



NODDI Highlights Promising New Markers In Presymptomatic C9orf72 Carriers

Junhao Wen, Hui Zhang, Daniel Alexander, Stanley Durrleman, Alexandre Routier, Daisy Rinaldi, Marion Houot, Jiaying Zhang, Olivier Colliot, Isabelle Le Ber, et al.

► To cite this version:

Junhao Wen, Hui Zhang, Daniel Alexander, Stanley Durrleman, Alexandre Routier, et al.. NODDI Highlights Promising New Markers In Presymptomatic C9orf72 Carriers. OHBM 2018 - Organization for Human Brain Mapping Annual Meeting, Jun 2018, Singapour, Singapore. hal-01758137

HAL Id: hal-01758137

<https://inria.hal.science/hal-01758137>

Submitted on 4 Apr 2018

HAL is a multi-disciplinary open access archive for the deposit and dissemination of scientific research documents, whether they are published or not. The documents may come from teaching and research institutions in France or abroad, or from public or private research centers.

L'archive ouverte pluridisciplinaire **HAL**, est destinée au dépôt et à la diffusion de documents scientifiques de niveau recherche, publiés ou non, émanant des établissements d'enseignement et de recherche français ou étrangers, des laboratoires publics ou privés.

NODDI Highlights Promising New Markers In Presymptomatic C9orf72 Carriers

Junhao Wen^{1,2}, Hui Zhang³, Daniel Alexander³, Stanley Durrleman^{1,2}, Alexandre Routier^{1,4}, Daisy Rinaldi^{4,5}, Marion Houot⁶, Jiaying Zhang³, Olivier Colliot^{1,7,8}, Isabelle Le Ber^{5,6,7}, Anne Bertrand^{1,7,9} and the PREVDEMALS study group

¹Inria Paris, Aramis project-team, Paris, France

²Sorbonne Université, Inserm, CNRS, Institut du cerveau et la moelle (ICM), Paris, France

³Department of Computer Science & Centre for Medical Image Computing, University College London, UK

⁴Sorbonne Université, Inserm, CNRS, Institut du cerveau et la moelle (ICM), FrontLab, Paris, France

⁵AP-HP, Hôpital Pitié-Salpêtrière, Centre de Référence des Démences Rares ou Précoces, Paris, France

⁶AP-HP, Hôpital Pitié-Salpêtrière, Institute of Memory and Alzheimer's Disease (IM2A), Centre of excellence of neurodegenerative disease (CoEN), Department of Neurology, Paris, France

⁷Sorbonne Université, Inserm, CNRS, Institut du cerveau et la moelle (ICM), AP-HP, Paris, France

⁸AP-HP, Departments of Neuroradiology and Neurology, Pitié-Salpêtrière Hospital, Paris, France

⁹AP-HP, Saint-Antoine Hospital, Department of Radiology, Paris, France

Introduction

C9orf72 repeat expansions are the most common genetic cause of frontotemporal lobar degeneration (FTLD) and amyotrophic lateral sclerosis (ALS). (Majounie et al., 2012). Diffusion tensor imaging (DTI) is a magnetic resonance imaging (MRI) technique that can detect microstructural changes in vivo by measuring water diffusion (Alexander et al. 2007). However, DTI has several limitations (Pierpaoli et al., 1996), that could be overcome using more advanced model, such as neurite orientation dispersion and density imaging (NODDI) (Zhang et al., 2012). Neurite density index (NDI) and orientation dispersion index (ODI) from NODDI aim to quantify the density and dispersion of neurites. Besides, free water fraction (FISO) also captures the volume of free water in tissues at the microstructural level. In the present work, we studied a cohort of subjects at risk for carrying *c9orf72* mutation. NODDI metrics were compared to T1 and standard DTI metrics to detect group differences between presymptomatic subjects (c9+) and control subjects (c9-) during presymptomatic stage.

Methods

Multi-shell diffusion-weighted images (DWI) were acquired on 38 c9+ and 29 c9- (the study group differs from Bertrand et al., 2017, by 11 subjects). 13 non diffusion-weighted volumes (b0) and three shells DWI with b-values of 300, 600 and 2200 s/mm² were acquired. Each subject also underwent a single-shell DWI sequence (used to fit DTI model) with b-values of 1000 s/mm², and a 3D T1-weighted sequence. Multi-shell DWI data were corrected for susceptibility-induced distortions, eddy current-induced distortions and head motion. NODDI was then fitted generating NDI, ODI and FISO maps. NDI and ODI maps were nonlinearly registered onto John Hopkins University atlas template to calculate the mean values of NDI and ODI within white matter (WM) regions of interest (ROI). T1-weighted images were segmented using FreeSurfer and FISO maps were rigidly transformed onto FreeSurfer conformed space, in order to extract volumetry and FISO values within cortical and subcortical ROI. Additionally, the single-shell DWI was processed with the same approach as in Bertrand et al to obtain the mean values of FA, MD, RD and AD maps within WM ROI. Statistical analyses were performed using a general linear model, including age, sex and group as fixed effects and family kinship as random effect. Statistical significance was set at $P < 0.05$ and correction for multiple comparisons was performed using Benjamini-Hochberg method. Additionally, effect size for the factor “group” was also reported for each metric using Cohen’s f^2 .

The image processing pipelines are publicly available in Clinica platform (<http://clinica.run>).

Results

For WM analysis displayed in Fig 1, 10 tracts showed significant WM abnormalities in c9+ subjects with NDI, while only 5 tracts with DTI metrics. 7 of the 11 significant tracts detected by either NDI or DTI had higher effect size with NDI than with DTI metrics.

For cortex analysis shown in Fig 2, FISO detected significant free water alteration within 13 ROIs in c9+, while significant atrophy was detected within 11 ROIs in c9+. The difference of effect size was moderate between FISO and volumetry.

For subcortical analysis, volumetry identified significant atrophy in right thalamus, while FISO failed to reveal any free water alteration.

Conclusions

We demonstrate that NDI offers higher sensitivity than DTI metrics to detect white matter alteration in presymptomatic carriers of *c9orf72* mutation. FISO was comparably sensitive, as compared to volumetry, for the detection of cortical changes. However, FISO failed to detect any free water alteration in subcortical structures. Overall, NODDI may provide more sensitive biomarkers than DTI for the detection of white matter integrity disruption during the presymptomatic stage of neurodegenerative diseases. This could have implications for the monitoring of disease trajectory and therapeutic interventions in presymptomatic subjects.

References

- Majounie, E., Renton, A.E., Mok, K., Dopper, E.G., Waite, A., Rollinson, S., Chiò, A., Restagno, G., Nicolaou, N., Simon-Sanchez, J. and Van Swieten, J.C., 2012. Frequency of the C9orf72 hexanucleotide repeat expansion in patients with amyotrophic lateral sclerosis and frontotemporal dementia: a cross-sectional study. *The Lancet Neurology*, 11(4), pp.323-330.
- Alexander, A.L., Lee, J.E., Lazar, M. and Field, A.S., 2007. Diffusion tensor imaging of the brain. *Neurotherapeutics*, 4(3), pp.316-329.
- Pierpaoli, C. and Basser, P.J., 1996. Toward a quantitative assessment of diffusion anisotropy. *Magnetic resonance in Medicine*, 36(6), pp.893-906.
- Zhang, H., Schneider, T., Wheeler-Kingshott, C.A. and Alexander, D.C., 2012. NODDI: practical in vivo neurite orientation dispersion and density imaging of the human brain. *Neuroimage*, 61(4), pp.1000-1016.
- Bertrand, A., Wen, J., Rinaldi, D., Houot, M., Sayah, S., Camuzat, A., Fournier, C., Fontanella, S., Routier, A., Couratier, P. and Pasquier, F., 2017. Early Cognitive, Structural, and Microstructural Changes in Presymptomatic C9orf72 Carriers Younger Than 40 Years. *JAMA neurology*.

Figures

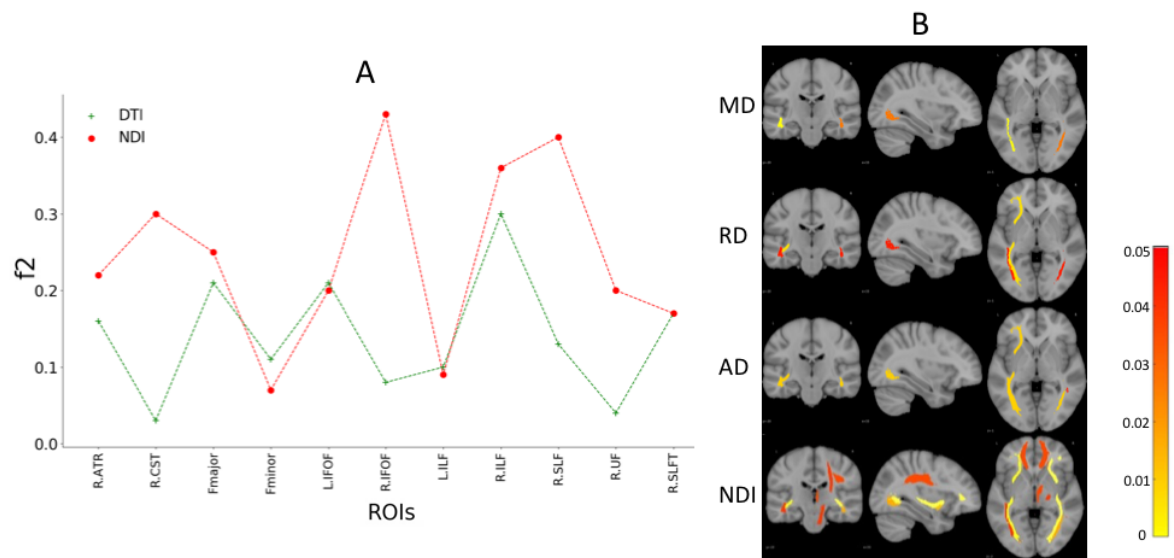


Fig 1. A) Effect size corresponding to the effect of *C9orf72* mutation on DTI and NDI. B) Corrected P value corresponding to the effect of *C9orf72* mutation on DTI and NODDI metrics. No significance was detected for FA and ODI.

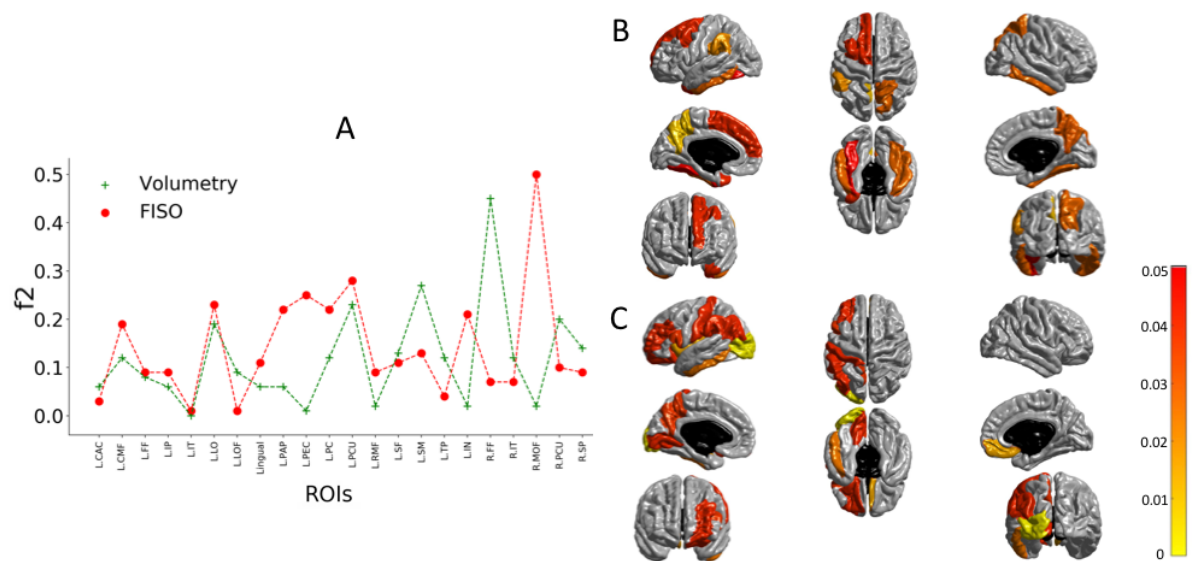


Fig 2. A) Effect size corresponding to the effect of *C9orf72* mutation on Volumetry and FISO. B) Corrected P value corresponding to the effect of *C9orf72* mutation on Volumetry within cortical ROI. C) Corrected P value corresponding to the effect of *C9orf72* mutation on FISO within cortical ROI.