



HAL
open science

Reduced basal forebrain atrophy progression in a randomized Donepezil trial in prodromal Alzheimer's disease

Enrica Cavedo, Michel J Grothe, Olivier Colliot, Simone Lista, Marie Chupin, Didier Dormont, Marion Houot, Stephane Lehéricy, Stefan Teipel, Bruno Dubois, et al.

► To cite this version:

Enrica Cavedo, Michel J Grothe, Olivier Colliot, Simone Lista, Marie Chupin, et al.. Reduced basal forebrain atrophy progression in a randomized Donepezil trial in prodromal Alzheimer's disease. Scientific Reports, 2017, 7 (1), pp.11706. 10.1038/s41598-017-09780-3 . hal-01589622

HAL Id: hal-01589622

<https://inria.hal.science/hal-01589622>

Submitted on 18 Sep 2017

HAL is a multi-disciplinary open access archive for the deposit and dissemination of scientific research documents, whether they are published or not. The documents may come from teaching and research institutions in France or abroad, or from public or private research centers.

L'archive ouverte pluridisciplinaire **HAL**, est destinée au dépôt et à la diffusion de documents scientifiques de niveau recherche, publiés ou non, émanant des établissements d'enseignement et de recherche français ou étrangers, des laboratoires publics ou privés.

SCIENTIFIC REPORTS



OPEN

Reduced basal forebrain atrophy progression in a randomized Donepezil trial in prodromal Alzheimer's disease

Enrica Cavedo^{1,2}, Michel J. Grothe^{3,4}, Olivier Colliot^{5,6}, Simone Lista¹, Marie Chupin^{5,7}, Didier Dormont^{5,8}, Marion Houot⁹, Stephane Lehericy^{10,11,12}, Stefan Teipel^{3,4}, Bruno Dubois¹³, Harald Hampel¹ & Hippocampus Study Group

Acetylcholinesterase inhibitors are approved drugs currently used for the treatment of Alzheimer's disease (AD) dementia. Basal forebrain cholinergic system (BFCS) atrophy is reported to precede both entorhinal cortex atrophy and memory impairment in AD, challenging the traditional model of the temporal sequence of topographical pathology associated with AD. We studied the effect of one-year Donepezil treatment on the rate of BFCS atrophy in prodromal AD patients using a double-blind, randomized, placebo-controlled trial of Donepezil (10 mg/day). Reduced annual BFCS rates of atrophy were found in the Donepezil group compared to the Placebo treated arm. Secondary analyses on BFCS subregions demonstrated the largest treatment effects in the Nucleus Basalis of Meynert (NbM) and the medial septum/diagonal band (Ch1/2). Donepezil administered at a prodromal stage of AD seems to substantially reduce the rate of atrophy of the BFCS nuclei with highest concentration of cholinergic neurons projecting to the cortex (NbM), hippocampus and entorhinal cortex (Ch1/2).

Degeneration of cholinergic neurons in the basal forebrain cholinergic system (BFCS) and the subsequent loss of cholinergic neurotransmission in the cerebral cortex and limbic system are crucial pathophysiological events that trigger the cognitive deterioration observed in patients with Alzheimer's disease (AD) dementia^{1,2}.

So far, Acetylcholinesterase inhibitors (AChEI) are among the few drugs approved for the treatment of AD^{3,4}. Traditionally, AChEI have been categorized as "symptomatic drugs" since they delay the development of clinical symptoms of AD without previous convincing evidence of affecting hypothesized key disease pathophysiology, characterized by the extracellular deposition of accumulated amyloid beta (A β) peptides into amyloid plaques and the intracellular accumulation of neurofibrillary tangles in the brain. However, there is a renewed debate on the involvement of cholinergic therapies in various pathophysiological mechanisms and cascades associated

¹AXA Research Fund & UPMC Chair, Paris, France; Sorbonne Universities, Pierre et Marie Curie University, Paris 06, Institute of Memory and Alzheimer's Disease (IM2A) & Brain and Spine Institute (ICM) UMR S 1127, Department of Neurology, Hopital Pitié-Salpêtrière, Paris, France. ²Laboratory of Alzheimer's Neuroimaging and Epidemiology, IRCCS Centro San Giovanni di Dio Fatebenefratelli, Brescia, Italy. ³German Center for Neurodegenerative Diseases (DZNE) – Rostock/Greifswald, Rostock, Germany. ⁴Department of Psychosomatic Medicine, University of Rostock, Rostock, Germany. ⁵Sorbonne Universités, UPMC Univ Paris 06, Inserm, CNRS, Institut du cerveau et la moelle (ICM), APHP- Hôpital Pitié-Salpêtrière, Paris, France. ⁶Inria, Aramis project-team, Centre de Recherche de, Paris, France. ⁷CATI – Centre d'Acquisition et de Traitement des Images, Paris, France. ⁸AP-HP, Neuroradiology Department, Hôpital de la Pitié-Salpêtrière, Paris, France. ⁹Institute of Memory and Alzheimer's Disease (IM2A), Centre of Excellence of Neurodegenerative Disease (CoEN), ICM, APHP Department of Neurology, Hopital Pitié-Salpêtrière, University Paris 6, Paris, France. ¹⁰CENIR, Hôpital de la Salpêtrière, Paris, France. ¹¹INSERM U1127, Institut du Cerveau et de la Moelle Epiniere (ICM), Paris, France. ¹²Sorbonne Universités, Université Pierre et Marie Curie-Paris 6, Paris, France. ¹³Sorbonne Universités, Pierre et Marie Curie University, Paris 06, Institute of Memory and Alzheimer's Disease (IM2A) & Brain and Spine Institute (ICM) UMR S 1127, Department of Neurology, Hopital Pitié-Salpêtrière, Paris, France. A comprehensive list of consortium members appears at the end of the paper. Correspondence and requests for materials should be addressed to E.C. (email: enrica.cavedo@gmail.com) or H.H. (email: harald.hampel@med.uni-muenchen.de)

Received: 5 April 2017

Accepted: 31 July 2017

Published online: 15 September 2017

	Placebo (n = 88)	Donepezil (n = 75)	p-value	F value (df)
Age, years	73 (6.7)	73 (6.8)	0.930	0.008 (1,161)
Gender				
F/M	46/42	37/38	0.708	
Education, n (%)				
No education	1 (0.01)	0 (0.0)	0.140	
Primary	6 (6.8)	8 (10.6)		
Certificate of Primary	43 (48.8)	26 (34.6)		
Education	13 (14.7)	21 (28)		
Secondary	25 (28.4)	20 (26.6)		
Higher education				
Follow-up MRI (days)	376 (48)	373 (43)	0.730	0.120 (1,161)
FCSRT (Free recall)	11.3 (5.7)	12.1 (5.2)	0.357	0.853 (1,161)
FCSRT (Total recall)	29.4 (10)	31 (8.7)	0.267	1.267 (1,161)
Hamilton Rating Scale for Depression	3.6 (2.8)	3.3 (2.7)	0.492	0.475 (1,161)
ADAS-COG-MCI	12.4 (4.3)	12.3 (4.5)	0.975	0.001 (1,161)
MMSE	25.9 (2.8)	26 (2.2)	0.831	0.046 (1,161)
APOE genotype,				
Positive APOE $\epsilon 4$ n (%)	18 (47%)	16 (59%)	0.344	
Missing n (%)	65 (63%)	86 (24%)		
3 Tesla MRI (%)	23%	29%	0.336	

Table 1. Baseline Demographic and Clinical Characteristics of patients performing baseline and follow-up MRI. Means and standard deviations are reported for continuous variables, numbers and percentages for the dichotomous ones. P-values denote significant differences at ANOVA and Chi-square tests. FCSRT = Free and Cued Selective Reminding Test, MRI = Magnetic Resonance Imaging, df = degrees of freedom.

with AD. There is evidence showing that AChEI prevent experimentally induced A β brain deposition, suggesting that AChEI may delay the progression of the disease^{5,6}. Indeed, reduced rate of atrophy in grey and white matter volumes and metabolic changes were found in AD dementia patients after AChEI treatment^{7–10} indicating the potential disease-modifying effect of AChEI. However, conflicting results were reported in clinical trials on mildly cognitively impaired (MCI) subjects^{11–16}, probably due to the substantial degree of clinical heterogeneity that characterizes this target population.

The nucleus basalis of Meynert (NbM) is one of the most vulnerable structures to neurofibrillary degeneration¹⁷ and represents the principal source of cholinergic innervation of the cerebral cortex and the amygdala¹⁸. In contrast to its widespread projections to major cortical areas, the NbM receives its main cortical inputs from the piriform, orbitofrontal, medial temporal, entorhinal and anterior cingulate cortices as well as from the anterior insula and temporal pole^{18,19}.

Measurements of BFCS atrophy on high-resolution structural magnetic resonance imaging (MRI) are being used as *in vivo* surrogate markers for cholinergic degeneration. Recent studies could demonstrate *in vivo* BFCS atrophy in AD dementia patients and in prodromal AD individuals^{20–22}, including increased rates of BFCS atrophy in AD and MCI compared to controls during 2 years of follow-up²³. These changes were found to be most pronounced in the posterior part of the NbM²⁴, reflecting the neuropathological literature²⁵. Recently published results indicated that the atrophy of NbM may precede and predict atrophy of the entorhinal cortex in relation to different stages of AD pathophysiology²⁶. These evidences were in line with previous findings highlighting the existence of a correlation between BFCS atrophy and cortical amyloid burden in asymptomatic at-risk and pre-dementia stages of AD^{27–29}.

Based on the data previously reported by the Hippocampus Study Clinical Trial (NCT00403520)^{13,16} and the recent literature results suggesting an early involvement of BFCS in AD pathophysiology^{26,28,30}, the objective of this explorative study is to further investigate the effect of one-year Donepezil treatment on the rate of BFCS atrophy in prodromal AD patients.

Results

Study design and clinical results. This study included 332 patients with prodromal AD that participated in the multi-centre double-blind, randomized, placebo-controlled trial with a Donepezil treatment period (10 mg/day) of 12 months (Clinical Trial.gov Number: NCT00403520, Submission Date: November 21, 2006)¹³. From the per-protocol population, we selected the participants with imaging scans with enough quality for the data analysis (Placebo N = 88, Donepezil N = 75). No difference between Donepezil and Placebo groups was present in terms of sociodemographic features (age, gender and education), clinical features (depressive symptoms), global cognition and memory performances (Table 1). Finally, no differences were found in the time period of MRI scans and in the frequencies of scans executed with 3 Tesla MRI machine between groups (Table 1).

	Placebo (n = 88)	Donepezil (n = 75)	p-value	F value (df)
GM (cm ³)	535 ± 60	543 ± 60	0.352	0.870 (1,161)
BFCS (mm ³)	617 ± 125	648 ± 139	0.132	2.296 (1,161)
NbM (mm ³)	471 ± 100	494 ± 109	0.171	1.889(1,161)
Ch4p (mm ³)	179 ± 45	184 ± 46	0.482	0.496 (1,161)
Ch1/2 (mm ³)	109 ± 25	117 ± 28	0.068	3.382 (1,161)

Table 2. Grey Matter and Basal forebrain cholinergic system volumes at baseline. Means and standard deviations are reported, p-values denote significant differences at One-Way ANOVA including age, gender, MRI field strength (1.5 T or 3 T) and MRI scanner manufacturer (Philips, GE Healthcare or Siemens) as covariates. All the Volumes are normalized to the total intracranial volume (TIV). Abbreviations: BFCS = Basal Forebrain Cholinergic System; NbM = Nucleus Basalis of Meynert; Ch4p = posterior Nucleus basalis Meynert (NBM); Ch1/2 = combined clusters of the medial septum and the vertical limb of the diagonal band of Broca, df = degrees of freedom.

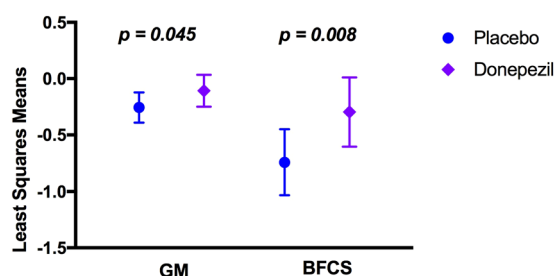


Figure 1. Grey Matter (GM) and Basal Forebrain Cholinergic System (BFCS) Annualized Percentage Change (APC) describing significant atrophy reduction in prodromal AD patients treated one year with Donepezil. Least squares means and 95% Confidence Interval are reported, p-values denote significant differences between treatment groups at the General Linear Model including age, gender, MRI field strength (1.5 T or 3 T) and MRI scanner manufacturer (Philips, GE Healthcare or Siemens) as covariates.

Grey Matter and BFCS baseline volume features. In order to check baseline brain volume differences between groups, we first examined the baseline BFCS and total grey matter (GM) volume differences, normalized to the total intracranial volume, between Placebo and Donepezil using ANOVA. No differences were found (Table 2). Distributions of GM and BFCS nuclei volumes in each treatment group stratified by MRI field strength at baseline and follow-up scans are represented in the Supplementary Fig. 1.

Donepezil reduced GM and BFCS atrophy. The main aim of the study was to investigate the effect of Donepezil treatment on brain volume changes involved in the cholinergic circuit over the study period by measuring the BFCS and GM Annualized Percentage Change (APC). Results from the general linear model, including age, gender, MRI field strength as well as MRI scanner manufacturer as covariates, revealed reduced APC of the total GM in the Donepezil group compared to the Placebo ($p = 0.045$, Fig. 1). A treatment difference of -0.15 percentage points for total GM volume was found. Moreover, the Donepezil group exhibited a lower rate of atrophy of the whole BFCS over a 1-year period compared to the Placebo group (APC -0.30% vs -0.74% , respectively, $p = 0.008$, Fig. 1) with a treatment difference of -0.44 . Supplemented analysis using the linear mixed effect model (Fig. 2) revealed that GM ($p = 0.030$; estimate: $\text{time} \times \text{donepezil} = -0.001$, $\text{time} \times \text{placebo} = -0.004$) and BFCS ($p = 0.004$; estimate: $\text{time} \times \text{donepezil} = -0.005$ and $\text{time} \times \text{placebo} = -0.013$) volumes were significantly decreased in the Placebo group compared with the Donepezil group throughout the 12 months of treatment period.

Secondary analysis on BFCS subregions. In addition, a secondary analysis was conducted on BFCS subregions. In particular, in those subregions representing the best separable divisions within the BFCS such as the Ch1/2 sector and the NbM, as well as the Ch4p division of the NbM, since previous studies reported that the Ch4p is the most BFCS region affected in AD.

Results from the general linear model showed reduced APC in the Donepezil group compared to the Placebo group in the rostromedial nuclei (Ch1/2, $p < 0.001$, treatment difference = -0.76) as well as in the NbM ($p = 0.005$ treatment difference = -0.48 ; defined as the sum of the volume of its subdivisions: Ch4a-i, Ch4al/NSP and Ch4p) (Fig. 2). Finally, a trend of significance between groups was found in the APC of the posterior NbM subregion (Ch4p, $p = 0.060$, treatment difference = -0.042 , Fig. 3). Supplemented analysis using the linear mixed effect model (Fig. 2) revealed that during the 12 months of treatment period, NbM ($p = 0.002$; estimate: $\text{time} \times \text{donepezil} = -0.004$, $\text{time} \times \text{placebo} = -0.012$), Ch1/2 ($p < 0.001$; estimate: $\text{time} \times \text{donepezil} = 0.002$, $\text{time} \times \text{placebo} = -0.001$) and Ch4p volumes were significantly decreased in the Placebo group compared with the Donepezil group ($p = 0.024$; estimate: $\text{time} \times \text{donepezil} = -0.005$, $\text{time} \times \text{placebo} = -0.007$).

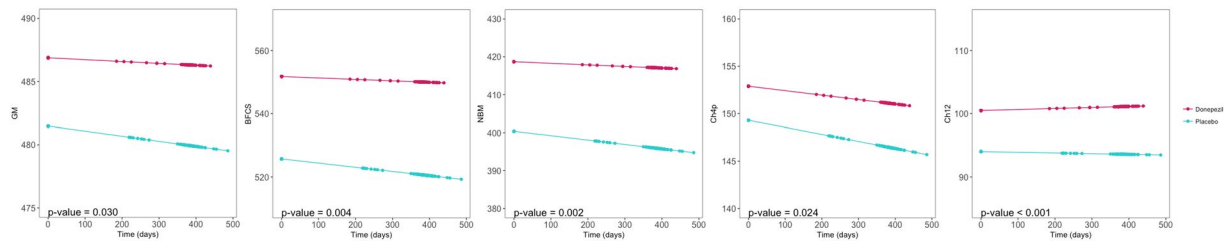


Figure 2. Mean trajectories of Grey Matter and Basal Forebrain Cholinergic System indicating significant volume changes over time, from baseline scan to follow-up scan, as resulted from the linear mixed-effects model.

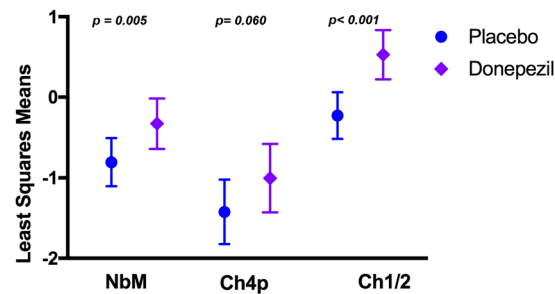


Figure 3. Annualized Percentage Change (APC) of Basal forebrain cholinergic system subregions indicating a specific reduction of trophy after one year of treatment with Donepezil in the Nucleus Basalis of Meynert and in the medial septum and the vertical limb of the diagonal band of Broca. Least squares means and 95% Confidence Interval are reported, p-values denote significant differences between treatment groups at General Linear Model including age, gender, MRI field strength (1.5 T or 3 T) and MRI scanner manufacturer (Philips, GE Healthcare or Siemens) as covariates. NbM = Nucleus Basalis of Meynert; Ch4p = posterior Nucleus Basalis Meynert (NBM); Ch1/2 = combined clusters of the medial septum and the vertical limb of the diagonal band of Broca.

Discussion

Our outcomes build on the hypothesis that AChEI treatment has a relevant influence on the neurodegenerative progression of the BFCS in patients with an amnesic syndrome of the hippocampal type, a clinical high risk manifestation of prodromal AD³¹. Overall, our findings revealed a reduction of total GM and BFCS atrophy in prodromal AD patients treated with Donepezil compared to the Placebo group after one year of treatment. In particular, we found a specific effect of cholinesterase therapy on the BFCS with a treatment difference of -0.44 points compared to a difference of -0.15 detected for total GM. In addition, the treatment effect was observed in those BFCS subregions showing widespread projections to the cortex (NbM), the hippocampus and the entorhinal cortex (Ch1/2). In this regards, our results revealed a relative specificity of treatment for the rostromedial nuclei (Ch1/2) compared to Ch4p/NbM.

It should be noted that the cholinergic basal forebrain, as part of the basomedial limbic belt, is one of the most susceptible brain areas for early damage in AD. Cholinergic neurons in the NbM are among the first neurons in which neurofibrillary tangles and A β plaques are detected in AD patients³². Moreover, a significant *in vivo* atrophy of BFCS in AD patients^{20,33} as well as in prodromal and preclinical phases of AD^{21–23}, particularly in the posterior part of NbM (Ch4p)²⁴, has been extensively reported in the recent literature. Notably, *in vivo* BFCS atrophy correlated with cognitive decline in individuals with MCI and AD^{22,34}, and it is assumed to contribute to the mechanisms of brain resilience in cognitively intact elderly individuals³⁵. These results support previous evidence describing an involvement of the BFCS in cognitive processes altered in AD, such as memory and attention^{36–38}. *In vivo* BFCS atrophy was also found to be associated with cortical brain amyloidosis in AD patients at the pre-symptomatic and pre-dementia stages^{27,28,39}, thus reflecting a link between cholinergic degeneration and cortical amyloid pathology, as previously reported in neuropathological examination studies^{40–42}. A recent analysis emphasized the role of NbM as a crucial pathological target of AD²⁶ by describing its early and isolated abnormal degeneration in asymptomatic at-risk individuals for AD. The authors showed how atrophy of the NbM precedes and predicts both memory decline and entorhinal cortex atrophy in relation to AD pathophysiology.

In view of the development of novel therapeutic strategies, the findings presented by Schmitz and colleagues lead to carefully re-examine the prominence of the entorhinal cortex as the structural starting point of the disease and suggest that the BFCS might represent a key therapeutic target for clinical trials aimed at modifying the progression of AD during the early preclinical and potentially reversible or modifiable disease stages. However, to our knowledge, to date no trial has used quantitative BFCS volumetry as primary or secondary endpoint. Few studies examined the association of BFCS volume with treatment response to AChEI in prodromal AD and dementia patients^{43,44}. A first study, conducted in AD dementia patients, showed that the atrophy of the substantia innominata, an anatomic proxy of the BFCS, measured on MRI, predicts response to Donepezil treatment over nine months⁴³. However, these effects were not assessed in relation to a Placebo control group. Instead, a study from

our group, performed on the hippocampus study population, assessed the significance of hippocampus and BFCS volumes at baseline in predicting cognitive decline and treatment response after one year of Donepezil treatment in comparison to Placebo⁴⁴. Results indicated that both hippocampus and BFCS volumes were poor predictors of treatment response; however, the study sample power was not calculated to detect treatment effects on cognition or functional outcomes⁴⁴. These results highlighted the need to use longitudinal measurements of hippocampus and BFCS to test the treatment effects of Donepezil.

Our results are in line with the ones described in previous clinical trials revealing a biological effect of AChEI treatment in AD dementia patients. In particular, a significant reduction of grey matter and white matter atrophy, as well as metabolic changes were described in AD dementia patients treated with Donepezil compared to Placebo^{7–10}. Furthermore, our previous study on prodromal AD patients confirmed the results described in AD dementia patients, showing reduced annual hippocampal rate of atrophy in patients treated with Donepezil compared to the Placebo group¹³. The treated group showed a percentage of annual atrophy reduction equal to 45%. In the current study we found 59% reduction of rate of BFCS atrophy in the treated group. These results suggest a relative higher protective effect of Donepezil on the BFCS compared with the one found in the hippocampus. Additionally, we found an effect of Donepezil in reducing the rate of atrophy in cortical areas involved in the cholinergic circuits¹⁶. In the same cohort, we found a reduction of whole brain atrophy and ventricular enlargement in prodromal AD participants receiving Donepezil¹³, consistent with earlier findings in MCI individuals⁴⁵. Studies on functional brain imaging reported promising results on the impact of AChEI-based therapy on AD patients showing an increased resting state metabolism in the left prefrontal cortex and a decreased metabolism in the right hippocampus⁴⁶. Furthermore, stabilization of resting- and memory-specific brain activity and connectivity^{47, 48} as well as significant brain activation of the dorsal visual pathway during a location matching task were found in individuals with MCI treated with AChEI⁴⁹.

Our current findings based on quantitative analysis of longitudinal neuroimaging data support the hypothesis that one-year Donepezil treatment at the prodromal AD stage may have a significant positive impact on brain structures involved in the cholinergic circuits, such as the NbM. Furthermore, in the Donepezil group, our results highlighted the presence of reduced atrophy rate in the Ch1/2 subregions, representing the primary source of cholinergic projections to the hippocampus and entorhinal cortex^{26, 50}. Two previous trials showed reduced hippocampal atrophy after Donepezil treatment in comparable target populations^{11, 13}. Consequently, Donepezil may induce a specific beneficial pathophysiological effect on brain structures involved in the hippocampal cholinergic circuit. This reflection is in line with previously published evidence suggesting that AChEI therapy probably delays the progression of the disease by reducing the accumulation of A β plaques in the brain⁵. In addition to cholinergic system enhancement, there is evidence that Donepezil may promote Nerve Growth Factor (NGF) activity and potentiate NGF-induced neurite outgrowth via extracellular signal-regulated kinase (ERK) activation in PC12 cells⁵¹. These results suggest that Donepezil may promote neuronal differentiation and this effect could slow the degeneration processes fostering the recovery of higher neuronal functions. Furthermore, several studies suggest a relationship between cholinergic neurotransmission and β -amyloid peptide (A β) that may act as a physiologically active neuromodulator⁵². The scenario of chronic inflammation in the brain, generated by the imbalance between A β production and clearance, induces the production of a series of proinflammatory cytokines, chemokines, macrophage inflammatory proteins, leukotrienes, reactive oxygen species, and nitric oxide^{53–55}. The neuroinflammatory cytokines may not only contribute to neuronal death, but they might also affect the recognized neurodegenerative pathways such as amyloid precursor protein (APP) processing and tau hyperphosphorylation⁵⁶. Studies using Donepezil have also shown that Donepezil does not act exclusively at the level of acetylcholine, but has potent anti-inflammatory properties in AD patients, in a tauopathy mouse model and in lipopolysaccharide (LPS)-treated animals⁵⁷. These findings suggest a potential inhibitory role of Donepezil in neuronal death and cognitive decline by repressing oligomeric A β -triggered inflammatory pathways in microglia⁵⁷.

Further analyses on phenotypically and clinically well-defined populations, supported by *in vivo* evidence of AD pathophysiology, are needed in order to substantiate our findings.

A former investigation examining longitudinal BFCS atrophy in very mild AD patients based on the same methodology showed a BFCS APC of 2.9%²³. The higher APC value than the one found in our Placebo group may be due to differences in the clinical population specifically selected. Indeed, participants selected for the present trial mostly represent prodromal AD patients at a particularly early stage, as defined by the amnesic syndrome of the hippocampal type.

Our study has a number of limitations that might reduce its generalizability. First of all, the initial study design was not intended for use in a *post-hoc* analysis. The study protocol did not collect any information with reference to core feasible pathophysiological biomarkers of AD, race and ethnicity characteristics, or lifestyle. Lifestyle habits, such as nutrition, hydration, physical activity, and bilingualism, showed a significant effect on brain morphology in elderly individuals^{58–60}. Moreover, no sufficient data on *APOE* ϵ 4 genotype were collected to exclude the hypothesis that our results were not significantly affected by the *APOE* ϵ 4 genetic variant that seems to have an impact on the biological effect of Donepezil in the amyloid precursor protein metabolism in AD dementia patients⁶¹. Finally, the examined follow-up period was not long enough to determine the incidence of incipient AD dementia in each group.

In conclusion, to our knowledge this is the first randomized clinical therapy trial using the BFCS as outcome. Overall, our findings substantiate the hypothesis that Donepezil treatment during the prodromal AD stage may preserve decline of brain morphology of structures belonging to the cholinergic circuit, thus re-opening the question whether Donepezil has substantial biological properties and should be still categorized as a mere “symptomatic” drug. Moreover, our findings support the assumption that BFCS atrophy may represent a robust, reliable and feasible candidate surrogate outcome in pre-dementia AD clinical trials. Our results furthermore, are in line with recent findings from Schmitz and colleagues describing a central and early involvement of basal forebrain

atrophy during the pathophysiological process of AD²⁶. In the light of these findings, the effect of cholinergic therapy should then be applied and assessed in a preclinical population of amyloid positive individuals, in order to test the power of cholinergic drugs in preventing AD.

Cholinergic structural changes begin during subclinical stages of AD and are accompanied by several other components of AD pathophysiology leading to AD dementia. For these reasons, further studies combining the *in vivo* measurement of different pathophysiological mechanisms of AD, such as neurofibrillary tangles and amyloid plaque deposition measured by positron emission tomography, as well as white matter cholinergic networks measured by advanced tractographic methods, are needed to support data on the relative specificity of Donepezil effect on the cholinergic system in the brain.

Methods

Study Design. Multi-centre double-blind, randomized, placebo-controlled trial with a treatment period of 12 months. The study started in November 2006 and was concluded in August 2010 (NCT00403520), for details on the selection of population, randomisation and sample size calculation please see our previous publication by Dubois and colleagues¹³. Patients were randomly assigned to either active or Placebo treatment group (1 capsule of 5-mg Donepezil daily for Weeks 0 to 6, then 2 capsules of 5-mg Donepezil [i.e., 10 mg] daily from Week 6 to Month 12 for double-blind treatment; or 1 placebo capsule daily for Weeks 0 to 6, then 2 capsules daily from Week 6 to Month 12 for double-blind treatment, respectively). The study protocol was approved by the institutional review board from each site and by the Ethic Committee of the Coordination Centre at La Pitié-Salpêtrière Hospital, Paris, France (Reference Number: E2020-E033-41, Ethic Committee Approval: November 8, 2006). The study was performed strictly in accordance with the approved guidelines and regulations. An informed consent was obtained from all subjects. The original primary efficacy outcome of the trial was the annualized percentage change (APC) of total hippocampal volume measured by an automated segmentation method⁶². Since the BFCS is one of the main brain regions rich of cholinergic neurons and early involved in the AD pathophysiology, in this *post-hoc* analysis, we explored the effect of Donepezil on BFCS APC.

Patients. Details on patient characteristics have been previously described¹³. Briefly, a total of 332 patients were screened within the national network of Memory Resources and Research Centres (CMRR) consisting of 28 French regional university expert centres with neurologists, geriatricians, neuropsychologists, biological and neuroimaging resources in each centre. Inclusion criteria were: 1) more than 50 years of age; 2) a progressive hippocampal amnesic syndrome, denoting prodromal AD, was defined by Free Recall score ≤ 17 or Total Recall score < 40 on the Free and Cued Selective Reminding Test (FCSRT); and 3) no dementia with a CDR stage of 0.5 and preserved global cognition and functional performance. Subjects who met the eligibility criteria were enrolled in the randomization phase beginning with Visit 1. In the present study we considered exclusively the per-protocol population (173 subjects) who performed MRI at baseline and at the end of the treatment.

Neuropsychological assessment. At baseline and follow-up visits, patients underwent a baseline MRI scan and a cognitive evaluation including: the Alzheimer's Disease Assessment Scale-cognitive subscale, MCI version (ADAS-COG-MCI)²⁰, Mini-Mental State Examination (MMSE), Modified Isaacs test, California Verbal Learning Test (CVLT)²¹, Trail Making Tests (TMT) A and B²², and the Benton Test²³.

MRI Acquisition. Brain MRI scans were acquired in each centre at baseline and at the end of treatment period. All the MRI were performed using 1.5 Tesla or 3 Tesla MRI scanners qualified by the central MRI analysis core at the Cogimage team, Centre de Recherche de l'institut du Cerveau et de la Moelle Épineière (CRICM). A standardized protocol of acquisition for the 3D T1-weighted images was applied in each site. The 3D T1-weighted scan parameters for scans at 1.5 T were: TR = 10 ms, TE = minimum, flip angle: 10, PREP time: 600, bandwidth: 12.50 khz, axial orientation; 1.3mm slice thickness, contiguous (124 slices), Imaging matrix size: 256 × 256, Field of view: 240 × 240; and for scans at 3 T: TR = 3.9 ms, TE = 2100 ms, flip angle: 15, PREP time: 1100 ms, sagittal orientation with 1 mm slice thickness, contiguous (144 slices), Acquisition matrix size: 256 × 192, Field of view: 256 × 192. The expert neuroradiologist in charge of quality control verified artifacts of movements, ringing, wrap around and metal artifacts. Moreover they attested that the sequences were acquired according to protocol parameters. Due to gross MRI artefacts or MRI quality issues, which might interfere with data analysis measurement of BFCS volume, 10 MRI images were excluded. The final sample considered for the study was composed of 163 subjects (Placebo N = 88 and Donepezil N = 75).

MRI processing. Main processing steps and computational analyses employed in the present study followed the longitudinal processing stream implemented in SPM12⁶³, adapted to the analysis of serial MRI scans used for BFCS volume²³. MRI data were processed by the statistical parametric mapping (SPM8 and SPM12, Wellcome Trust Center for Neuroimaging) and the VBM8-toolbox (<http://dbm.neuro.uni-jena.de/vbm/>) implemented in MatLab R2013a (MathWorks, Natick, MA). First, we applied the symmetric diffeomorphic registration for longitudinal MRI developed in SPM12⁶³. In particular, this algorithm rests on an intra-subject modelling framework that combines nonlinear diffeomorphic and rigid-body registration and further corrects for intensity inhomogeneity artefacts. The optimization is realized in a single generative model and provides internally consistent estimates of within-subject brain deformations that may have occurred during the study period. The registration model creates an average T1-image for each subject and the corresponding deformation fields for every individual scan. Then, images were segmented into grey matter (GM), white matter (WM) and cerebrospinal fluid (CSF) partitions using the tissue prior free segmentation routine of the VBM8-toolbox. All GM maps were visually inspected for segmentation. Afterward, nonlinear inter-subject image registration was performed on the individual average GM and WM tissue maps using DARTEL in SPM12. This involves iteratively matching all the selected images to a template generated from their own mean. Then, all native space average GM maps were scaled by

the respective Jacobian determinants (baseline and follow-up) obtained from the longitudinal registration, and the resulting images were finally warped to the group-specific spatial normalization template. Finally, individual GM volumes of the BFCS at baseline and follow-up were extracted automatically by summing up the modulated GM voxel values within a stereotactic mask of the BFCS. Generation of the BFCS mask was based on combined post-mortem MRI and histology of an autopsy brain and has been described in detail elsewhere²⁴. Briefly, the BFCS and its subregions were identified from digital images of histological sections of a post-mortem brain and transferred into corresponding slices of an *in-situ* acquired MRI scan, which was used for high-dimensional spatial normalization into MNI standard space. Histologic delineation of the BFCS and its subregions followed Mesulam's nomenclature^{64,65}, according to which the BFCS is separated into 4 principal groups of cholinergic cells: Ch1 and Ch2 denote the cholinergic cells associated with the medial septal nucleus, and the vertical limb of the diagonal band of Broca (Ch1/Ch2); Ch3 belongs to the horizontal limb of the diagonal band of Broca, and Ch4 describes the cholinergic cells of the NbM⁶⁵. The NbM is the largest cholinergic nucleus of the BFCS and can be considered as the sum of its subdivisions: anterior to intermediate (Ch4a-i), anterior lateral/nucleus subputaminalis (Ch4al/NPS) and posterior (Ch4p) subregions.

Statistical Analysis. Demographic, clinical and neuropsychological features were compared between groups (Placebo vs Donepezil). Chi-square (two-tailed) test was performed on categorical variables, while the one-way analysis of variance (ANOVA) two-tailed test was utilized for continuous variables. Baseline GM and BFCS measures normalized to total intracranial volume were compared between groups using One-way ANOVA two-tailed test.

Annualized Percentage Change (APC) of GM, BFCS and its subregions was computed as follows:

$$APC = \frac{\text{change from baseline}}{\text{value at baseline}} \times \frac{365}{\text{MRI delay}} \times 100$$

A General Linear Model including age, gender, MRI field strength (1.5 T or 3 T) and MRI scanner manufacturer (Philips, GE Healthcare or Siemens) was performed on the APC of the GM, BFCS and its subregions. In particular, in the whole NbM and its posterior nucleus (Ch4p) considered as the most susceptible to AD pathology^{21,23,25,66}, and in the medial septum and the vertical limb of the diagonal band of Broca (Ch1/2), which provide the main cholinergic innervation of the hippocampus. The BFCS, its subregions and the GM volumes were supplemented analysed by a linear mixed-effects model with patients as random effects and controlling for: age, gender, MRI field strength and MRI scanner manufacturer, to compare the differences in the volumes changes between Placebo and Donepezil patients over time. Statistical analyses were performed using SPSS v.22.00 and R 3.3.2.

References

- Bartus, R. T., Dean, R. L. 3rd, Beer, B. & Lipka, A. S. The cholinergic hypothesis of geriatric memory dysfunction. *Science* **217**, 408–414 (1982).
- Francis, P. T., Palmer, A. M., Snape, M. & Wilcock, G. K. The cholinergic hypothesis of Alzheimer's disease: a review of progress. *J Neurol Neurosurg Psychiatry* **66**, 137–147 (1999).
- Mangialasche, F., Solomon, A., Winblad, B., Mecocci, P. & Kivipelto, M. Alzheimer's disease: clinical trials and drug development. *Lancet Neurology* **9**, 702–716 doi:10.1016/S1474-4422(10)70119-8 (2010).
- Johannsen, P. *et al.* Assessing therapeutic efficacy in a progressive disease: a study of donepezil in Alzheimer's disease. *CNS Drugs* **20**, 311–325 (2006).
- Sabbagh, M. N., Farlow, M. R., Relkin, N. & Beach, T. G. Do cholinergic therapies have disease-modifying effects in Alzheimer's disease? *Alzheimers Dement* **2**, 118–125, doi:10.1016/j.jalz.2006.02.001 (2006).
- Giacobini, E. Do cholinesterase inhibitors have disease-modifying effects in Alzheimer's disease? *CNS Drugs* **15**, 85–91 (2001).
- Feldman, H. H. *et al.* Randomized controlled trial of atorvastatin in mild to moderate Alzheimer disease: LEADe. *Neurology* **74**, 956–964, doi:10.1212/WNL.0b013e3181d6476a (2010).
- Krishnan, K. R. *et al.* Randomized, placebo-controlled trial of the effects of donepezil on neuronal markers and hippocampal volumes in Alzheimer's disease. *Am J Psychiatry* **160**, 2003–2011 (2003).
- Hashimoto, M. *et al.* Does donepezil treatment slow the progression of hippocampal atrophy in patients with Alzheimer's disease? *Am J Psychiatry* **162**, 676–682, doi:10.1176/appi.ajp.162.4.676 (2005).
- Moon, C. M., Kim, B. C. & Jeong, G. W. Effects of donepezil on brain morphometric and metabolic changes in patients with Alzheimer's disease: A DARTEL-based VBM and (1)H-MRS. *Magn Reson Imaging* **34**, 1008–1016, doi:10.1016/j.mri.2016.04.025 (2016).
- Schuff, N. *et al.* An MRI substudy of a donepezil clinical trial in mild cognitive impairment. *Neurobiol Aging* **32**(2318), e2331–2341, doi:10.1016/j.neurobiolaging.2010.04.005 (2011).
- Jack, C. R. *et al.* Longitudinal MRI findings from the vitamin E and donepezil treatment study for MCI. *Neurobiol Aging* **29**, 1285–1295, doi:10.1016/j.neurobiolaging.2007.03.004 (2008).
- Dubois, B. *et al.* Donepezil decreases annual rate of hippocampal atrophy in suspected prodromal Alzheimer's disease. *Alzheimers Dement*, doi:10.1016/j.jalz.2014.10.003 (2015).
- Doody, R. S. *et al.* Donepezil treatment of patients with MCI: a 48-week randomized, placebo-controlled trial. *Neurology* **72**, 1555–1561, doi:10.1212/01.wnl.0000344650.95823.03 (2009).
- Birks, J. & Flicker, L. Donepezil for mild cognitive impairment. *Cochrane Database Syst Rev*, CD006104, doi:10.1002/14651858.CD006104 (2006).
- Cavedo, E. *et al.* Reduced Regional Cortical Thickness Rate of Change in Donepezil-Treated Subjects With Suspected Prodromal Alzheimer's Disease. *J Clin Psychiatry*, doi:10.4088/JCP.15m10413 (2016).
- Mesulam, M. M. The cholinergic innervation of the human cerebral cortex. *Prog Brain Res* **145**, 67–78, doi:10.1016/S0079-6123(03)45004-8 (2004).
- Mesulam, M. M. Cholinergic circuitry of the human nucleus basalis and its fate in Alzheimer's disease. *J Comp Neurol* **521**, 4124–4144, doi:10.1002/cne.23415 (2013).
- Mesulam, M. M., Mufson, E. J., Levey, A. I. & Wainer, B. H. Atlas of cholinergic neurons in the forebrain and upper brainstem of the macaque based on monoclonal choline acetyltransferase immunohistochemistry and acetylcholinesterase histochemistry. *Neuroscience* **12**, 669–686 (1984).

20. Teipel, S. J. *et al.* The cholinergic system in mild cognitive impairment and Alzheimer's disease: an *in vivo* MRI and DTI study. *Hum Brain Mapp* **32**, 1349–1362, doi:10.1002/hbm.21111 (2011).
21. Grothe, M., Heinsen, H. & Teipel, S. J. Atrophy of the cholinergic Basal forebrain over the adult age range and in early stages of Alzheimer's disease. *Biol Psychiatry* **71**, 805–813, doi:10.1016/j.biopsych.2011.06.019 (2012).
22. Grothe, M. *et al.* Reduction of basal forebrain cholinergic system parallels cognitive impairment in patients at high risk of developing Alzheimer's disease. *Cereb Cortex* **20**, 1685–1695, doi:10.1093/cercor/bhp232 (2010).
23. Grothe, M., Heinsen, H. & Teipel, S. Longitudinal measures of cholinergic forebrain atrophy in the transition from healthy aging to Alzheimer's disease. *Neurobiol Aging* **34**, 1210–1220, doi:10.1016/j.neurobiolaging.2012.10.018 (2013).
24. Kilimann, I. *et al.* Subregional Basal Forebrain Atrophy in Alzheimer's Disease: A Multicenter Study. *J Alzheimers Dis*, doi:10.3233/JAD-132345 (2014).
25. Vogels, O. J. *et al.* Cell loss and shrinkage in the nucleus basalis Meynert complex in Alzheimer's disease. *Neurobiol Aging* **11**, 3–13 (1990).
26. Schmitz, T. W. & Nathan Spreng, R. & Alzheimer's Disease Neuroimaging, I. Basal forebrain degeneration precedes and predicts the cortical spread of Alzheimer's pathology. *Nat Commun* **7**, 13249, doi:10.1038/ncomms13249 (2016).
27. Teipel, S. *et al.* Cholinergic basal forebrain atrophy predicts amyloid burden in Alzheimer's disease. *Neurobiol Aging* **35**, 482–491, doi:10.1016/j.neurobiolaging.2013.09.029 (2014).
28. Grothe, M. J. *et al.* Basal forebrain atrophy and cortical amyloid deposition in nondemented elderly subjects. *Alzheimers Dement*. doi:10.1016/j.jalz.2013.09.011 (2014).
29. Kerbler, G. M. *et al.* Basal forebrain atrophy correlates with amyloid β burden in Alzheimer's disease. *Neuroimage Clin* **7**, 105–113, doi:10.1016/j.nicl.2014.11.015 (2015).
30. Kerbler, G. M. *et al.* Basal Forebrain Atrophy Contributes to Allocentric Navigation Impairment in Alzheimer's Disease Patients. *Front Aging Neurosci* **7**, 185, doi:10.3389/fnagi.2015.00185 (2015).
31. Dubois, B. *et al.* Research criteria for the diagnosis of Alzheimer's disease: revising the NINCDS-ADRDA criteria. *Lancet neurology* **6**, 734–746, doi:10.1016/S1474-4422(07)70178-3 (2007).
32. Arendt, T., Bruckner, M. K., Morawski, M., Jager, C. & Gertz, H. J. Early neurone loss in Alzheimer's disease: cortical or subcortical? *Acta Neuropathol Commun* **3**, 10, doi:10.1186/s40478-015-0187-1 (2015).
33. Teipel, S. J. *et al.* Measurement of basal forebrain atrophy in Alzheimer's disease using MRI. *Brain* **128**, 2626–2644, doi:10.1093/brain/awh589 (2005).
34. Grothe, M. J. *et al.* Cognitive Correlates of Basal Forebrain Atrophy and Associated Cortical Hypometabolism in Mild Cognitive Impairment. *Cereb Cortex* **26**, 2411–2426, doi:10.1093/cercor/bhv062 (2016).
35. Wolf, D. *et al.* Association of basal forebrain volumes and cognition in normal aging. *Neuropsychologia* **53**, 54–63, doi:10.1016/j.neuropsychologia.2013.11.002 (2014).
36. Bentley, P., Husain, M. & Dolan, R. J. Effects of cholinergic enhancement on visual stimulation, spatial attention, and spatial working memory. *Neuron* **41**, 969–982 (2004).
37. Duzel, S. *et al.* Basal forebrain integrity and cognitive memory profile in healthy aging. *Brain Res* **1308**, 124–136, doi:10.1016/j.brainres.2009.10.048 (2010).
38. Fujii, T. *et al.* The role of the basal forebrain in episodic memory retrieval: a positron emission tomography study. *Neuroimage* **15**, 501–508, doi:10.1006/nimg.2001.0995 (2002).
39. Kerbler, G. M. *et al.* Basal forebrain atrophy correlates with amyloid beta burden in Alzheimer's disease. *Neuroimage Clin* **7**, 105–113, doi:10.1016/j.nicl.2014.11.015 (2015).
40. Perry, E. K. *et al.* Correlation of cholinergic abnormalities with senile plaques and mental test scores in senile dementia. *Br Med J* **2**, 1457–1459 (1978).
41. Arendt, T., Bigl, V., Tennstedt, A. & Arendt, A. Correlation between cortical plaque count and neuronal loss in the nucleus basalis in Alzheimer's disease. *Neurosci Lett* **48**, 81–85 (1984).
42. Potter, P. E. *et al.* Pre- and post-synaptic cortical cholinergic deficits are proportional to amyloid plaque presence and density at preclinical stages of Alzheimer's disease. *Acta Neuropathol* **122**, 49–60, doi:10.1007/s00401-011-0831-1 (2011).
43. Tanaka, Y., Hanyu, H., Sakurai, H., Takasaki, M. & Abe, K. Atrophy of the substantia innominata on magnetic resonance imaging predicts response to donepezil treatment in Alzheimer's disease patients. *Dement Geriatr Cogn Disord* **16**, 119–125, doi:70998 (2003).
44. Teipel, S. J. *et al.* Predictors of cognitive decline and treatment response in a clinical trial on suspected prodromal Alzheimer's disease. *Neuropharmacology* **108**, 128–135, doi:10.1016/j.neuropharm.2016.02.005 (2016).
45. Schuff, N. *et al.* MRI of hippocampal volume loss in early Alzheimer's disease in relation to ApoE genotype and biomarkers. *Brain: a journal of neurology* **132**, 1067–1077, doi:10.1093/brain/awp007 (2009).
46. Teipel, S. J. *et al.* Effects of donepezil on cortical metabolic response to activation during (18)FDG-PET in Alzheimer's disease: a double-blind cross-over trial. *Psychopharmacology (Berl)* **187**, 86–94, doi:10.1007/s00213-006-0408-1 (2006).
47. Goveas, J. S. *et al.* Recovery of hippocampal network connectivity correlates with cognitive improvement in mild Alzheimer's disease patients treated with donepezil assessed by resting-state fMRI. *J Magn Reson Imaging* **34**, 764–773, doi:10.1002/jmri.22662 (2011).
48. Sole-Padullés, C. *et al.* Donepezil treatment stabilizes functional connectivity during resting state and brain activity during memory encoding in Alzheimer's disease. *J Clin Psychopharmacol* **33**, 199–205, doi:10.1097/JCP.0b013e3182825bfd (2013).
49. Bokde, A. L. *et al.* Effects of rivastigmine on visual attention in subjects with amnesic mild cognitive impairment: A serial functional MRI activation pilot-study. *Psychiatry Res* **249**, 84–90, doi:10.1016/j.psychres.2016.01.018 (2016).
50. Mesulam, M. M., Geula, C., Bothwell, M. A. & Hersh, L. B. Human reticular formation: cholinergic neurons of the pedunculopontine and laterodorsal tegmental nuclei and some cytochemical comparisons to forebrain cholinergic neurons. *J Comp Neurol* **283**, 611–633, doi:10.1002/cne.902830414 (1989).
51. Oda, T. *et al.* Donepezil potentiates nerve growth factor-induced neurite outgrowth in PC12 cells. *J Pharmacol Sci* **104**, 349–354 (2007).
52. Auld, D. S., Kar, S. & Quirion, R. Beta-amyloid peptides as direct cholinergic neuromodulators: a missing link? *Trends Neurosci* **21**, 43–49 (1998).
53. Querfurth, H. W. & LaFerla, F. M. Alzheimer's disease. *N Engl J Med* **362**, 329–344, doi:10.1056/NEJMra0909142 (2010).
54. Rubio-Perez, J. M. & Morillas-Ruiz, J. M. A review: inflammatory process in Alzheimer's disease, role of cytokines. *ScientificWorldJournal* **2012**, 756357, doi:10.1100/2012/756357 (2012).
55. Doens, D. & Fernández, P. L. Microglia receptors and their implications in the response to amyloid β for Alzheimer's disease pathogenesis. *J Neuroinflammation* **11**, 48, doi:10.1186/1742-2094-11-48 (2014).
56. Li, S. M., Xu, M. M. & Progress, P. Y. In mechanisms of acetylcholinesterase inhibitors and memantine for the treatment of Alzheimer's disease. *Neuroimmunol Neuroinflammation* **2**, 274–280 (2015).
57. Yoshiyama, Y., Kojima, A., Ishikawa, C. & Arai, K. Anti-inflammatory action of donepezil ameliorates tau pathology, synaptic loss, and neurodegeneration in a tauopathy mouse model. *J Alzheimers Dis* **22**, 295–306, doi:10.3233/JAD-2010-100681 (2010).
58. Rolandi, E., Frisoni, G. B. & Cavado, E. Efficacy of lifestyle interventions on clinical and neuroimaging outcomes in elderly. *Ageing Res Rev* **25**, 1–12, doi:10.1016/j.arr.2015.11.003 (2016).
59. Gold, B. T. Lifelong bilingualism and neural reserve against Alzheimer's disease: a review of findings and potential mechanisms. *Behav Brain Res* **281**, 9–15, doi:10.1016/j.bbr.2014.12.006 (2015).

60. Thomas, J., Thomas, C. J., Radcliffe, J. & Itsopoulos, C. Omega-3 Fatty Acids in Early Prevention of Inflammatory Neurodegenerative Disease: A Focus on Alzheimer's Disease. *Biomed Res Int* **2015**, 172801, doi:10.1155/2015/172801 (2015).
61. Borroni, B. *et al.* ApoE genotype influences the biological effect of donepezil on APP metabolism in Alzheimer disease: evidence from a peripheral model. *Eur Neuropsychopharmacol* **12**, 195–200 (2002).
62. Chupin, M. *et al.* Automatic segmentation of the hippocampus and the amygdala driven by hybrid constraints: method and validation. *Neuroimage* **46**, 749–761, doi:10.1016/j.neuroimage.2009.02.013 (2009).
63. Ashburner, J. & Ridgway, G. R. Symmetric diffeomorphic modeling of longitudinal structural MRI. *Front Neurosci* **6**, 197, doi:10.3389/fnins.2012.00197 (2012).
64. Mesulam, M. M., Mufson, E. J., Levey, A. I. & Wainer, B. H. Cholinergic innervation of cortex by the basal forebrain: cytochemistry and cortical connections of the septal area, diagonal band nuclei, nucleus basalis (substantia innominata), and hypothalamus in the rhesus monkey. *J Comp Neurol* **214**, 170–197, doi:10.1002/cne.902140206 (1983).
65. Mesulam, M. M. & Geula, C. Nucleus basalis (Ch4) and cortical cholinergic innervation in the human brain: observations based on the distribution of acetylcholinesterase and choline acetyltransferase. *J Comp Neurol* **275**, 216–240, doi:10.1002/cne.902750205 (1988).
66. Kilimann, I. *et al.* Subregional basal forebrain atrophy in Alzheimer's disease: a multicenter study. *J Alzheimers Dis* **40**, 687–700, doi:10.3233/JAD-132345 (2014).

Acknowledgements

We would like to acknowledge Dr Line Garnerio who deceased during the study, without her support and experience this study would never have been undertaken. HH is supported by the AXA Research Fund, the Fondation Université Pierre et Marie Curie and the Fondation pour la Recherche sur Alzheimer, Paris, France. Ce travail a bénéficié d'une aide de l'Etat « Investissements d'avenir » ANR-10-IAIHU-06 (HH). The research leading to these results has received funding from the program “Investissements d'avenir” ANR-10-IAIHU-06 (Agence Nationale de la Recherche-10-IA Agence Institut Hospitalo-Universitaire-6) (HH).

Author Contributions

E.C. pre-processed the data, conducted the analyses and wrote the manuscript; M.J.G. and S.T. supported data analysis, defined the BFCS nomenclature and edited the manuscript; O.C. and S.L. edited the manuscript, M.C. collected the neuroimaging data and performed the MRI quality control; M.H. conducted part of the statistical analysis; D.D. and B.D. being the principal coordinators of the Hippocampus Study Group supervised the clinical and neuroimaging data collection and edited the manuscript. H.H. supervised the manuscript development and wrote the manuscript. The Hippocampus Study Group collected the clinical and neuroimaging data.

Additional Information

Supplementary information accompanies this paper at doi:10.1038/s41598-017-09780-3

Competing Interests: The clinical trial with Donepezil leading to the analysed dataset was supported by Eisai SAS France. Eisai SAS France supported for data collection and for the investigation of the primary endpoint of the study. Dr Cavado, Dr Grothe, Dr Chupin, Dr Teipel and Dr Dormont declare no competing financial interests related to the present article. Dr Dubois has received consulting fees from Eli Lilly, Dr Dubois have received Grant support from Pfizer in 2012; Dr Colliot declares no competing financial interests related to the present article, Dr Colliot he has received consulting fees from Guerbet and lecture fees from Lundbeck and Roche. Dr Lista has received lecture fees from Roche. Dr Hampel, Dr Cavado and Dr Lista are supported by the AXA Research Fund, the Université Pierre et Marie Curie and the “Association pour la Recherche sur Alzheimer”, Paris, France. Dr Hampel declares no competing financial interests related to the present article. During the last 36 months Dr Hampel has received lecture honoraria and/or research grants (paid to the institution) and/or travel funding and/or participated in scientific advisory boards and/or as a consultant to diagnostic, biotechnology and pharmaceutical companies involved in the manufacture and marketing of biomarkers and/or diagnostics and/or drugs or medicinal products for cognitive impairment and Alzheimer's disease including Roche Pharmaceuticals and Diagnostics, GE Healthcare, Avid, Eli Lilly and Company, GlaxoSmithKline-Biologics, Jung-Diagnostics, Cytos, Anavex, Axovant, Biogen Idec, Oryzon Genomics. He is co-inventor in patents relating to biological markers and/or diagnostics and has not received any royalties.

Publisher's note: Springer Nature remains neutral with regard to jurisdictional claims in published maps and institutional affiliations.



Open Access This article is licensed under a Creative Commons Attribution 4.0 International License, which permits use, sharing, adaptation, distribution and reproduction in any medium or format, as long as you give appropriate credit to the original author(s) and the source, provide a link to the Creative Commons license, and indicate if changes were made. The images or other third party material in this article are included in the article's Creative Commons license, unless indicated otherwise in a credit line to the material. If material is not included in the article's Creative Commons license and your intended use is not permitted by statutory regulation or exceeds the permitted use, you will need to obtain permission directly from the copyright holder. To view a copy of this license, visit <http://creativecommons.org/licenses/by/4.0/>.

© The Author(s) 2017

Consortia Hippocampus Study Group

**Bernard Croisile¹⁴, Guy Louis Tisserand¹⁵, Alain Bonafe¹⁶, Pierre J Ousset¹⁷, Olivier Rouaud¹⁸,
Frédéric Ricolfi¹⁸, Alain Vighetto¹⁹, Florence Pasquier²⁰, Christine Delmaire²¹, Mathieu
Ceccaldi²², Nadine Girard²², Françoise Duveau²³ & Marie Sarazin²⁴**

¹⁴Department of Neuropsychology, Hôpital Neurologique Pierre Wertheimer, Lyon, France. ¹⁵Hôpital Neurologique Pierre Wertheimer, Lyon, France. ¹⁶CHRU, Gui de Chauliac, Montpellier, France. ¹⁷Centre Mémoire/Centre de Recherche Clinique – Gérotopôle, Hôpital Casselardit, Toulouse, France. ¹⁸Hôpital General, Dijon, France. ¹⁹Lyon 1 university, Hospices Civils de Lyon, hôpital neurologique, service de neurologie D, Lyon, France. ²⁰Université de Lille, Inserm U1171, CHU, centre mémoire 59000, Lille, France. ²¹Université de Lille, Inserm U1171, Service de Neuroradiologie, Hôpital Roger Salengro, Lille, France. ²²Hôpital de la Timone, Marseille, France. ²³Eisai SAS, La Defense 2, Cedex, France. ²⁴Neurologie de la Mémoire et du Langage, Université Paris Descartes, Sorbonne Paris Cité, INSERM UMR S894, Centre Hospitalier Sainte Anne, Paris, France.