



HAL
open science

MR for stents and other device delivery

Harald Quick

► **To cite this version:**

Harald Quick. MR for stents and other device delivery. CI2BM09 - MICCAI Workshop on Cardiovascular Interventional Imaging and Biophysical Modelling, Sep 2009, London, United Kingdom. pp.122-123. inria-00417899

HAL Id: inria-00417899

<https://inria.hal.science/inria-00417899>

Submitted on 17 Sep 2009

HAL is a multi-disciplinary open access archive for the deposit and dissemination of scientific research documents, whether they are published or not. The documents may come from teaching and research institutions in France or abroad, or from public or private research centers.

L'archive ouverte pluridisciplinaire **HAL**, est destinée au dépôt et à la diffusion de documents scientifiques de niveau recherche, publiés ou non, émanant des établissements d'enseignement et de recherche français ou étrangers, des laboratoires publics ou privés.

MR for stents and other device delivery

Harald H. Quick, PhD

Department of Diagnostic and Interventional Radiology

University Hospital Essen, Essen, Germany

Harald.Quick@uni-due.de

Introduction

Several attributes make MRI attractive for guidance of intravascular therapeutic procedures. For MR-guidance of vascular interventions the interventionalist must be able to visualize guidewires, catheters, and other vascular devices such as stents and stent-grafts relative to the vascular system and surrounding tissues. Numerous approaches for rendering flexible, small diameter instruments visible in an MR environment have been developed, including *passive* and *active* techniques.

Methods and Materials

Passive techniques depend on contrast agents or susceptibility artifacts which enhance the appearance of the catheter in the image itself, whereas *active* techniques rely on supplemental hardware built into the catheter, such as radiofrequency (RF) coils. Traditional active visualization approaches like “tip-tracking”, “profiling”, and “dipole antennas” required connection of the instruments to the scanner with either coaxial cable or laser fibers. The more recent approach of wireless active catheter visualization uses inductive signal coupling between a catheter RF coil and surface coils to supersede the need for cable connections. Most experiments and concept evaluation studies so far have been performed in swine.

Results

Passive instrument visualization techniques in general are less demanding on device complexity, and when not containing any conductive material mostly can be considered as safe with regards to potential RF-heating. *Passive* instruments, however, often provide only poor contrast and thus reduced visibility especially *in vivo*. *Active* techniques here have shown robust and reliable instrument contrast and furthermore allow for instrument position feedback.

Conclusion

The additional capabilities of MRI could potentially open up new applications within the purview of vascular interventions beyond those currently performed under X-ray fluoroscopic guidance.

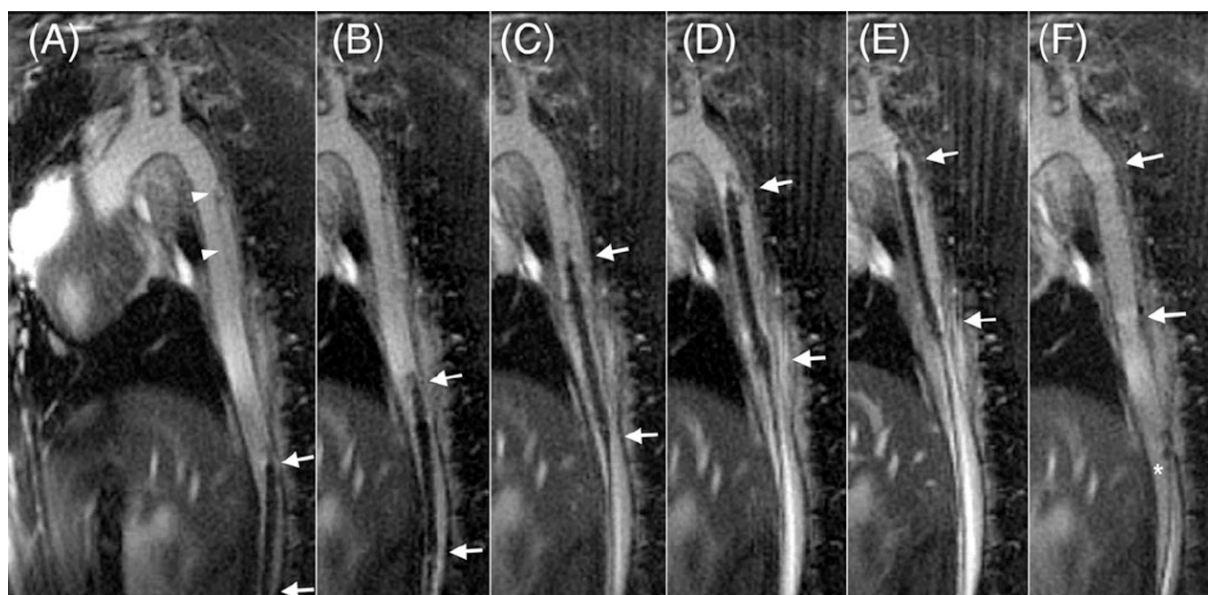


Fig. 1: Safe advancement of an aortic stent-graft delivery system (arrows) in a pig model of aortic dissection. The stent-graft is delivered up to the level of the dissection (arrowheads) under real-time MRI guidance. (F) The correct stent-graft position (arrows) is confirmed immediately after graft deployment showing complete coverage of the dissection.

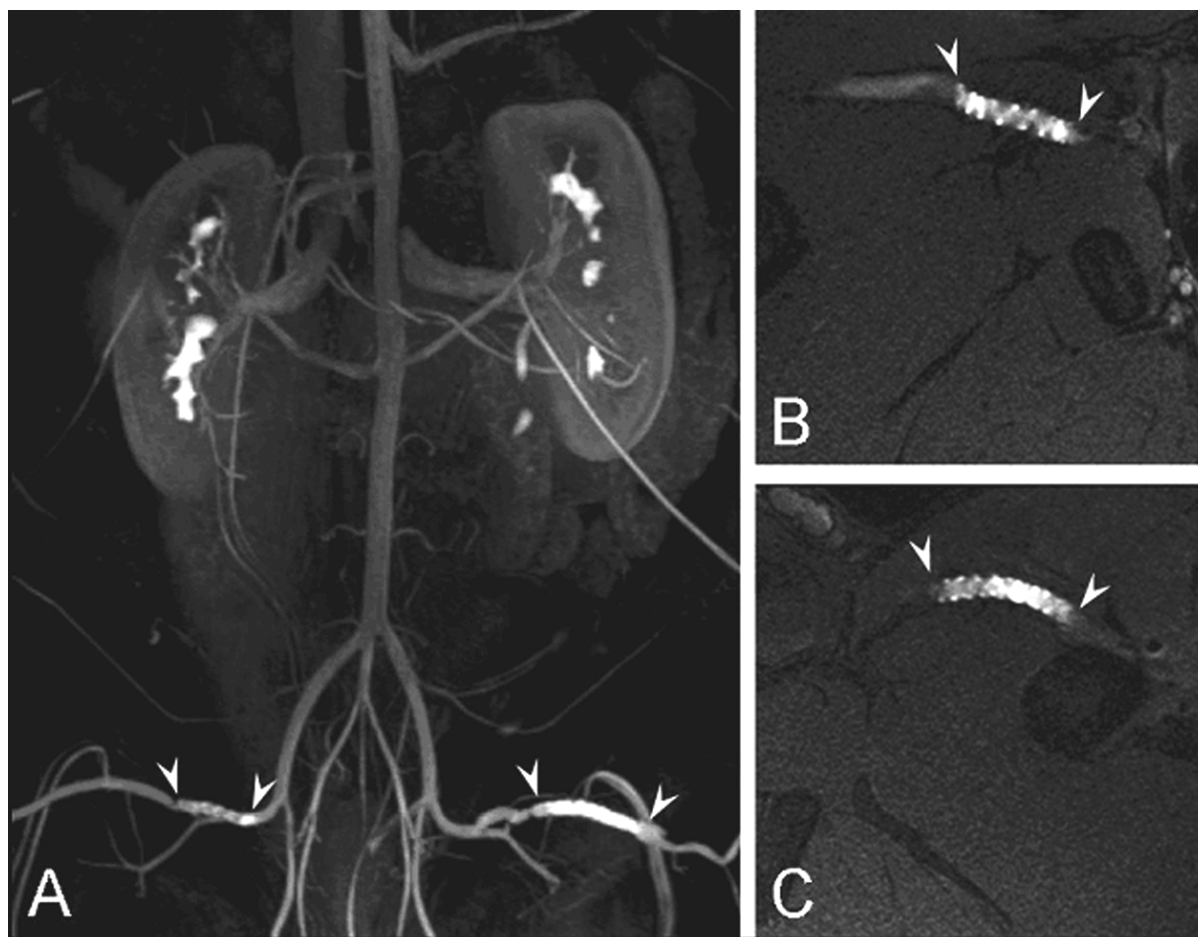


Fig. 2: Active visualization of active stent resonators in the iliac arteries of a pig. The MR angiogram (MRA) in (A) shows the position of the two stent resonators in the iliac arteries. The stents provide bright signal from their interior. Images (B) and (C) show amplified signal intraluminal in both stent resonators. Active stent visualization can be performed with inductive signal coupling not requiring any cable connection.

References

1. Quick HH, Kuehl H, Kaiser G, Bosk S, Debatin JF, Ladd ME: Inductively coupled stent antennas in MRI. *Magn Reson Med.* 2002 Nov;48(5):781-90.
2. Quick HH, Kuehl H, Kaiser G, Hornscheidt D, Mikolajczyk KP, Aker S, Debatin JF, Ladd ME: Interventional MRA using actively visualized catheters, TrueFISP, and real-time image fusion. *Magn Reson Med.* 2003 Jan;49(1):129-37.
3. Quick HH, Zenge MO, Kuehl H, Kaiser G, Aker S, Massing S, Bosk S, Ladd ME: Interventional magnetic resonance angiography with no strings attached: wireless active catheter visualization. *Magn Reson Med.* 2005 Feb;53(2):446-55.
4. Eggebrecht H, Zenge M, Ladd ME, Erbel R, Quick HH: In vitro evaluation of current thoracic aortic stent-grafts for real-time MR-guided placement. *J Endovasc Ther.* 2006 Feb;13(1):62-71.
5. Eggebrecht H, Kühl H, Kaiser GM, Aker S, Zenge MO, Stock F, Breuckmann F, Grabellus F, Ladd ME, Mehta RH, Erbel R, Quick HH: Feasibility of real-time magnetic resonance-guided stent-graft placement in a swine model of descending aortic dissection. *Eur Heart J.* 2006 Mar;27(5):613-20.