



3D+t Modeling of Coronary Artery Tree from Standard Non Simultaneous Angiograms

Fabien Mourgues, Frédéric Devernay, Grégoire Malandain, Ève Coste-Manière

► To cite this version:

Fabien Mourgues, Frédéric Devernay, Grégoire Malandain, Ève Coste-Manière. 3D+t Modeling of Coronary Artery Tree from Standard Non Simultaneous Angiograms. Medical Image Computing and Computer-Assisted Intervention - MICCAI 2001, Oct 2001, Utrecht, Netherlands. pp.1320-1322, 10.1007/3-540-45468-3_213 . inria-00267253

HAL Id: inria-00267253

<https://inria.hal.science/inria-00267253>

Submitted on 26 Mar 2008

HAL is a multi-disciplinary open access archive for the deposit and dissemination of scientific research documents, whether they are published or not. The documents may come from teaching and research institutions in France or abroad, or from public or private research centers.

L'archive ouverte pluridisciplinaire **HAL**, est destinée au dépôt et à la diffusion de documents scientifiques de niveau recherche, publiés ou non, émanant des établissements d'enseignement et de recherche français ou étrangers, des laboratoires publics ou privés.

3D+t Modeling of Coronary Artery Tree from Standard Non Simultaneous Angiograms

Fabien Mourgues, Frédéric Devernay,
Grégoire Malandain, and Ève Coste-Manière

CHIR Team,
www.inria.fr/chir
INRIA, 2004 route des lucioles,
06902 Sophia-Antipolis Cedex, France

Abstract. 3D models of coronary arteries is a valuable help for the planning and simulation of minimally-invasive cardiac surgery, and may be used in per-operative augmented reality. We propose a method to build a time-variant model of the coronary artery tree from standard non simultaneous angiograms. The semi-automatically extracted and labeled tree is tracked in each sequence by B-snakes with an image energy term deduced from a multi-scale model-based preprocessing. Then, from two projections synchronized with the electrocardiogram, a non simultaneous stereoscopy method is used to build the 3D skeletonized coronary artery tree. The heart shift and deformation between acquisitions problem - mainly due to patient's breathing and motion - is solved by simultaneously optimizing the sensor geometry. Finally 3D sections are estimated from the projected sections.

1 Introduction

The robotically assisted totally endoscopic coronary artery bypass avoids the opening of the thorax and limits post-operative consequences. On the other hand, the confined vision delivered by the endoscope greatly increases the difficulty of locating the concerned arteries. We propose as described in [2], to enhance the surgeon's endoscopic vision with a 3D+t model of the coronary artery tree, thus helping him find his target (position of the anastomosis on the correct artery) in the surgical context.

After fusion with the epicardium surface obtained by other imaging modalities (gated MRI or CT-scan), the coronary artery tree model will be integrated in a planning and simulation system for robotically assisted surgery [1] and in second time, its real-time registration in the operating context will guide the surgeon's gesture by augmented reality [2]. Future improvements will make applications to diagnostic and follow-up of the coronary artery diseases possible.

X-rays angiography is a classical way of coronary artery imaging. These two-dimensional projections grouped in a sequence in which patient is breathing, are obtained after an invasive catheterization procedure. The sequence is unique with single-view systems (bolus injection and acquisition must be repeated), while in biplane angiography, two simultaneous acquisitions (frequently perpendicular)

are provided before the contrast agent diffuses. Biplane angiography [13,15,16] makes the 3D modeling easier but suffers from the higher cost of these devices. As a remedy, it has been proposed [12] to introduce heart motion and deformation model in order to achieve the 3D modeling from a single-view cineangiogram. However, we feel that non simultaneous incidences can give as much 3D informations as biplane angiography.

We propose in this article a method to construct a 3D+t model of the coronary artery tree from non-simultaneous sequences, synchronized with the electrocardiogram and acquired on a standard and widespread single-view angiograph. The developed approach, illustrated on figure 1, is composed as follows:

A first stage consists in extraction and labeling of the coronary artery tree in the different projections. The segmentation problem has been addressed by precisely extracting an user-defined artery segment [14] or by recursively analyzing borders of arteries, to extract the complete tree from a seed point [7]. Some have introduced prior 3D anatomic knowledge [16] or temporal analysis in sequence [4] to disambiguate the computationally expensive problem of labeling and matching arteries. We chose a semi-automatic method: the arteries to be reconstructed are selected and labeled in one image of each sequence with an interactive tool which relies on a multi-scale model-based preprocessing. The hierarchical structure of the tree is automatically determined.

In a second step, segmentation and labeling informations have to be propagated in the different projections during at least one cardiac beat. This problem has been addressed by grouping and matching artery portions in consecutive frames [12], by poly-line approximation and optimization [3], or by Snakes based on correlation criterion [6]. Our approach is lying on the hierarchical description of the coronary tree, and the modeling of the arteries by B-snakes with an internal energy deduced from the multi-scale model-based preprocessing. A two-steps optimization reduces the effects of large displacements, crossing and overlapping arteries.

Then, in a third stage, 3D modeling of the coronary artery tree is performed from two segmented projections corresponding roughly to the same cardiac time. As they are extracted from two different sequences, heart motion may occur due to patient's motion or simply breathing (in the latter, the largest value for the inferior-superior translation of the Left Anterior Descending artery is about 10 mm [10]). We overcome this difficulty by creating a coherent 3D model by alternately matching the artery pixels strings and optimizing the sensor parameters. Finally, the 3D skeleton is enriched with 3D sections estimated from the acquisition geometry and the scale extracted in the multi-scale preprocessing.

In the next three paragraphs, we enter into details of the proposed approach, before we discuss the results and future improvements.

2 2D Segmentation and Labeling

This stage consists in a multi-scale preprocessing of the sequences and a semi-automatic extraction and labeling of the coronary tree in a single image of each sequence.

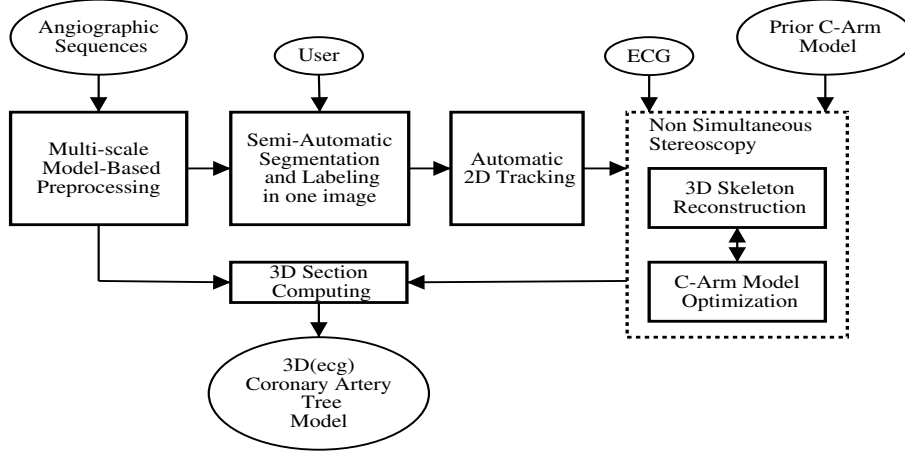


Fig. 1. 3D+t coronary tree reconstruction method from several angiographic sequences.

2.1 Multi-Scale Model-based Preprocessing

In the input images, background and foreground structures are visible since subtracting images is not feasible: X-rays are invasive and acquiring projections without contrast agent is not clinically acceptable. Moreover, it is difficult to subtract images because of the patient breathing and motion.

The arteries are tubular, variable-size structures characterized by their two edges. To isolate them, we use a multi-scale criterion based of the vessel model proposed in [8,14], and more precisely studied for 3D vessels in [9]. The multi-scale analysis is achieved with a variable Gaussian kernel σ and the resulting criterion is - for each image point - the highest response in scale-space: $R_{\sigma_{max}}(u) = \max_{\sigma}[R_{\sigma}(u)]$. Added to this centerline magnitude, the presumed direction $dl(u)$ of the vessel (unit tangent vector) is obtained from the lowest eigen-vector of the Hessian matrix of the image at scale σ . The scale of the highest response $\sigma_{max}(u)$ is saved.

The scale range is chosen according to the size of searched structures. Figure 2) illustrates this multi-scale response.

2.2 Semi-Automatic Segmentation and Labeling

Among the frames in angiographic sequence, the cardiologist chooses the one in which the coronary tree can be clearly observed. Then, he selects arteries to be reconstructed with a tool inspired from the intelligent scissors [11] that relies on the presented multi-scale response. Finally, the cardiologist points the root-artery and the hierarchical structure is automatically constructed.

The proposed interactive segmentation tool works as follows: from an user-defined seed point, the artery centerline is captured in the neighborhood of the mouse with a shortest path algorithm to the current mouse position. Only the n last pixels are constantly optimized in a sleeping window and the correction

is possible by back-tracking and guiding the optimized segment through an alternative orientation.

The shortest path criterion consists of two terms: the first is based on the multi-scale magnitude $R_{\sigma_{max}}(u)$ and penalizes points as they get away from the centerlines. The second regularizes the problem by penalizing directions different than that of the presumed vessels $dl(u)$. This shortest path problem is solved for using dynamic programming with an 8-connexity neighborhood.

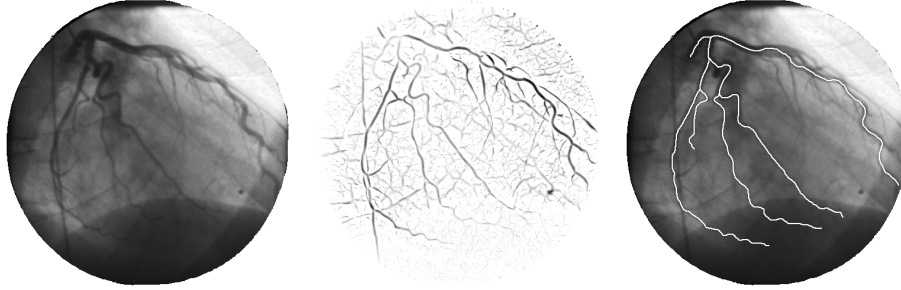


Fig. 2. An original 512×512 image, his multi-scale response (scales from 1 to 3 pixels) and the semi-automatically extracted and labeled tree.

3 Coronary Artery Tree 2D Tracking

The extracted and labeled tree must be tracked through the rest of the angiograms, where motions are due to heart beating, patient's motion and breathing. Each artery is modeled by a B-spline, allowing a relatively precise description with a small number of parameters. The frame to frame tracking process is formulated as an energy minimization problem as proposed by Kass et al. for contour segmentation. Our image energy is the mean of the multi-scale response along the B-spline. A regularization term is added to ensure the good behavior of the B-snakes. To make the tracking process robust to arteries overlap and crossing, and to be able to handle more important artery motion, a two-stage optimizing is achieved:

1. B-splines are globally transformed to permit a rough but large shift. As described in [12], heart beating can be approached by a translation, scaling and rotation movement. Therefore we use a 2D affine transformation.
2. the B-spline polygon control points are individually optimized to fit the artery centerlines.

The arteries are individually tracked in top-down method according to their hierarchical position in the tree, and the structure of the tree is conserved in each frame by reconnecting arteries to their mother with a shortest-path algorithm on the multi-scale response.

4 Stereoscopy on Synchronized Images

The initial segmented tree is propagated through the whole heart cycle in the different sequences. The aim of the third step is to reconstruct, for each cardiac instant, the 3D coronary artery tree from the available labeled projections.

C-arm geometry is approached for each incidence with a pinhole camera model improved with a radial distortion calibration from a grid. Unfortunately, two synchronized projections do not exactly represent the same 3D scene because of the 3D heart shift (due to patient's motion and breathing), the 3D heart deformation (due to possible patient's arrhythmia and temporal resolution of the sequences) and the uncertainties on C-arm model (some deformation is caused by the weight of the X-rays source and the detector). Therefore, we have addressed the 3D scene determination problem by simultaneously reconstructing the 3D artery centerlines and optimizing the C-arm acquisition model. Then in a second step, the skeleton is enhanced with its 3D sections.

4.1 Artery Centerlines Point-to-Point Matching

In two synchronized images, artery centerlines are globally matched using their label. The artery roots and junctions can directly be paired (A and C on fig. 3). The remaining centerline points are matched, according to the available epipolar geometry [5], starting from the artery roots. We introduce a cost on the distance to the epipolar lines (c_1 on fig. 3), a term to ensure that the deviation from epipolar geometry varies smoothly (c_2 on fig. 3) and a penalty which constraints the match of all the junctions on the considered artery (c_3 on fig. 3). The symmetrical penalties obtained by reversing the role of the two images are added, and this shortest path problem is solved for using dynamic programming. The number of candidate matches is reduced by searching within a band around the epipolar line (see fig. 3).

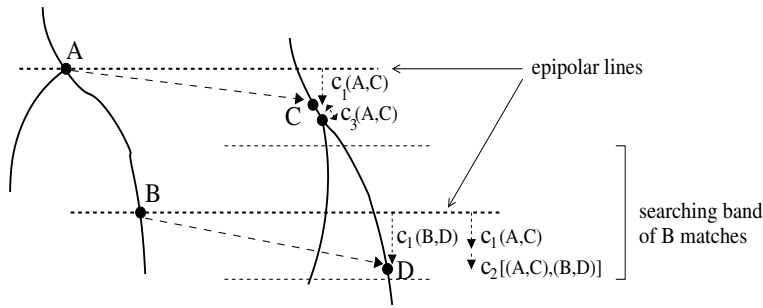


Fig. 3. The penalties of the matching criteria: c_1 penalizes matches which do not respect epipolar geometry, c_2 ensures the deviation continuity from epipolar geometry and c_3 encourages the matching of A and C bifurcations.

4.2 Reconstruction and Bundle-Adjustment

After the previous step, all the artery centerlines are matched point-to-point. However, to ensure a good matching of the features, we authorized some deviations from the strict available epipolar geometry. A direct 3D reconstruction from the paired points gives some bad back-projections in images. To improve the 3D scene coherence, sensors parameters have to be optimized, mainly the extrinsic parameters of the two projection matrices, to correct for 3D heart shift. A classical bundle-adjustment method, accomplished on the whole coronary artery tree minimizes the errors between the projected 3D reconstructed points and the 2D paired points. We optimize only the translation of the camera models in their image plane because the consequences of the 3D heart shift along the optical axis are limited (the focal length is important). When this geometry optimization is achieved, the point-to-point matching process is repeated starting from the newly obtained epipolar geometry. This (2D-matching)-(3D-reconstruction)-(geometry optimization) loop is repeated until the stabilization of the 3D reconstructed scene is measured. Some optimization results are illustrated on figure 4.

After the reconstruction is complete, 3D sections are estimated from the detection-scale of the multi-scale analysis and from the sensors parameters (see on figure 5 a 3D coronary artery tree).

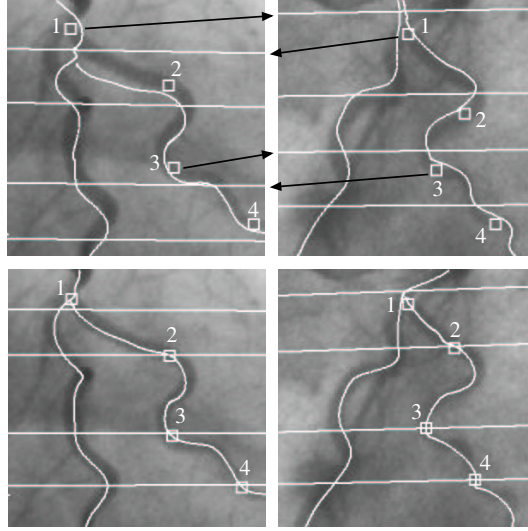


Fig. 4. The first row shows some four initial matches on the extracted arteries, the epipolar lines and back-projection of initially reconstructed 3D centerlines. The second row shows the final back-projection and the epipolar lines after sensors optimizing. The first camera was $-0.0861mm$ horizontally and $3.81mm$ vertically adjusted. The second one was $0.3861mm$ horizontally and $-3.98mm$ vertically adjusted.

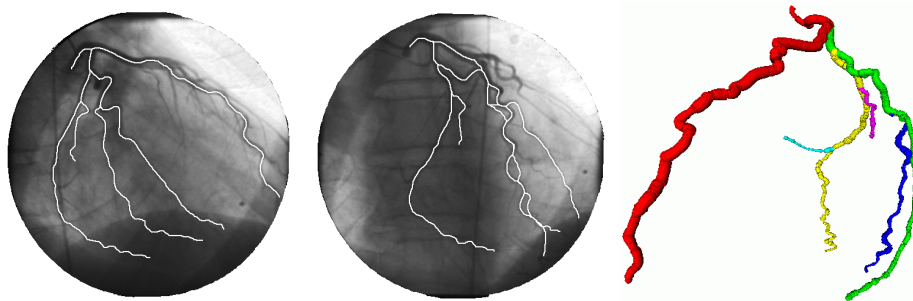


Fig. 5. Two synchronized projections and the final reconstructed tree with sections.

5 Discussion

In this paper we have presented a method for building a time-variant 3D model of the coronary artery tree from standard non-simultaneous angiograms. It has been successfully applied to angiograms acquired on a single-view angiograph, as well as to sequences acquired on a biplane angiograph. The approach requires some user-interaction to select the arteries to be reconstructed and the labeled tree is automatically propagated in 2D through the rest of sequences by using B-snakes. The 3D reconstruction method handles the fact that acquisitions are not simultaneous by using weak epipolar constraints and global heart motion between acquisition is compensated by bundle-adjustment on the C-arm geometric models. Finally, the 3D skeletons are enriched with corresponding 3D sections deduced from the multi-scale preprocessing of projections.

We hope to improve the robustness of the tracking by directly deforming the 3D model obtained at one cardiac instant rather than computing independently the 3D reconstruction. Using its back-projections in all the available sequences would eliminate the arteries overlap and crossing problems. Moreover, the measure of sections in all the projections will enable a better quantification of the shape and size of the 3D sections.

After clinical validation, this time-variant 3D model can be helpful for cardiovascular diseases diagnostic and surgical planning. It can also be fused with the epicardium surface obtained by other imaging modalities and integrated in a planning and simulation system for robotically assisted surgery [1]. Its registration with the endoscopic images in the operating theater requires some new developments and will allow to guide the surgeon by augmented reality [2].

6 Acknowledgments

We would like to thank Régis Vaillant from GE Medical Systems, Global X-Ray Advanced Applications, and Didier Blanchard from Georges Pompidou European Hospital for their help in providing patient data and feedback as well as Louaï Adhami for his review of this manuscript.

References

1. L. Adhami, E. Coste-Manière, and J.-D. Boissonnat. Planning and simulation of robotically assisted minimal invasive surgery. In *Proceedings MICCAI*, volume 1935 of *Lecture Notes in Computer Science*. Springer, Oct. 2000.
2. F. Devernay, F. Mourgues, and E. Coste-Manière. Towards endoscopic augmented reality for robotically assisted minimally invasive cardiac surgery. In *Proceedings of Medical Imaging and Augmented Reality*, 2001.
3. M.-P. Dubuisson-Jolly, C. Liang, and A. Gupta. Optimal polyline tracking for artery motion compensation in coronary angiography. In *International Conference in Computer Vision*, pages 414–419, 1998.
4. N. Ezquerro, S. Capell, L. Klein, and P. Duijves. Model-guided labeling of coronary structure. *IEEE Transactions on Medical Imaging*, 17:429–441, 1998.
5. O. Faugeras. *Three-Dimensional Computer Vision*. MIT Press, 1993.
6. S. Grosskopf and A. Hildebrand. 3D reconstruction of coronary arteries from X-ray projections. In *Proceedings Computer Assisted Radiology*, 1995.
7. K. Haris, S. Efstratiadis, N. Maglaveras, C. Pappas, and J. Gourassas. Model-Based morphological segmentation and labeling of coronary angiograms. In *IEEE Transactions on Medical Imaging*, volume 10, pages 1003–1015, Oct. 1999.
8. T. Koller, G. Gerig, G. Szekely, and D. Dettwiler. Multiscale detection of curvilinear structures in 2D and 3D image data. *ICCV*, pages 864–869, June 1995.
9. K. Krissian, G. Malandain, N. Ayache, R. Vaillant, and Y. Troussset. Model-based detection of tubular structures in 3D images. *Computer Vision and Image Understanding*, 80:130–171, 2000.
10. K. Manke, D. and Nehrke, P. Rosch, and O. Dossel. Study of respiratory motion of the heart in coronary MR angiography. *International Journal of Bioelectromagnetism*, 2(2), Sept. 2000.
11. E. Mortensen and W. Barrett. Intelligent scissors for image composition. In *Computer Graphics Proceedings*, pages 191–198, 1995.
12. T. Nguyen and J. Sklansky. Reconstructing the 3D medial axes of coronary arteries in single-view cineangiograms. *IEEE Transactions on Medical Imaging*, 13:61–73, Mar. 1994.
13. S. Ruan, A. Bruno, and J. Coatrieux. Three-dimensional motion and reconstruction of coronary arteries from biplane cineangiography. *Image and Vision Computing*, 12(10):683–689, Dec. 1994.
14. T. Sato, T. Araki, M. Hanayama, H. Naito, and S. Tamura. A viewpoint determination system for stenosis diagnosis and quantification in coronary angiographic image acquisition. *IEEE Transactions on Medical Imaging*, 17(1), 1998.
15. A. Wahle, H. Oswald, and E. Fleck. 3D heart-vessel reconstruction from biplane angiograms. *IEEE Computer Graphics and Applications*, 16:65–73, Jan. 1996.
16. P. Windiga, M. Garreau, and J. Coatrieux. Estimation of search-space in 3D coronary artery reconstruction using biplane images. *Pattern Recognition Letters*, 19:1325–1330, Sept. 1998.