

# Radiosurgical planning of brain arteriovenous malformations (AVMs): a user interface for the delineation of 3D target from 2D angiographic projections

<sup>1</sup>Anxionnat R, <sup>2</sup>Kerrien E, <sup>2</sup>Berger MO, <sup>1</sup>Bracard S, <sup>1</sup>Picard L  
<sup>1</sup>Department of Diagnostic and Interventional Neuroradiology. University Hospital. Nancy, France.  
<sup>2</sup>LORIA/INRIA Lorraine, France

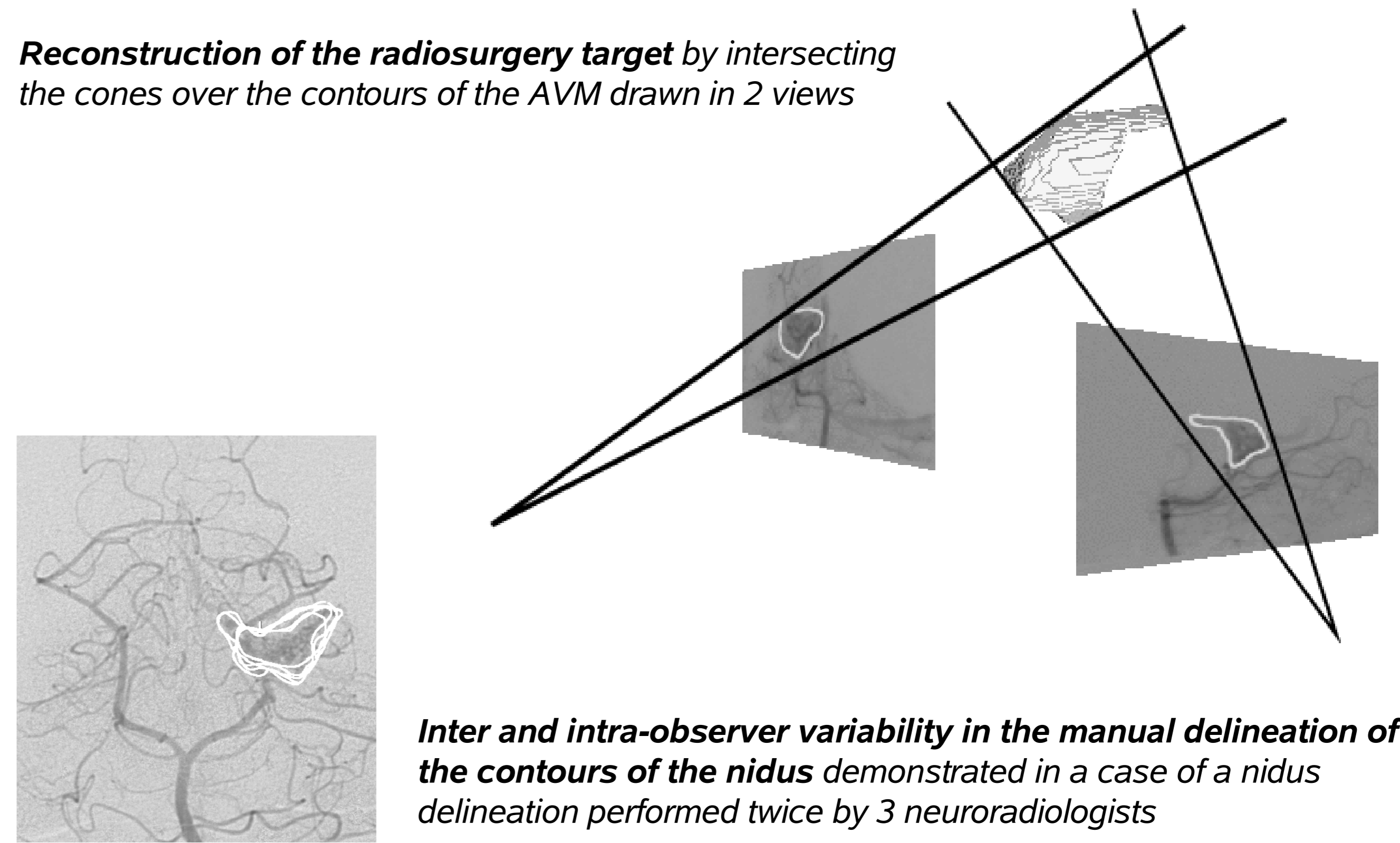
## PURPOSE

1. to describe an original and helpful user interface to delineate a 3D target by drawing its contours on multiple 2D projections from DSA
2. to clinically validate the interest of this interface

## CLINICAL CONTEXT

- Precise delineation of the target is a critical part of radiosurgical treatment
  - *Inappropriate target decreases efficacy of radiosurgery and increases risk of radionecrosis*
- Target delineation is performed by drawing the contours of the nidus, the active part of the AVM, on calibrated (using a stereotactic frame) digital subtraction angiography (DSA) projections assuming that DSA remains the imaging gold standard.
  - *The target volume is reconstructed as the intersection of the cones of projection from these contours on different views, usually AP and lateral (see figure on the right)*
- This manual delineation is a difficult and time consuming task.
  - *Some part of the nidus are often difficult to draw on angiography projections because of superimpositions*
  - *Consequently inconsistencies between the delineations performed in the different views, usually AP and lateral, are frequent*
- Currently available softwares don't show these inconsistencies and don't allow to correct them, this result in
  - *a bad reproducibility and repeatability in the 3D target delineation [1]. (see figure on the right)*
  - *an inappropriate target and therefore a poor anatomical result*

**Reconstruction of the radiosurgery target by intersecting the cones over the contours of the AVM drawn in 2 views**



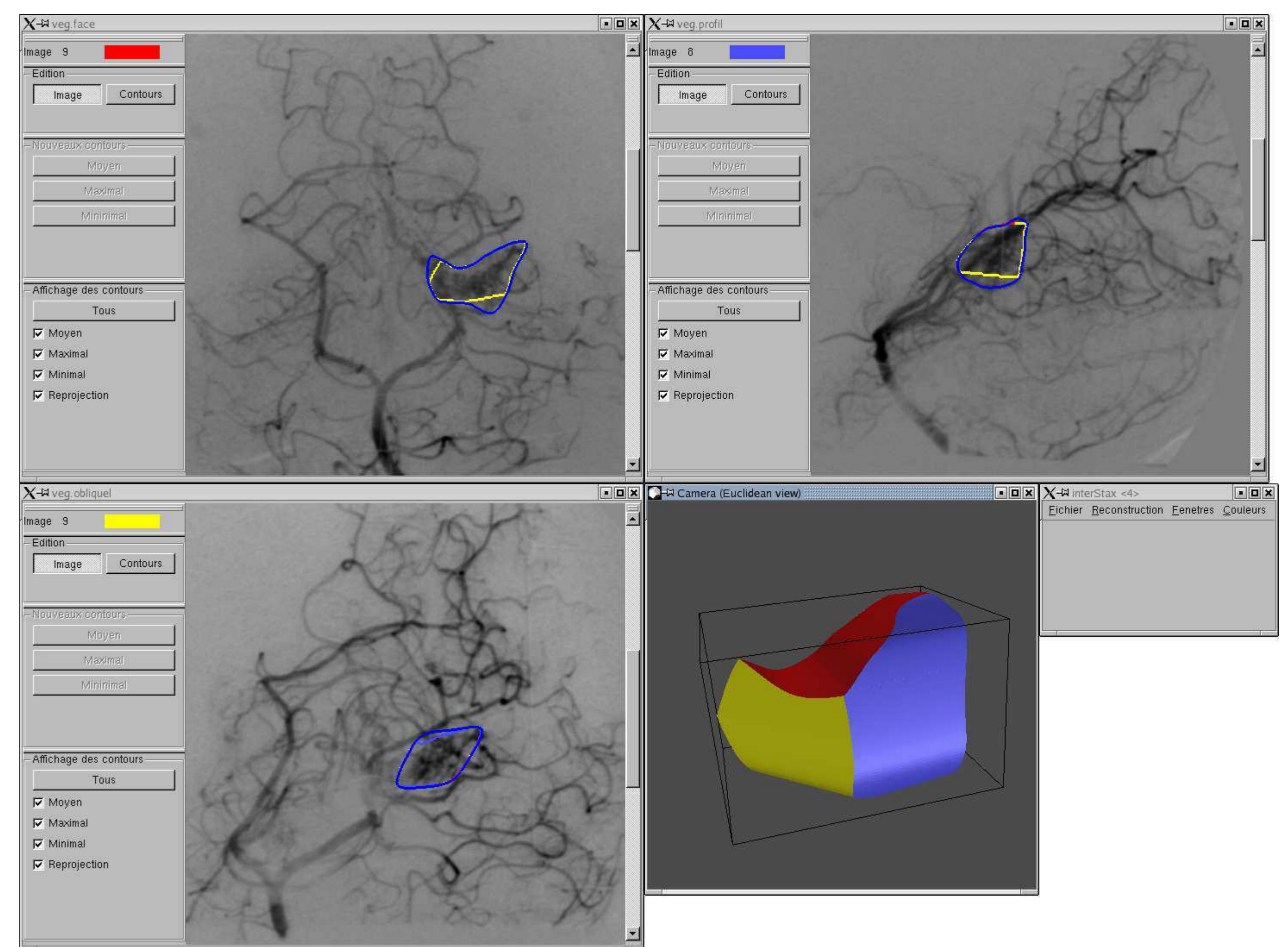
**Inter and intra-observer variability in the manual delineation of the contours of the nidus demonstrated in a case of a nidus delineation performed twice by 3 neuroradiologists**

## DESCRIPTION OF THE USER INTERFACE

- This software can read DSA temporal series in DICOM format.
- These images must be calibrated using a stereotactic frame.
- The neuroradiologist draws the contours on the different views and, at any time, he can
  - Reconstruct and analyze the resulting 3D target (intersection of the cones of projection).
  - Visualize the reprojected contours of this 3D target to compare them to the initial contours.
  - Correct these contours if necessary.
- Contours may be saved and reloaded and the target may be saved in geomview format (free 3D visualization software available at <http://www.geomview.org>).
- The software was written under Linux using Qt (platform-independent software library used to build graphical user interface, available at <http://www.trolltech.com>) and OpenGL to enable easy port to Windows.

### Example of session using the user interface

One window opens per series (AP, lateral and two oblique in this case). In each image window, image zoom, pan and window/level tuning is available, as well as review of dynamic series. One contour was drawn on each view, as a spline whose control points are manually inserted. Target volume is automatically reconstructed and displayed. This volume is reprojected on each view and can be compared with initial delineations to demonstrate inconsistencies and to correct them.



## VALIDATION OF THE INTERFACE

- Purpose: to demonstrate that on-line 3D target visualization and ensured consistency of the contours improve the performances and the confidence of the neuroradiologist.
- Materiel: 7 AVMs treated by radiosurgery .
- Method: One neuroradiologist (RA) delineated the contours
  - twice using the classical method (neither 3D reconstruction nor reprojction of the target)
  - twice using all the software features.
- The repeatability of the target delineation using each method was quantified by calculating the similarity index \* [2] (see exemple and definition on the right). A ratio above 70% is usually interpreted as a good agreement between volumes.
  - **Similarity index** =  $2 \cdot \text{Vol}_{\text{target1} \cap \text{target2}} / (\text{Vol}_{\text{target1}} + \text{Vol}_{\text{target2}})$ . It is a measure of comparison between 2 volumes which takes into account both the shape and the respective location of these volumes. It is derived from kappa measure of agreement.
- Results:
  - 77.7% in the classical method versus 82.4% using the new features of the interface: **significant improvement by 4.7% (p=0.007)**
  - Moreover the subjective expert's feelings concerning the software were quite favourable as it made him feel **more confident in the final target**.

## CONCLUSION

We developed a user interface for AVM delineation from DSA images that provides on-line 3D reconstruction and view-indexed reprojction of the target on the original DSA images. The interest of this interface was proved in a preliminary study and will be analysed on a largest study involving more AVMs and experts.