



**HAL**  
open science

## Machine-learning based guided diagnosis of parotid tumours from MRI

Arnaud Quillent, Samy Ammari, Emilie Chouzenoux, Víctor Elvira, Nathalie Lassau

► **To cite this version:**

Arnaud Quillent, Samy Ammari, Emilie Chouzenoux, Víctor Elvira, Nathalie Lassau. Machine-learning based guided diagnosis of parotid tumours from MRI. ISBI 2023 - IEEE International Symposium on Biomedical Imaging, Apr 2023, Cartagena (Colombia), Colombia. hal-04407914

**HAL Id: hal-04407914**

<https://inria.hal.science/hal-04407914v1>

Submitted on 21 Jan 2024

**HAL** is a multi-disciplinary open access archive for the deposit and dissemination of scientific research documents, whether they are published or not. The documents may come from teaching and research institutions in France or abroad, or from public or private research centers.

L'archive ouverte pluridisciplinaire **HAL**, est destinée au dépôt et à la diffusion de documents scientifiques de niveau recherche, publiés ou non, émanant des établissements d'enseignement et de recherche français ou étrangers, des laboratoires publics ou privés.



Distributed under a Creative Commons Attribution 4.0 International License

# MACHINE LEARNING BASED GUIDED DIAGNOSIS OF PAROTID TUMOURS FROM MRI

Arnaud Quillent<sup>3</sup>, Samy Ammari<sup>1,2</sup>, Émilie Chouzenoux<sup>3</sup>, Víctor Elvira<sup>4</sup>, Nathalie Lassau<sup>1,2</sup>

<sup>1</sup>Biomaps, UMR1281 INSERM, CEA, CNRS, Université Paris-Saclay, 94805 Villejuif, France

<sup>2</sup>Department of Imaging, Gustave Roussy Cancer Campus, Université Paris Saclay, 94805 Villejuif, France

<sup>3</sup>Centre de Vision Numérique, OPIS, CentraleSupélec, Inria, Université Paris-Saclay, 91190 Gif-sur-Yvette, France

<sup>4</sup>School of Mathematics, University of Edinburgh, Edinburgh EH9 3FD, United Kingdom

Diagnosis of parotid gland tumours rely on magnetic resonance examination, fine-needle aspiration biopsy, or in some cases, invasive surgery that can damage facial nerves. In this work, we propose a machine learning model that can discriminate parotid tumours into histopathological subtypes from magnetic resonance imaging (MRI) scans, and further evaluate its impact on the diagnostic decisions of radiologists. We aim at improving the diagnosis of parotid neoplasms while avoiding any physical harm to patients. The radiologists improved their performance after observing the predictions of the algorithm. We conclude that machine-learning-based radiomics classification can assist radiologists.

## 1. DATA

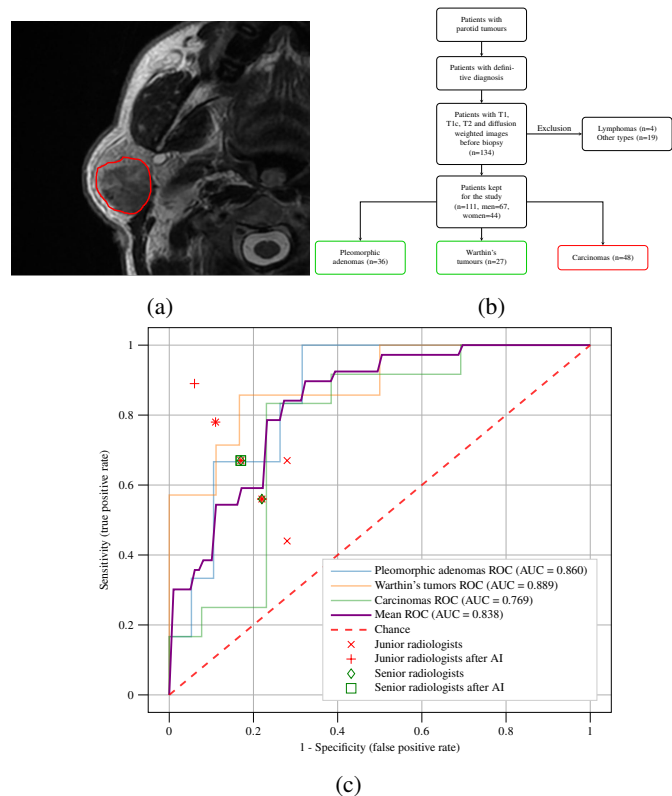
The cohort gathers patients that underwent an MRI examination for parotid tumours at Gustave Roussy Cancer Campus (France) between 2012 and 2021. All the patients subsequently underwent surgery, with histopathologic examination performed in the same center. The data includes four MRI sequences (T1w, T1ce, T2w, DWI) of 134 patients, along with histopathological subtypes categorized into pleomorphic adenomas (benign), Warthin's tumour (benign) and carcinomas (malignant) (see Fig. 1(b)).

## 2. METHODS

Parotid gland tumours were manually segmented using the software Olea Sphere on the four different MRI sequences (see Fig. 1(a)). Using the same software, 108 radiomic features were extracted from the MRI sequences. Harmonization steps at the image and feature levels compensate the high variability of the data. A feature selection step based on the F-test method sorts out variables that are independent of the target. The classification is performed through random forest algorithm, with a five-fold cross-validation, using an 80:20 ratio between training and test samples.

## 3. RESULTS

Radiologists and the proposed machine learning model were exposed to the MRI data to classify the tumors. The machine learning technique reached an accuracy of 0.720 and a mean AUC of 0.838 on test set when considering all classes (see Fig. 1(c)). Senior radiologists displayed worse performance compared to the juniors and to the algorithm. Finally, all radiologists were given the opportunity to change their decision by observing the algorithm prediction. Seniors improved their accuracy in a 5.6% and juniors in a 6.3%.



**Fig. 1:** (a) Segmentation of MRI image. (b) Dataset description. (c) One-Versus-All ROC curves of the algorithm predictions for each tumor class and performance metrics of the radiologists.