



**HAL**  
open science

## **Congenital abnormalities associated with microtia: A 10-YEARS retrospective study**

Antoine Paul, Sophie Achard, François Simon, Nicolas Garcelon, Erea Noel  
Garabedian, Vincent Couloigner, Charlotte Celerier, Françoise Denoyelle

► **To cite this version:**

Antoine Paul, Sophie Achard, François Simon, Nicolas Garcelon, Erea Noel Garabedian, et al.. Congenital abnormalities associated with microtia: A 10-YEARS retrospective study. International Journal of Pediatric Otorhinolaryngology, 2021, 146, pp.110764. 10.1016/j.ijporl.2021.110764 . hal-04360132

**HAL Id: hal-04360132**

**<https://inria.hal.science/hal-04360132>**

Submitted on 22 Jul 2024

**HAL** is a multi-disciplinary open access archive for the deposit and dissemination of scientific research documents, whether they are published or not. The documents may come from teaching and research institutions in France or abroad, or from public or private research centers.

L'archive ouverte pluridisciplinaire **HAL**, est destinée au dépôt et à la diffusion de documents scientifiques de niveau recherche, publiés ou non, émanant des établissements d'enseignement et de recherche français ou étrangers, des laboratoires publics ou privés.



Distributed under a Creative Commons Attribution 4.0 International License

# **CONGENITAL ABNORMALITIES ASSOCIATED WITH MICROTIA: A 10-YEARS RETROSPECTIVE STUDY**

**Authors :** Antoine Paul MD<sup>1</sup>, Sophie Achard MD<sup>1</sup>, François Simon MD<sup>1</sup>, Nicolas Garcelon MD<sup>2</sup>, Erea Noel Garabedian PhD<sup>1</sup>, Vincent Couloigner PhD<sup>1</sup>, Charlotte Celerier MD<sup>1</sup>, Françoise Denoyelle PhD<sup>1</sup>.

## **Affiliations**

**1.** Pediatric otolaryngology and head and neck surgery department, Necker Enfants-Malades Assistance Publique - Hôpitaux de Paris, Université de Paris, Paris, France

**2.** Plateforme data science - institut des maladies génétiques Imagine, Inserm, centre de recherche des Cordeliers, UMR 1138 équipe 22, institut Imagine, université Sorbonne-Paris Cité, Paris, France.

Corresponding author: Antoine Paul, pediatric otolaryngology and head and neck surgery department, Necker Enfants-Malades Assistance Publique - Hôpitaux de Paris, Paris, France.

Phone number 0033(0)171396784; e-mail: antoine.paul@wuzcap.fr

All authors disclosed any actual or potential conflicts of interest, including any financial, personal or other relationships with other people or organizations within that could have inappropriately influenced this work.

1 **Abstract**

2 **Objective:** Microtia is a congenital auricular malformation, often part of a syndromic form  
3 (35% to 55% of cases). The accurate prevalence of associated malformations remains to be  
4 determined with regard to the heterogeneous results of the previous studies. This study aims  
5 to describe in a large population cohort the abnormalities associated with microtia and to  
6 determine the most suitable assessment for these children.

7 **Methods:** This is a retrospective and observational cohort study collecting data from the  
8 medical records of children affected by microtia, diagnosed or followed-up between 2007 and  
9 2017. Data were collected via a computer database. Clinical data, as well as imaging or  
10 genetic results, were noted.

11 **Results:** Six hundred ninety four children were included, 587 (84.6%) with unilateral and 107  
12 (15.4%) with bilateral microtia. Inner ear malformations were observed in 14.1% of the ears.  
13 The main associated anomalies were hemifacial microsomia (29%), velopharyngeal  
14 insufficiency (9%), ophthalmologic (6.2%), vertebral (5.9%), cardiac (5.5%) and kidney (3%)  
15 abnormalities. Main identified entities were Goldenhar, Treacher-Collins and Guion-Almeida  
16 syndromes.

17 **Conclusion:** A comprehensive clinical assessment must be completed when microtia is  
18 diagnosed. Besides screening well-known oculo-auriculo-vertebral spectrum malformations,  
19 velopharyngeal insufficiency should be systematically sought. Specialized care must be  
20 provided to the very frequently associated hemifacial macrosomia. Mild forms of this last  
21 malformation may correspond to Guion-Almeida syndrome, especially in cases of learning  
22 disability.

23

24 **Key-words:** Microtia, malformations, genetic, children, syndrome.

## 25 **1. Introduction**

26 Microtia is defined as a congenital auricular malformation, ranging from a small-sized  
27 pinna to a complete absence of auricular structure called anotia[1]. This abnormality is  
28 usually associated with external ear canal and middle ear malformations. Microtia is a rare  
29 malformation with an incidence rate between one and three out of 10000 births[2], which may  
30 vary according to the ethnicity of the studied population as Hispanic and Asian populations  
31 are more frequently affected.

32 A significant part of cases are syndromic forms, for which prevalence rates range from  
33 35% to 55%[3]–[5]. The most often reported abnormalities are orofacial, vertebral,  
34 ophthalmologic, or kidney malformations, and some specific syndromes are often reported  
35 such as Goldenhar, Treacher-Collins, Branchio-oto-renal or Nager syndromes. The results of  
36 previous studies regarding the frequency of the malformations associated with microtia are  
37 heterogeneous which may be explained by various differences such as population size,  
38 demographic characteristics, or study methodology. Thus, it remains difficult to estimate the  
39 accurate prevalence of the various associated anomalies. In the past few decades, a greater  
40 amount of work has been done in the genetic etiology of microtia, which will probably lead to  
41 the classification of various forms of this disorder.

42 The aim of this work is to describe, in a large cohort on a ten years period, the rate of  
43 the abnormalities associated with microtia in order to help physicians in the assessment of this  
44 congenital malformation.

45

## 46 **2. Materials and methods**

47 This is a retrospective and observational cohort study. Data were collected from the  
48 medical records of affected children managed in the pediatric ENT department of Necker

49 Enfants-Malades children hospital in Paris, France. We included all children under 18 years of  
50 age with microtia-anotia diagnosed or followed-up between January 2007 and December 2017.  
51 A standard malformative assessment was performed during this period including cardiac and  
52 renal ultrasonography, vertebral and temporal bone imaging, and ophthalmologic examination.  
53 Data collection was performed via a computer database Dr Warehouse[6] gathering the  
54 pediatric ENT department documents as well as the results or records from the radiology,  
55 neonatology, or other specialized departments involved in the care of the affected children.  
56 The sample selection was done in Dr Warehouse by a keyword search: “microtia,” “anotia,”  
57 and “pinna malformation” were used. With this method, we were able to retrieve all patients  
58 with records mentioning these keywords. Then the medical records of each patient were  
59 studied to confirm their inclusion, and from the included records, all clinical data and results  
60 of complementary exams were noted. Two pediatric otolaryngologists were responsible for  
61 the cohort selection. After they agreed about which records to include, one of them collected  
62 the data, after which another ENT physician rechecked their accuracy, trying to improve their  
63 comprehensiveness and quality.

64 Clinical data included sex, affected side, family history, associated facial palsy,  
65 preauricular pit or tag, and other associated congenital abnormalities. Homolateral pits or tags  
66 were not noted because they are considered as part of the pinna malformation.

67 Results of additional exams were also registered: temporal bone imaging results  
68 (computed tomography and/or magnetic resonance imaging) searching for associated middle  
69 or inner ear malformations and genetic results. We registered the orofacial, ophthalmologic,  
70 cardiac, vertebral, renal, neurological anomalies as well as those of the digestive tract or limbs.  
71 Any non-isolated microtia was considered a syndromic microtia. Specific identified  
72 syndromes are noted when they were named in the medical records (ex: Goldenhar syndrome).

73

74 The relationship between qualitative variables were analyzed through Chi-square and  
75 Fisher's exact tests depending on the population size studied (more or less than 5 cases  
76 respectively).  $p < 0.05$  was considered statistically significant.

77

78 All children and parents were given oral and written comprehensive information about  
79 the study modalities, explaining that it is a retrospective study without any influence on their  
80 care, and that all data would be anonymously published. They were aware of the possibility  
81 that inclusion of their data could be canceled according to their will. This study was approved  
82 by the ethics committee CENEM (Comité d'Ethique de Necker-Enfants Malades, referring  
83 code: 2019-06-FD).

84

### 85 **3. Results**

86 Six hundred ninety four children were included. Sex-ratio was 1.4 (284 girls, 410  
87 boys). Cases of unilateral and bilateral microtia were registered in 587 (84.6%) and 107  
88 (15.4%) children, respectively. Ears were separately studied when analyzing the rates of  
89 middle and inner ear malformations associated with microtia on temporal bone imaging. Thus,  
90 data of 801 ears were analyzed. In 31/587 cases of unilateral microtia (5.3%), contralateral  
91 preauricular pits or tags were noted, (27 preauricular tag, 2 preauricular pit and 2 preauricular  
92 and cheek tag). Facial palsy was diagnosed in 44 children (6.3%): 38 unilateral microtia with  
93 homolateral Facial palsy(FP), 6 cases of bilateral microtia with unilateral or bilateral FP in 3  
94 cases for each. In this retrospective study, it was difficult to determine whether FP was  
95 congenital or acquired as it was not systematically specified in the medical records.

96 Temporal imaging results were available for 311 affected ears (261 children with 211  
97 unilateral and 50 bilateral microtia). Ossicular malformations were observed in all ears: in

98 281/311 ears (90.4%), ossicular dysplasia was diagnosed with all 3 ossicles identifiable,  
99 whereas ossicular agenesis was noted in 29/311 ears (9.3%) (table 1). Window dysplasia was  
100 visualized in 2.6%. Inner ear malformations were observed in 44/311 ears (14.1%), mainly  
101 isolated vestibular malformations (table 2a).

102 Inner ear malformations were statistically more frequently observed in children having  
103 associated anomalies ( $p < 10^{-6}$ ). No difference was observed between unilateral and bilateral  
104 cases (table 2b).

105 281 children were registered as having microtia associated with other abnormalities,  
106 the prevalence of which was as follows: hemifacial microsomia (HM) in 202/694 (29%,  
107 IC95%[25.8-32.6]), velopharyngeal insufficiency with and without cleft lip and/or palate in  
108 63/694 (9%, IC95%[7-11.5]), ophthalmologic in 43/694 (6.2%, IC95%[4.5-8.3]), vertebral in  
109 41/694 (5.9%, IC95%[4.3-7.9]), cardiac in 38/694 (5.5%, IC95%[3.9-7.4]), kidney in 21/694  
110 (3%, IC95%[1.9-4.6]), limbs in 19/694 (2.7%, IC95%[1.7-4.2]), digestive tract and neurologic  
111 abnormalities in 14/694 (2%, IC95%[1.1-3.4]) for both. Malformations are detailed in table 3.

112 Among those 281 syndromic cases of microtia, the main associations registered were  
113 isolated HM in 44.8% (n=126) or HM associated with other abnormalities in 27.8% (n=78).  
114 The main anomalies related to HM were velopharyngeal, palate or lip (VPL) defects in 6.5%  
115 (n=18), vertebral malformations in 4.3% (n=12) or ophthalmologic affection in 3.6% (n=10).  
116 When no hemifacial microsomia was noted, the most frequently abnormalities associated with  
117 microtia were VPL defects in 7.5% (n=21), ophthalmological anomalies in 3.6% (n=10),  
118 cardiac affection in 3.2% (n=9) or vertebral malformation in 1.8% (n=5). The main  
119 associations are summarized in the figure 1.

120 VPL, ophthalmologic, or vertebral anomalies were more frequently observed in  
121 children with hemifacial microsomia (table 4a). Ophthalmological, vertebral and kidney

122 anomalies were significantly associated with unilateral microtia, as compared to bilateral cases  
123 (table 4b).

124 The syndromic forms most frequently identified and reported in the medical records  
125 were Goldenhar, Treacher-Collins and Guion-Almeida syndromes. Goldenhar syndrome was  
126 noted in 45% of syndromic cases. The other entities are detailed in the table 5. Overall,  
127 genetic testing was performed in 147 children (21.2%). In 12 cases, a genetic abnormality was  
128 revealed: mutation in the *EFTUD2* gene (MIM: 610536) in four cases, terminal deletion on  
129 chromosome 18 in two children, 22q11 microdeletion (MIM:192430) in two cases, EDNRA  
130 gene (MIM: 616367) deletion in one case, and three cases of trisomy (one case for each  
131 trisomy 21 (MIM: 190685) and 22, and one unspecified trisomy reported in the medical  
132 records). Genetic findings are detailed in the appendices.

133

134

135

#### 136 **4. Discussion**

137 This study examines a remarkable population of patients who have been diagnosed  
138 with microtia over a period of 10 years. Collecting these data provides a clearer picture of the  
139 various forms of microtia that have been clinically assessed with current knowledge.  
140 Moreover, all the main malformations usually noted in this context were comprehensively  
141 analyzed.

142 Middle ear malformations are very frequent in microtia cases, and temporal bone  
143 imaging was systemically performed in children with hearing loss, which revealed ossicular  
144 abnormalities. Inner ear malformations were much less frequently noted than middle ear



145 anomalies, in accordance with the different embryological origin between both structures  
146 (branchial arches versus the otic capsule)[7][8]. The frequency of inner ear malformations  
147 noted in this study is similar to that of Mayer *et al* (13% versus 10.9% in our study)[9].  
148 Diagnosing inner ear malformations should lead to pneumococcal conjugate vaccination for  
149 the prevention of meningitis and to a vestibular assessment.

150 Thus, temporal bone imaging is mandatory in the assessment of microtia with hearing  
151 loss, keeping in mind that this type of imaging is most useful when the mastoid aeration is  
152 developed enough (from a mean age of 5 years-old, with a completely pneumatized mastoid at  
153 about 11 years-old). However, it remains useful at an earlier age in some cases: sensorineural  
154 hearing loss, otorrhea from a narrow canal, or fistulae located in the atretic ear, to search for  
155 an external ear cholesteatoma.

156 Hemifacial microsomia was the most frequently observed malformation in this study,  
157 29%, similar to previous work[5][10][11]. It represented in 45% of all syndromic cases. This  
158 malformation affects the mandibular bone in most cases, but the upper and midface must be  
159 assessed as well; Kheogh *et al.* reassessed 100 cases of microtia initially considered as  
160 isolated: 40% of them were associated with HM such as mandibular, orbital or malar  
161 hypoplasia[12]. We show here that most of multiple malformations cases presented with the  
162 oculo-auriculo-vertebral (OAV) spectrum anomalies which correspond to a large and  
163 heterogeneous range of manifestations mainly affecting aural, oral, and mandibular (or  
164 maxillary) developments. It includes the Goldenhar syndrome defined as the association of  
165 HM, ophthalmologic affection (mainly epibulbar cyst), and vertebral anomalies. This clinical  
166 spectrum is related to impaired development in the first and second branchial arches involving  
167 the neural crest cells migration[13].

168 Among craniofacial anomalies, we reported many cases of velopharyngeal  
169 insufficiency, mostly without obvious morphological anomaly. Indeed, they correspond to

170 muscular hypoplasia or hemiparesia of the soft palate or submucosal cleft leading to velar  
171 insufficiency. Westerflier *et al*, reported 96% of soft palate dysfunction, and velopharyngeal  
172 insufficiency was observed in 60% and 85% of unilateral and bilateral microtia,  
173 respectively[14]. Similarly, Kolodzynski *et al*. recently found velar palsy in 51/83 cases of  
174 microtia[15]. Thus, a systematic analysis of velar and palate contractility or morphology  
175 should be completed in all children with microtia.

176 Two other malformations were highly associated with microtia, being part of the so-  
177 called OAV spectrum: ophtalmologic abnormalities (mainly coloboma 26%, and epibulbar  
178 dermoid cyst 9%). Strabism prevalence was not different to the general population: 1.5-4%  
179 according to Schuster *et al*, and Torp-Pedersen *et al*)[16][17], and vertebral malformations  
180 (prevalence similar to those of Luquetti *et al* or Stoll *et al*)[18][19]). Among patients with  
181 vertebral anomalies, specific syndromic forms were identified in 15/42: 10 Goldenhar, 2  
182 Guion-Almeida, one CHARGE, one trisomy, and one Klippel-Feil syndrome.

183

184 Other malformations could be observed, but they didn't seem to be specifically linked  
185 to a well delineated syndrome. The most prevalent were as following:

186 - cardiopathy such as interventricular or interauricular defects, similar to the incidence in the  
187 general population.

188 - kidney disorders such as agenesis/hypoplasia, with one case of Goldenhar syndrome and one  
189 Fraser syndrome.

190 - limb malformations mainly corresponding to hypoplasia of the thumb or varus equinus of  
191 the foot: these affections were never the only malformation associated with a microtia case in  
192 our study

193 - digestive tract anomalies, less frequent, corresponding to esophageal atresia in a few cases.

194

195           Among neurologic anomalies, microcephaly was the most frequent. Three out of six  
196 cases of microcephaly corresponded to Guion-Almeida syndrome. Screening for mutations of  
197 the *EFTUD2* gene[20] related to Guion-Almeida syndrome, seems interesting in cases of  
198 microtia associated with microcephaly, especially when hemifacial microsomia is associated.

199           The high prevalence of microcephaly in the Hungarian study of Paput *et al* may  
200 question whether some cases of Guion-Almeida syndrome are part of them[21]. Microcephaly  
201 is one of the main differences between Guion Almeida and Treacher Collins syndromes (TC),  
202 both having many similarities such as malar hypoplasia and microtia[22]. The facial  
203 characteristics are nevertheless different on several points: in Guion Almeida syndrome,  
204 auricular malformations correspond mostly to large squared pinna, while TC cases present  
205 with auricular atresia or anotia. Downward-slanting palpebral fissures are specific to TC  
206 syndrome while Guion Almeida cases present with upward-slanting palpebral fissures.  
207 Developmental delay is very often reported in Guion-Almeida syndrome and it was noted in  
208 all of our cases. The *EFTUD2* gene may be implicated in children without microcephaly:  
209 physicians and geneticists must be aware of this when children present with a severe delay in  
210 speech, discordant with their hearing level. Guion Almeida syndrome is probably frequently  
211 underdiagnosed.

212           As a retrospective study, many limitations were expected such as incomplete data.  
213 Indeed, several imaging reports were unavailable, and some malformations could have been  
214 missed, either because of an incomplete assessment at the time of diagnosis, or because the  
215 information had not been noted in computerized medical records.

216           On the other hand, the study is difficult to compare to those of previous authors.  
217 Indeed, there were many differences between the studies' design:

218 - the population size, varying from 120 (Forrestier *et al*, 2005) to more than 818 cases  
219 (Luquetti *et al*, 2013)[18][23].

220 - the range of years considered by the study, varying from 2 to 42 years (Wu *et al* 2010,  
221 Luquetti *et al* 2013)[5][18].

222 - the inclusion criteria, leading to different population characteristics. For example, Luquetti  
223 *et al.* included stillborn infants which led to higher prevalence of severe malformations[18]. In  
224 Suutarla and Paput's studies, only syndromic forms without identified diagnoses were  
225 presented[10][21]. Our study was done in a French referring pediatric department and  
226 included all microtia forms.

227 - the comprehensiveness of the results: it was surprising to observe that no hemifacial  
228 microsomia was noted in Forrester and Stoll's studies[19][23]. Velopharyngeal insufficiency  
229 is rarely reported, this disorder is probably underestimated as its evaluation is difficult in  
230 young children. Moreover, details are lacking in many studies: cardiac or vertebral  
231 malformations are not always specified in previous work.

232 - the data analysis period. It is indeed difficult to compare results of the last few years with the  
233 earlier works as genetic knowledge has significantly improved as well as the corresponding  
234 phenotype description, mainly due to the recent development of "next generation sequencing."  
235 Guion Almeida syndrome and the *EFTUD2* gene have been well delineated since Line's and  
236 Gordon's works[20][24]. This syndrome has been probably underdiagnosed so far.

237

## 238 **5. Conclusion**

239 In conclusion, microtia is a rare malformation, the diagnosis of which must lead to a  
240 comprehensive clinical assessment. Beyond the well-known OAV spectrum malformations,  
241 some specific anomalies must be systematically considered due to their prevalence in this

242 population, such as hemifacial microsomia, velopharyngeal insufficiency, or milestone  
243 development. The associated malformations may not be obvious. Thus, besides the  
244 audiological and aesthetic considerations, it is essential for the associated anomalies to be  
245 screened by pediatricians and otolaryngologists who are at the forefront of these children's  
246 assessment.

247

248

249 **This research did not receive any specific grant from funding agencies in the public,**  
250 **commercial, or not-for-profit sectors.**

251

252

253

254

255

256

257

258

259

260

261

262

263

264

265

266

267

268

270 **References**

271

- 272 [1] Y. Meurman, "Congenital microtia and meatal atresia; observations and aspects of  
273 treatment," *AMA Arch. Otolaryngol.*, vol. 66, no. 4, pp. 443–463, Oct. 1957.
- 274 [2] A. T. Hoyt *et al.*, "Sociodemographic and hispanic acculturation factors and isolated  
275 anotia/microtia," *Birt. Defects Res. A. Clin. Mol. Teratol.*, vol. 100, no. 11, pp. 852–862,  
276 Nov. 2014, doi: 10.1002/bdra.23282.
- 277 [3] M. A. Canfield, P. H. Langlois, L. M. Nguyen, and A. E. Scheuerle, "Epidemiologic  
278 features and clinical subgroups of anotia/microtia in Texas," *Birt. Defects Res. A. Clin.  
279 Mol. Teratol.*, vol. 85, no. 11, pp. 905–913, Nov. 2009, doi: 10.1002/bdra.20626.
- 280 [4] P. Mastroiacovo, C. Corchia, L. D. Botto, R. Lanni, G. Zampino, and D. Fusco,  
281 "Epidemiology and genetics of microtia-anotia: a registry based study on over one  
282 million births," *J. Med. Genet.*, vol. 32, no. 6, pp. 453–457, Jun. 1995.
- 283 [5] J. Wu, R. Zhang, Q. Zhang, Z. Xu, W. Chen, and D. Li, "Epidemiological analysis of  
284 microtia: a retrospective study in 345 patients in China," *Int. J. Pediatr.  
285 Otorhinolaryngol.*, vol. 74, no. 3, pp. 275–278, Mar. 2010, doi:  
286 10.1016/j.ijporl.2009.12.001.
- 287 [6] N. Garcelon *et al.*, "A clinician friendly data warehouse oriented toward narrative  
288 reports: Dr. Warehouse," *J. Biomed. Inform.*, vol. 80, pp. 52–63, 2018, doi:  
289 10.1016/j.jbi.2018.02.019.
- 290 [7] M. Ozeki-Satoh, A. Ishikawa, S. Yamada, C. Uwabe, and T. Takakuwa, "Morphogenesis  
291 of the middle ear ossicles and spatial relationships with the external and inner ears  
292 during the embryonic period," *Anat. Rec. Hoboken NJ 2007*, vol. 299, no. 10, pp. 1325–  
293 1337, 2016, doi: 10.1002/ar.23457.
- 294 [8] H. Thompson, A. Ohazama, P. T. Sharpe, and A. S. Tucker, "The origin of the stapes  
295 and relationship to the otic capsule and oval window," *Dev. Dyn. Off. Publ. Am. Assoc.  
296 Anat.*, vol. 241, no. 9, pp. 1396–1404, Sep. 2012, doi: 10.1002/dvdy.23831.
- 297 [9] T. E. Mayer, H. Brueckmann, R. Siegert, A. Witt, and H. Weerda, "High-resolution CT  
298 of the temporal bone in dysplasia of the auricle and external auditory canal," *AJNR Am.  
299 J. Neuroradiol.*, vol. 18, no. 1, pp. 53–65, Jan. 1997.
- 300 [10] S. Suutarla, J. Rautio, A. Ritvanen, S. Ala-Mello, J. Jero, and T. Klockars, "Microtia in  
301 Finland: comparison of characteristics in different populations," *Int. J. Pediatr.  
302 Otorhinolaryngol.*, vol. 71, no. 8, pp. 1211–1217, Aug. 2007, doi:  
303 10.1016/j.ijporl.2007.04.020.
- 304 [11] D. P. F. van Nunen, M. N. Kolodzynski, M.-J. H. van den Boogaard, M. Kon, and C. C.  
305 Breugem, "Microtia in the Netherlands: clinical characteristics and associated anomalies,"  
306 *Int. J. Pediatr. Otorhinolaryngol.*, vol. 78, no. 6, pp. 954–959, Jun. 2014, doi:  
307 10.1016/j.ijporl.2014.03.024.
- 308 [12] I. J. Keogh, M. J. Troulis, A. A. Monroy, R. D. Eavey, and L. B. Kaban, "Isolated  
309 microtia as a marker for unsuspected hemifacial microsomia," *Arch. Otolaryngol. Head  
310 Neck Surg.*, vol. 133, no. 10, pp. 997–1001, Oct. 2007, doi: 10.1001/archotol.133.10.997.
- 311 [13] C. Tasse *et al.*, "Oculo-auriculo-vertebral spectrum (OAVS): clinical evaluation and  
312 severity scoring of 53 patients and proposal for a new classification," *Eur. J. Med.  
313 Genet.*, vol. 48, no. 4, pp. 397–411, Dec. 2005, doi: 10.1016/j.ejmg.2005.04.015.
- 314 [14] C. van Hövell Tot Westerfliet, I. C. Bracamontes, Y. Tahiri, C. Breugem, and J.  
315 Reinisch, "Soft Palate Dysfunction in Children With Microtia," *J. Craniofac. Surg.*, vol.  
316 30, no. 1, pp. 188–192, Jan. 2019, doi: 10.1097/SCS.0000000000004907.

- 317 [15] M. N. Kolodzynski, B. T. van Hoorn, M. Kon, and C. C. Breugem, "Abnormal soft  
318 palate movements in patients with microtia," *J. Plast. Reconstr. Aesthetic Surg. JPRAS*,  
319 vol. 71, no. 10, pp. 1476–1480, 2018, doi: 10.1016/j.bjps.2018.06.004.
- 320 [16] A. K. Schuster, H. M. Elflein, R. Pokora, and M. S. Urschitz, "[Childhood strabismus in  
321 Germany: Prevalence and risk groups : Results of the KiGGS survey],"  
322 *Bundesgesundheitsblatt Gesundheitsforschung Gesundheitsschutz*, vol. 60, no. 8, pp.  
323 849–855, Aug. 2017, doi: 10.1007/s00103-017-2578-x.
- 324 [17] T. Torp-Pedersen *et al.*, "Strabismus Incidence in a Danish Population-Based Cohort of  
325 Children," *JAMA Ophthalmol.*, vol. 135, no. 10, pp. 1047–1053, Oct. 2017, doi:  
326 10.1001/jamaophthalmol.2017.3158.
- 327 [18] D. V. Luquetti, T. C. Cox, J. Lopez-Camelo, M. da G. Dutra, M. L. Cunningham, and E.  
328 E. Castilla, "Preferential associated anomalies in 818 cases of microtia in South  
329 America," *Am. J. Med. Genet. A.*, vol. 161A, no. 5, pp. 1051–1057, May 2013, doi:  
330 10.1002/ajmg.a.35888.
- 331 [19] C. Stoll, Y. Alembik, B. Dott, and M.-P. Roth, "Associated anomalies in cases with  
332 anotia and microtia," *Eur. J. Med. Genet.*, vol. 59, no. 12, pp. 607–614, Dec. 2016, doi:  
333 10.1016/j.ejmg.2016.10.012.
- 334 [20] M. A. Lines *et al.*, "Haploinsufficiency of a spliceosomal GTPase encoded by EFTUD2  
335 causes mandibulofacial dysostosis with microcephaly," *Am. J. Hum. Genet.*, vol. 90, no.  
336 2, pp. 369–377, Feb. 2012, doi: 10.1016/j.ajhg.2011.12.023.
- 337 [21] L. Paput, F. Bánhidly, and A. E. Czeizel, "Distribution of associated component  
338 abnormalities in cases with unclassified multiple ('syndromic') anota/microtia," *Int. J.*  
339 *Pediatr. Otorhinolaryngol.*, vol. 75, no. 5, pp. 639–647, May 2011, doi:  
340 10.1016/j.ijporl.2011.01.041.
- 341 [22] M. Vincent *et al.*, "Treacher Collins syndrome: a clinical and molecular study based on a  
342 large series of patients," *Genet. Med. Off. J. Am. Coll. Med. Genet.*, vol. 18, no. 1, pp.  
343 49–56, Jan. 2016, doi: 10.1038/gim.2015.29.
- 344 [23] M. B. Forrester and R. D. Merz, "Descriptive epidemiology of anotia and microtia,  
345 Hawaii, 1986-2002," *Congenit. Anom.*, vol. 45, no. 4, pp. 119–124, Dec. 2005, doi:  
346 10.1111/j.1741-4520.2005.00080.x.
- 347 [24] C. T. Gordon *et al.*, "EFTUD2 haploinsufficiency leads to syndromic oesophageal  
348 atresia," *J. Med. Genet.*, vol. 49, no. 12, pp. 737–746, Dec. 2012, doi:  
349 10.1136/jmedgenet-2012-101173.
- 350
- 351
- 352
- 353
- 354
- 355
- 356

357

358

359 **Appendices**

360 *EFTUD2* mutations (NM\_004247) : - c.1860 G>C, p.Lys629Asn

361 - c.1854del p.Thr619Profs\*10

362 - c.1034del, p.Gly345ValfsX41

363 - c.2562-2\_2562-1del

364 18q22 deletions : - 46,XY del 18(q22.3qter)

365 - 46,XX,del(18)(q22.2).ish del(18)(qter)

366 *EDNRA* mutation (NM\_045958) : c.386A>T, p.Tyr129Phe

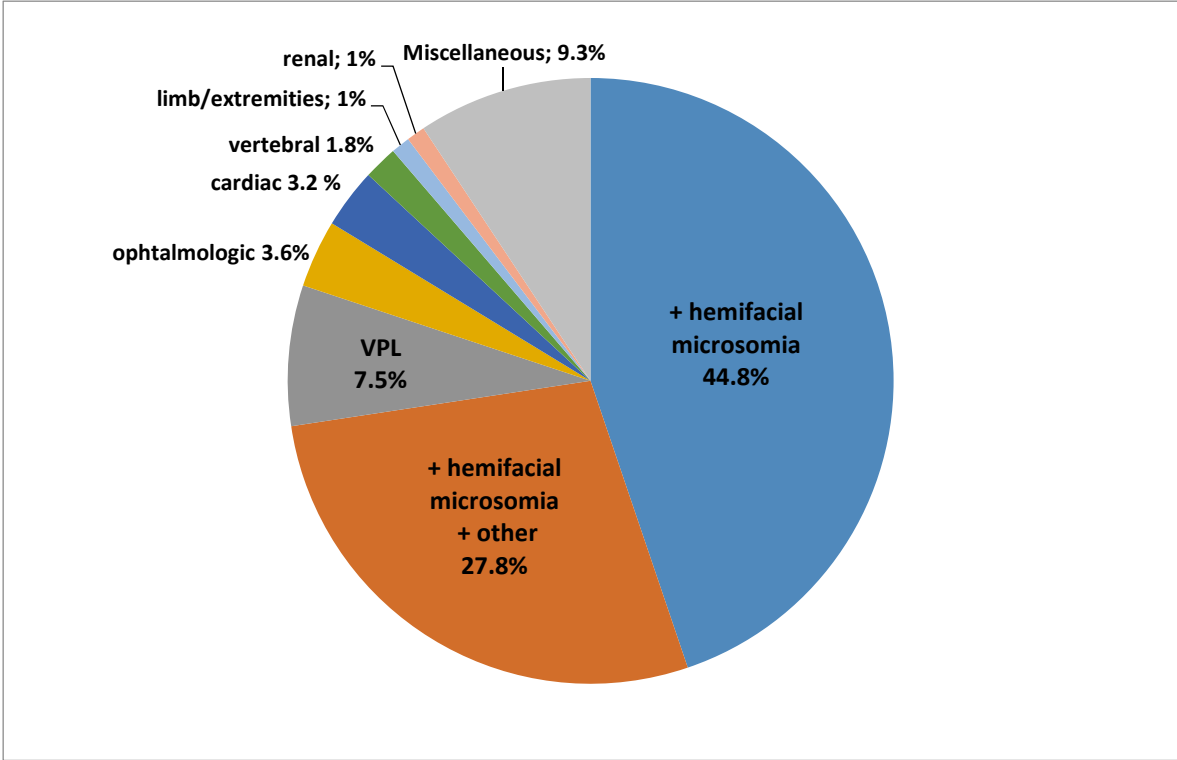
367

368

369

370





**Figure 1: Main associations among syndromic cases of microtia**

VPL: velopharyngeal/palate/lip abnormality

Miscellaneous: isolated cases of complex associations without hemifacial microsomia.

<b>Middle ear malformations</b>	<b>n (%)</b>
<b>Ossicular dysplasia - all ossicles identifiable</b>	<b>282 (90.7)</b>
including : OW agenesis	4
RW agenesis	1
<b>Ossicular agenesis</b>	<b>29 (9.3)</b>
Stapes / with OW dysplasia	10 / 2
Complete agenesis / with OW dysplasia	8 / 1
Malleus	4
Incus	3
Malleus and Incus	1

**Table 1: middle ear malformations associated with microtia.**

OW: oval window, RW: round window.

<b>Inner ear malformations</b>	<b>n (%)</b>
<b>Vestibula</b>	<b>28 (9)</b>
Lateral SCC	15
Posterior SCC	5
Multiple SCC malformations	2
Vestibular dilatation	4
SCC + vestibule	2
<b>Cochlea</b>	<b>4 (1.3)</b>
Hypoplasia	1
Canal stenosis	1
Dysplasia	2
<b>CV malformations</b>	<b>6 (1.9)</b>
Cochlea + SCC dysplasia	2
Cochlea + SCC dysplasia + EVA	1
Unique vesicle	2
Cochlea canal stenosis + lateral SCC dysplasia	1
<b>Other</b>	<b>6 (1.9)</b>
SCC dyplasia + IAC dilatation	1
Cochlea and lateral SCC dysplasia + EVA	1
Cochlear nerve agenesis	1
CV malformation + CV nerve agenesis	1
Unique vesicle + cochlear nerve hypoplasia	1
Unknown	1
<b>No Inner ear malformations</b>	<b>267 (85.9)</b>
<b>TOTAL</b>	<b>311</b>

**Table 2a: inner ear malformations associated with microtia.**

SCC: semicircular canal, IAC: internal auditory canal, EVA: enlarged vestibular aqueduct.

	<b>Inner ear malformation (n)</b>
Unilateral microtia (n=587)	22
Bilateral microtia (n=107)	6
p-value	0.368
Syndromic microtia (n=281)	24
Isolated microtia (n=413)	4
p-value	<b>1.07 x 10<sup>-7</sup></b>

**Table 2b: comparison of inner ear malformation rates between unilateral/bilateral groups, and between children with isolated or syndromic microtia.**

Chi2 and Exact Fisher's tests

	n (%)
<b>Hemifacial microsomia</b>	<b>202 (29)</b>
<b>Velopharyngeal, palate/lip abnormalities</b>	<b>63 (9)</b>
Velopharyngeal insufficiency - no cleft	36
Cleft palate	17
Bifida uvula	7
Cleft lip and palate	3
<b>Ophthalmologic abnormalities</b>	<b>43 (6.2)</b>
Coloboma	11
Strabism	9
Oculomotor palsy	4
Dermoid cyst	4
Ptosis	3
Hypertelorism	2
Miscellaneous	10
<b>Vertebral abnormalities</b>	<b>42 (6)</b>
Hemivertebra	13
Vertebral fusion	11
Scoliosis	5
Torticolis + cervical malformation	2
Narrowed cervico-occipital hinge	2
Miscellaneous	5
Unspecified	4
<b>Cardiac abnormalities</b>	<b>38 (5.5)</b>
Interventricular defect (4 with valvular insufficiency, one with left ventricular hypoplasia)	19
Interauricular defect (one of which with valvular insufficiency)	5
Interventricular + interauricular defect	3
Fallot tetralogy	2
Patent foramen ovale	2
Miscellaneous	5
Unspecified	2
<b>Kidney abnormalities</b>	<b>21 (3)</b>
Kidney hypoplasia/agenesia	6
Kidney ectopia	4
Hydronephrosis	5
Horseshoe kidneys	3
Miscellaneous	3
<b>Limbs abnormalities</b>	<b>19 (2.7)</b>
Superior limbs (4 thumb malformations, 2 clinodactyly , 2 miscellaneous)	8
Inferior limbs (6 varus foot, 3 asymetry, 4 miscellaneous)	11
<b>Neurologic abnormalities</b>	<b>13 (1.9)</b>
Microcephaly	6
Plagiocephaly	3
Miscellaneous	4
<b>Digestive tract abnormalities</b>	<b>13 (1.9)</b>
Oesophageal atresia	5
Anorectal malformation	4

---

**Table 3: Malformations associated with microtia.**

Unspecified: malformation not detailed in the reports. Miscellaneous : malformations observed in isolated cases.

	Hemifacial microsomia (n=202)	No hemifacial microsomia (n=492)	p-value
VLP	36	26	< 10 <sup>-6</sup>
Ophthalmologic	23	22	<b>0.001</b>
Vertebral	25	13	< 10 <sup>-6</sup>
Cardiac	15	22	0.127
Kidney	7	14	0.69
Digestive tract	9	4	<b>0.004</b>
Neurological	9	7	<b>0.017</b>

**Table 4a: comparison of the malformations between children with and without hemifacial microsomia.**

Chi2 and Exact Fisher's tests

VLP : velopalatal and/or lip defect

	Unilateral microtia (n=587)	Bilateral microtia (n=107)	p-value
HM	170	35	0.43
VLP	43	19	<b>0.0005</b>
Ophthalmologic	23	22	< 10 <sup>-9</sup>
Vertebral	30	8	0.32
Kidney	14	7	<b>0.02</b>
Limb	13	6	<b>0.04</b>
Cardiac	26	11	<b>0.013</b>
Digestive tract	9	4	0.137
Neurological	6	10	< 10 <sup>-6</sup>

**Table 4b: comparison of the malformations between children with unilateral and bilateral microtia.**

Chi2 and Exact Fisher's tests

HM: hemifacial macrosomia, VLP : velopalatal and/or lip defect

	n (%)
<b>Syndromes reported in the medical records</b>	<b>86</b>
Goldenhar	40 (45)
Treacher Collins	26 (29)
Guion-Almeida	4 (5)
Pierre Robin sequence	3 (3)
Branchio-oto-renal	3 (3)
CHARGE	2 (2)
Najer	2 (2)
Wildervanck	1 (1)
Klippel Feil	1 (1)
Pfeiffer	1 (1)
VACTERL	1 (1)
Crouzon craniostenosis	1 (1)
Frazer	1 (1)
<b>Molecular diagnosis</b>	
<i>EFTUD2</i> mutations	4 (2.7)
18q22 deletions	2 (1.4)
22q11 microdeletions	2 (1.4)
<i>EDNRA</i> mutations	1 (0.7)
Trisomy 22	1 (0.7)
Trisomy 21	1 (0.7)
Unspecified trisomy	1 (0.7)

**Table 5: genetic findings in patients referred to genetic department.**

Mutations are detailed in the appendices.