



**HAL**  
open science

## **EmboASSIST a new software to help endovascular treatment of brain AVMs**

R Anxionnat, Y Djebiret, Erwan Kerrien, Marie-Odile Berger, I Cartier, S Amelot, Y Trouset, S Bracard

### ► **To cite this version:**

R Anxionnat, Y Djebiret, Erwan Kerrien, Marie-Odile Berger, I Cartier, et al.. EmboASSIST a new software to help endovascular treatment of brain AVMs. ABC-WIN Seminar 2022, Apr 2022, Val d'Isère, France. hal-03897635

**HAL Id: hal-03897635**

**<https://inria.hal.science/hal-03897635>**

Submitted on 14 Dec 2022

**HAL** is a multi-disciplinary open access archive for the deposit and dissemination of scientific research documents, whether they are published or not. The documents may come from teaching and research institutions in France or abroad, or from public or private research centers.

L'archive ouverte pluridisciplinaire **HAL**, est destinée au dépôt et à la diffusion de documents scientifiques de niveau recherche, publiés ou non, émanant des établissements d'enseignement et de recherche français ou étrangers, des laboratoires publics ou privés.



Distributed under a Creative Commons Attribution 4.0 International License

## **EmboASSIST a new software to help endovascular treatment of brain AVMs**

R. Anxionnat <sup>1,2</sup>, Y Djebiret <sup>3,4</sup>, E Kerrien <sup>3</sup>, MO Berger <sup>3</sup>, I Cartier <sup>4</sup>, S Amelot <sup>4</sup>, Y Troussel <sup>4</sup>, S Bracard <sup>1,2</sup>

<sup>1</sup> Department of diagnostic and interventional neuroradiology. University Hospital. Nancy. France

<sup>2</sup> IADI Inserm U1254. Université de Lorraine. France

<sup>3</sup> INRIA Nancy-Grand Est & LORIA. France

<sup>4</sup> GE Healthcare

*Introduction:* EmboASSIST (GE Healthcare) is a new 3D visualization software dedicated to assist AVM embolization. It provides a one-click 3D segmentation of vascular anatomy from CBCT acquisition then dynamically track feeders and simulate virtual injections. These segmented feeders can be displayed on live fluoroscopy facilitating micro catheter navigation. Moreover, 3D MR acquisition may be automatically registered with CBCT acquisition and also displayed on live fluoroscopy.

*Aim of the study:* presentation and preliminary evaluation of Emboassist

*Population and method:* This software was evaluated in the endovascular treatment of 10 brain AVM in 10 patients between March and May 2021. There were 5 males, 5 females whose age varied from 13 to 64 yo (mean 38 yo). Six AVMs had bled previously. Location was supra-tentorial in 8 (3 in frontal lobe, 4 in parietal lobe and 1 in temporal lobe), and infra-tentorial in 2 (one mesencephalic and one cerebellar). Three AVMS were Spetzler Martin grade 1, three were grade 2 and four were grade 3. The evaluation was prospectively done using a short survey completed at the end of each treatment by 2 operators (SB, RA) using a 5 points Likert scale. This survey deals with the ease of use of Emboassist and the help provided 1st at the planning stage in understanding the angioarchitecture of the AVM especially the number of afferent pedicles and their course; and 2<sup>nd</sup> during the treatment itself by facilitating endovascular navigation, reducing needs of contrast media, radiation and procedure time

*Results:* EmboASSIST was considered to be quick and easy of use in all the cases. It helps to define feeding arteries, their number and their course in 8/10 AVMs. Used for micro catheter navigation on live fluoroscopy in 8 cases, Emboassist helped to visualize the path and to navigate in 5 cases. As a consequence, Emboassist was believed to reduce contrast media, radiation and procedure time and to increase safety of these five treatment.

*Conclusion:* EmboASSIST is easy to use and gives a quick and clear understanding of the afferent pedicles to the AVM. It helps to visualize their course and, by displaying them on live fluoroscopy, may facilitate microcatheter navigation.

*Illustrative cases:*

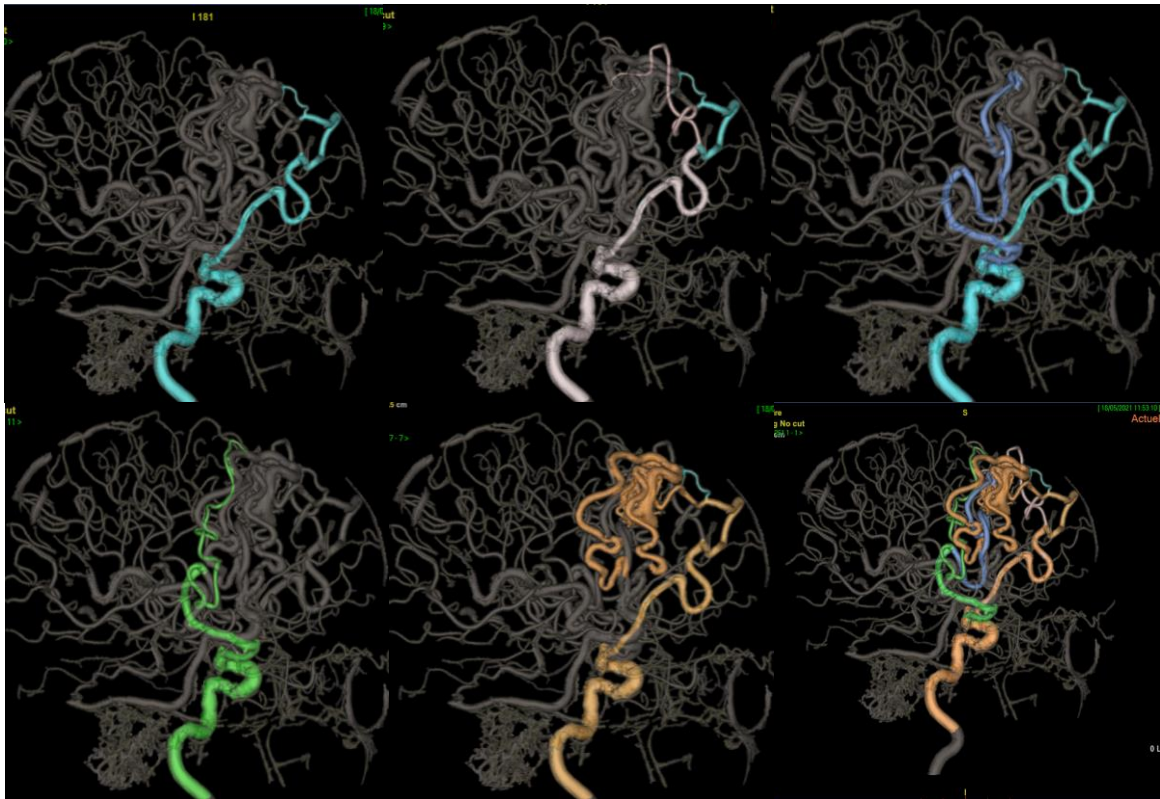


Fig 1: Right frontal AVM. Different step of segmentation of arterial feeders

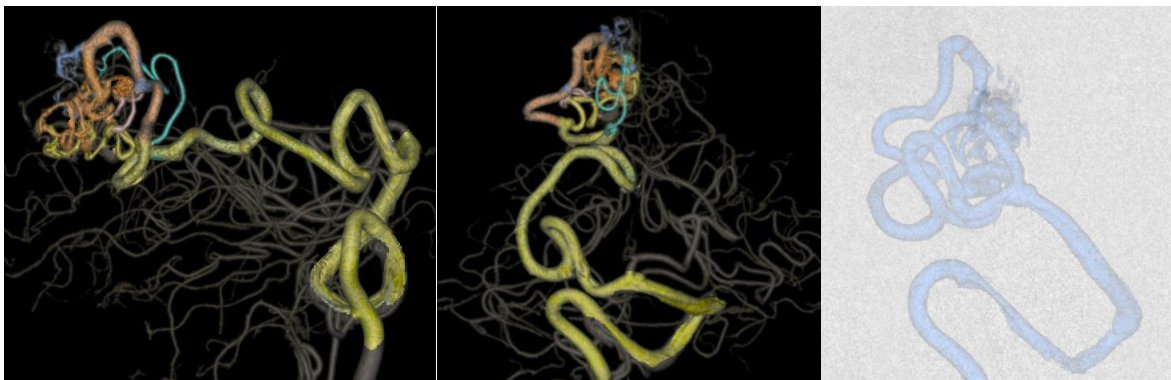


Fig 2: Right Parietal AVM. Analysis of arterial feeder with Emboassister. Microcatheter navigation and selective injection under fluoroscopy in an oblique view with segmented feeder displayed on screen.

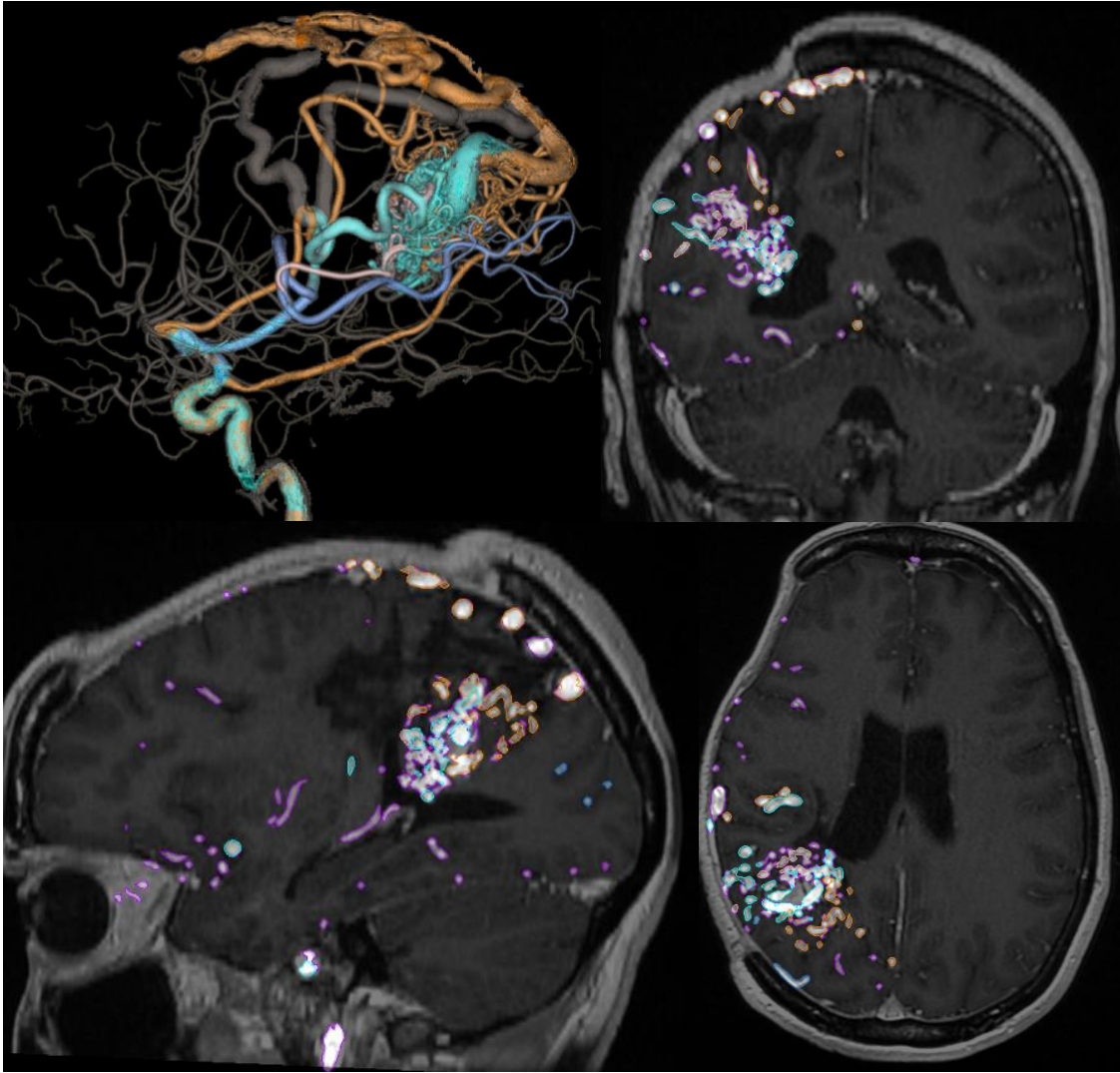


Figure 3 : Right parietal AVM. Registration with 3D T1 MRI