



HAL
open science

Neuroimaging in Machine Learning for Brain Disorders

Ninon Burgos

► **To cite this version:**

Ninon Burgos. Neuroimaging in Machine Learning for Brain Disorders. Olivier Colliot. Machine Learning for Brain Disorders, Springer, In press. hal-03814787

HAL Id: hal-03814787

<https://inria.hal.science/hal-03814787>

Submitted on 14 Oct 2022

HAL is a multi-disciplinary open access archive for the deposit and dissemination of scientific research documents, whether they are published or not. The documents may come from teaching and research institutions in France or abroad, or from public or private research centers.

L'archive ouverte pluridisciplinaire **HAL**, est destinée au dépôt et à la diffusion de documents scientifiques de niveau recherche, publiés ou non, émanant des établissements d'enseignement et de recherche français ou étrangers, des laboratoires publics ou privés.

Chapter 8

Neuroimaging in Machine Learning for Brain Disorders

Ninon Burgos^{*,1}

¹Sorbonne Université, Institut du Cerveau – Paris Brain Institute - ICM, CNRS, Inria, Inserm, AP-HP, Hôpital de la Pitié-Salpêtrière, F-75013, Paris, France

*Corresponding author: e-mail address: ninon.burgos@cnrs.fr

Abstract

Medical imaging plays an important role in the detection, diagnosis and treatment monitoring of brain disorders. Neuroimaging includes different modalities such as magnetic resonance imaging (MRI), X-ray computed tomography (CT), positron emission tomography (PET) or single-photon emission computed tomography (SPECT).

For each of these modalities, we will explain the basic principles of the technology, describe the type of information the images can provide, list the key processing steps necessary to extract features and provide examples of their use in machine learning studies for brain disorders.

Keywords: Magnetic resonance imaging, Computed tomography, Positron emission tomography, Single-photon emission computed tomography, Neuroimaging, Medical imaging, Machine learning, Deep learning, Feature extraction, Preprocessing

1. Introduction

Medical imaging plays a key role in brain disorders. In clinical care, it is vital for detection, diagnosis and treatment monitoring. It is also an essential tool for research to characterise the anatomical, functional and molecular alterations in brain disorders, to better understand the pathophysiology, or to evaluate the effects of new treatments in clinical trials for instance. Medical imaging of the brain is referred to as neuroimaging and involves different modalities such as X-ray computed tomography (CT), magnetic resonance imaging (MRI), positron emission tomography (PET) or single-photon emission computed tomography (SPECT).

Most neuroimaging modalities have been developed in the 1970s (Figure 1). The first CT image of a brain was acquired in 1971 [1, 2]. This technology results from the discovery of X-rays by Wilhelm Röntgen in 1895 [3]. A few years later, PET [4] and then SPECT [5, 6] cameras were developed. Both modalities result from the discovery of natural radioactivity in 1896 by Henri Becquerel [7]. The first MR image of a brain goes back to 1978 [8] following the discovery of nuclear magnetic resonance in 1946 by Felix Bloch [9]. Some of these imaging modalities were later combined into hybrid scanners. The first prototype combining PET and CT was introduced into the clinical arena in 1998 [10] while the first PET and MR images of a brain simultaneously acquired were reported in 2007 [11, 12]. The first commercial SPECT/CT system dates back to 1999 [13] while SPECT/MR systems are still under development [14].

CT and MRI are the modalities of choice when studying brain anatomy while SPECT and PET are used to image particular biological processes. Note that MRI is a versatile modality that allows studying both the structure and function of the brain, through the acquisition of different sequences. The use of these imaging modalities differs between clinical practice and research contexts. For example, CT is the main modality used in hospitals on adults [15] while MRI is by far the modality the most used for the study of brain disorders with machine learning (Figure 2, top). The two most studied disorders with machine learning are brain tumours and dementia, mainly Alzheimer’s disease (Figure 2, bottom).

This chapter will start by shortly describing the nature of neuroimages, detailing the type of features that can be extracted from them and listing software tools that can be used to do so. We will then briefly describe the principles of the imaging modalities the most used in machine learning studies: anatomical, diffusion and functional MRI, CT, PET and SPECT. For each modality, we will report the processing steps often perform to extract features, explain the type of information provided and give examples of their use in machine learning studies.

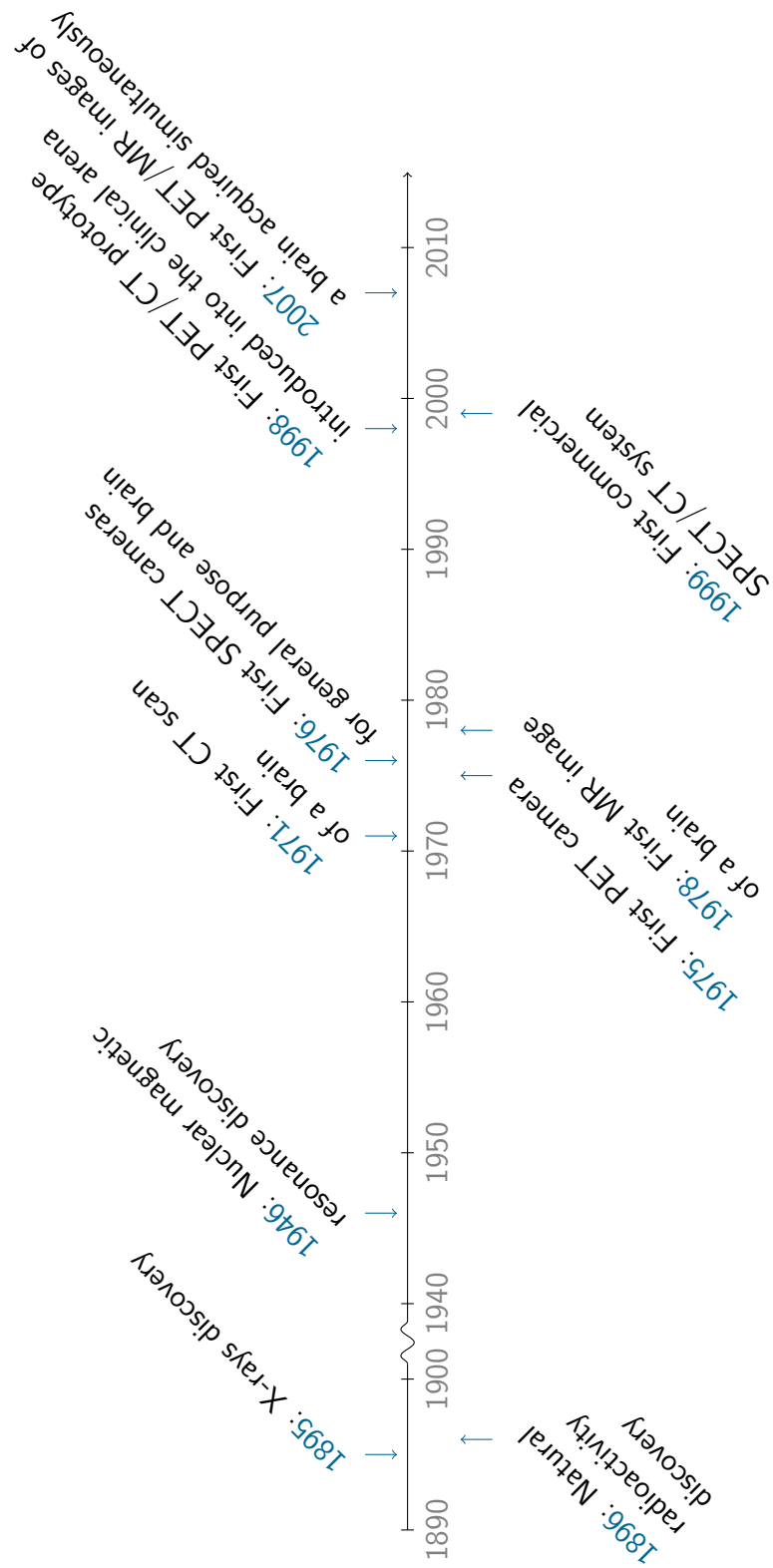


Figure 1: *Timeline of the main developments in neuroimaging*

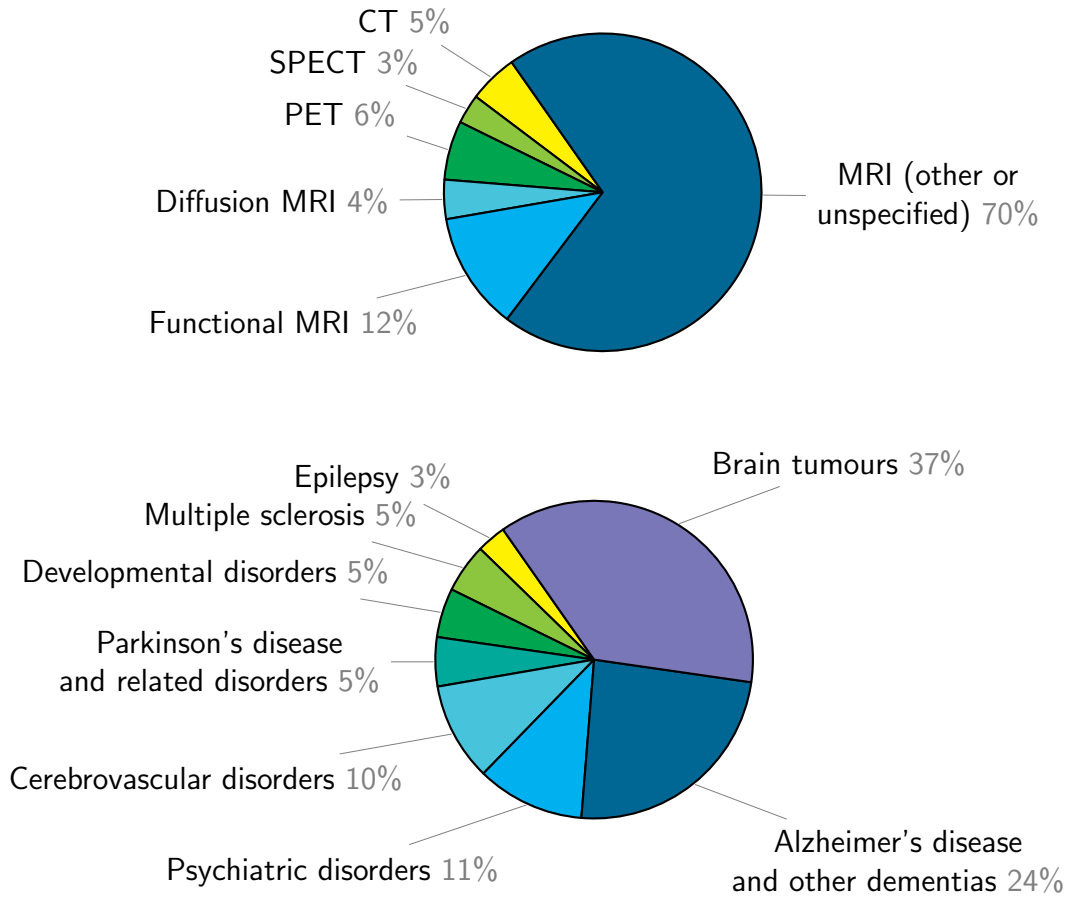


Figure 2: Distribution by imaging modality (top) and brain disorder (bottom) of 1327 articles presenting a study using machine learning. Note that these numbers should only be taken as rough indicators as they result from a non-exhaustive literature search. The Scopus query and the resulting articles (after some manual filtering) are available as a public Zotero library (https://www.zotero.org/groups/4623150/neuroimaging_with_ml_for_brain_disorders/library).

2. Manipulating neuroimages

In clinical routine, neuroimages are primarily exploited through visual inspection by a radiologist (or a neuroradiologist, who is a radiologist with an additional specialisation in brain imaging, in expert hospitals) or a nuclear medicine physician. This results in a radiological report that is a written text describing the characteristics of the brain of the patient, its alterations and possibly the most likely diagnosis. Note that neuroimaging exploration is usually requested by a neurologist or a psychiatrist, and is associated with an indication that may correspond to

the exploration of a set of symptoms (for instance the exploration of a dementia syndrome) or to the confirmation of a potential diagnosis. Neuroimaging alone will thus usually not provide a diagnosis. It will rather bring arguments in favour, or against, a potential diagnosis (for instance, in the exploration of a dementia syndrome, MRI can bring positive arguments for a diagnosis of Alzheimer's disease due to the observed atrophy in specific areas or on the contrary exclude this diagnosis by showing that the syndrome is due to a different cause such as for instance a brain tumour). Overall, the diagnosis will generally be made by the neurologist or the psychiatrist based on a combination of clinical examination and a set of multimodal data (clinical and cognitive tests, radiological report, biomarkers, etc.).

However, the use of neuroimages goes way beyond visual inspection and is subject to quantification using image processing procedures. This is particularly true in research even though image processing tools are also increasingly used in clinical routine. A characteristic of these tools that differentiates them from general purpose image processing tools is their ability to handle three-dimensional (3D) images.

2.1 The nature of 3D medical images

Most medical imaging devices acquire 3D images. This is the case of all the ones presented in this chapter (MRI, CT, PET and SPECT). If 2D images are essentially 2D arrays of elements called pixels (for picture elements), 3D images are 3D arrays of elements called voxels (for volume elements). Depending on the imaging modality, voxel values will represent different properties of the underlying tissues. For example, in a CT image, they will be proportional to linear attenuation coefficients. The shape and size of a voxel will also depend on the imaging modality (or the type of sequence in MRI). When its three dimensions are of equal lengths, the voxel is isotropic; otherwise it is anisotropic (see Figure 3). For instance, a typical voxel size for a T1-weighted MR image is about $1 \times 1 \times 1 \text{ mm}^3$, while it is about $3 \times 3 \times 3 \text{ mm}^3$ for a functional MR image. Most neuroimaging modalities will have a voxel dimension between 0.5 mm and 5 mm.

Even though most neuroimages are 3D, they are visualised as 2D slices along different planes: axial, coronal or sagittal (see Figure 4). Multiple tools exist to visualise neuroimages. Several are available within suites such as FSLeves¹, Freeview² or medInria³, while others are independent

¹FSLeves: <https://fsl.fmrib.ox.ac.uk/fsl/fslwiki/FSLeves>

²Freeview: <https://surfer.nmr.mgh.harvard.edu/fswiki/FreeviewGuide>

³medInria: <https://med.inria.fr>

such as Vinci⁴, Mango⁵ or Horos⁶. Note that viewers may interpolate the images they display, which may be misleading (see Figure 5 for an illustration).

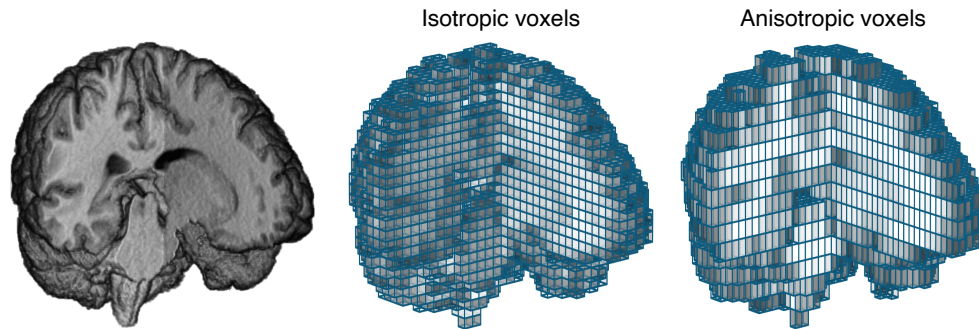


Figure 3: Most neuroimaging modalities are three dimensional. Left: volume rendering of an excavated T1-weighted MR image Middle: voxel grid with isotropic, i.e., cubic, voxels overlaid on the MRI. Right: voxel grid with anisotropic, i.e., rectangular, voxels overlaid on the MRI.

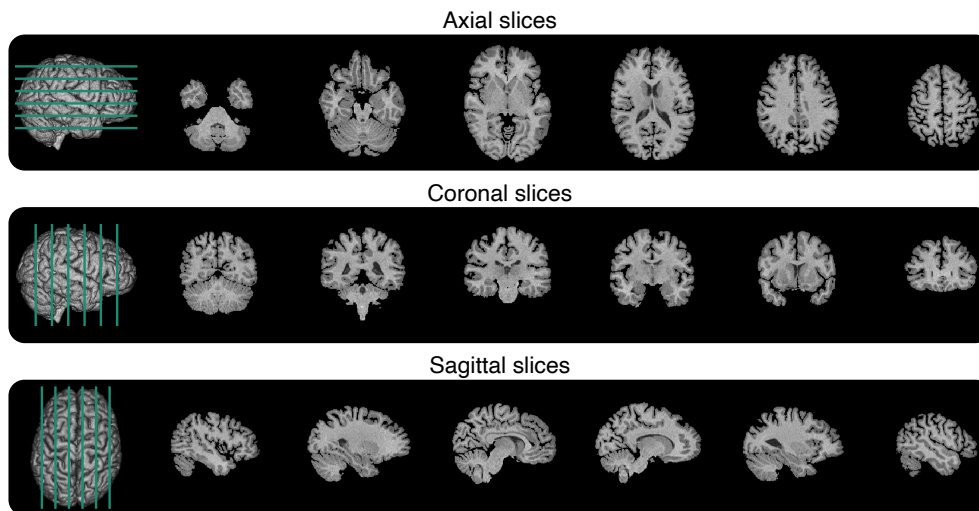


Figure 4: Axial, coronal and sagittal slices extracted from a T1-weighted MR image.

⁴Vinci: <https://vinci.sf.mpg.de>

⁵Mango: <http://ric.uthscsa.edu/mango>

⁶Horos: <https://horosproject.org>

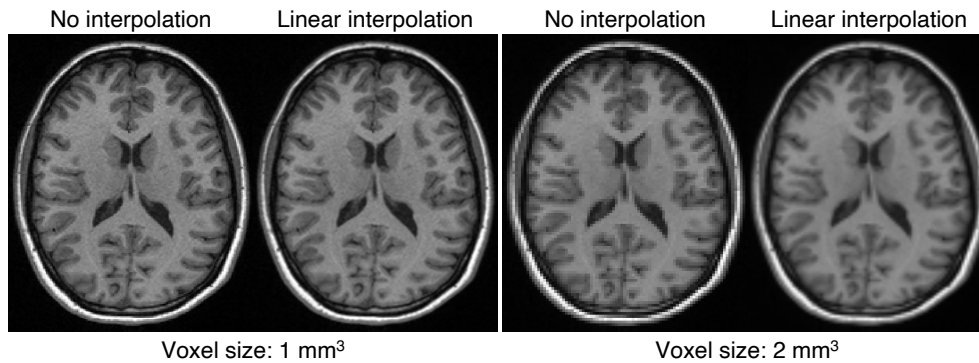


Figure 5: Axial slice of a T1-weighted MRI with an isotropic voxel size originally of $1 \times 1 \times 1 \text{ mm}^3$ (left) and downsampled to $2 \times 2 \times 2 \text{ mm}^3$ (right) displayed without interpolation or with linear interpolation. If the difference with or without interpolation is subtle at $1 \times 1 \times 1 \text{ mm}^3$, it is well visible at $2 \times 2 \times 2 \text{ mm}^3$.

2.2 Extracting features from neuroimages

When using machine learning to analyse images, one will often extract features. These features can be grouped into four categories that we will now describe and are illustrated in Figure 6. Note that these features are conceptually the same for the different modalities but their actual content will differ (e.g., volume of a region for anatomical MRI vs average uptake in this region for PET). Modality-specific preprocessing and corrections often need to be applied before neuroimages can be analysed, these will be described in Sections 3, 4 and 5.

Voxel-based features As mentioned previously, all the imaging modalities described in this chapter produce volumetric images. The whole 3D image can be used as input of a machine learning algorithm. In that case, each subject is seen as a collection of values at each voxel of the image. These values can simply be the intensity of the image at each voxel after some minimal preprocessing (which is very often what is used in deep learning) or some more complex value extracted from the image (for instance grey-level density from anatomical MRI, see Section 3.1). A prerequisite is often to align the images studied in a common space, by registering each image to a template and/or by performing a group-wise registration, thus guaranteeing a voxel-wise correspondence across subjects [16]. Note that this correspondence becomes particularly important when using an machine learning algorithm that takes as input a vector whose each component implicitly represents the same information for each subject (e.g., logistic regression or support vector machine).

Vertex-based features Studying the surface of the cortex is natural given its shape: it is a convoluted ribbon delimited by inner and outer surfaces. Moreover, surface-based characteristics can provide useful information such as for developmental or neurodegenerative diseases. Surfaces can be represented as meshes consisting of vertices, edges and faces. The vertices encode position and properties such as cortical thickness. In the vertex-based feature scenario, each subject is seen as a collection of values at each vertex of the surface. Classical values computed at each vertex include cortical thickness and local surface area (see Section 3.1). As for voxel-based features, images studied are usually aligned in a common space to ensure a vertex-wise correspondence across subjects [17, 18].

Regional features The brain can be divided into sub-regions according to different criteria that can be anatomical or functional [16]. When considering regional features, each subject is seen as a collection of values for each region of the brain defined by an atlas. Many atlases exist, either anatomical or functional, with different degrees of granularity. A list can be found online⁷. Classical values include the volume of a given region or the average image signal within a region.

Graph-based features A last way to represent an image is through a graph where nodes will correspond to brain regions and edges will encode a particular property (for instance anatomical or functional connections, possibly together with their strength). Graphs can directly be used as features but network indices characterising global and local graph topology, e.g., efficiency or degree, can also be computed [19].

2.3 Neuroimaging software tools

The features described above can be obtained using neuroimaging software tools. However, an important step before any preprocessing or analysis is to properly organise data. The neuroimaging community proposed the Brain Imaging Data Structure [20], which specifies how to organise data in folders and sub-folders on disk, and how to name the files. It also details the metadata necessary to describe neuroimaging experiments.

Many tools exist to process neuroimages⁸. The historical generic

⁷List of atlases: <https://www.lead-dbs.org/helpsupport/knowledge-base/atlasresources>

⁸List of open source medical imaging software tools: <https://idoimaging.com>

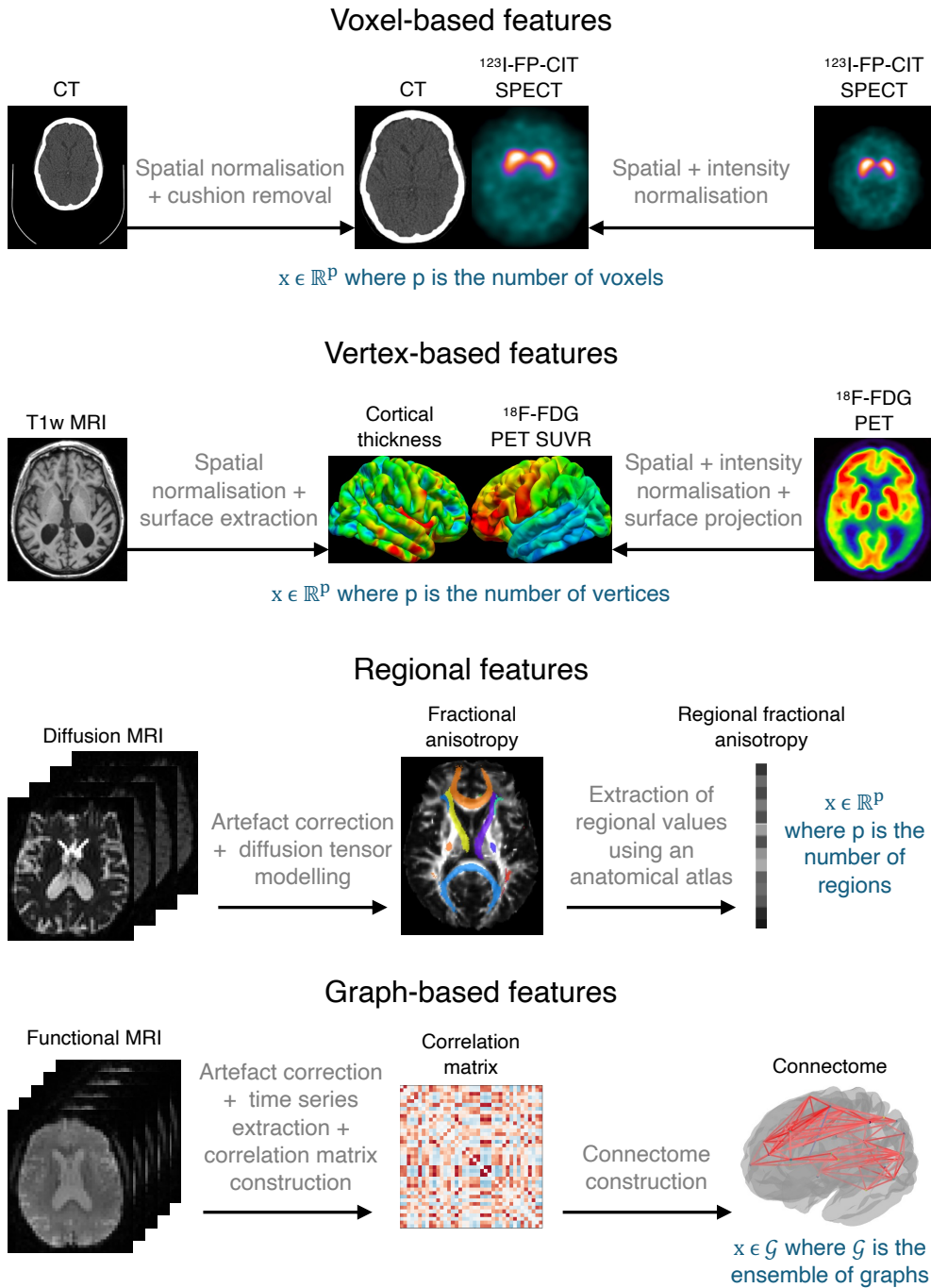


Figure 6: Examples of voxel, vertex, regional and graph features that can be extracted from neuroimages. It is for instance possible to extract voxel-based features from CT and SPECT images, vertex-based features from anatomical T1-weighted (T1w) MRI or PET images, regional features from diffusion MRI and graph-based features from functional MRI. Note that the modalities are just examples. For instance, voxel-based features can be extracted for any modality. See sections 3, 4 and 5 for a description of the imaging modalities.

frameworks include SPM⁹ [21], FSL¹⁰ [22], FreeSurfer¹¹ [23] or ANTs¹² [24]. Some tools are modality-specific such as MRtrix¹³ [25], dedicated to diffusion MRI, or AFNI¹⁴ [26], dedicated to functional MRI. Recent initiatives aim to make the use of neuroimaging tools easier by distributing them in containers (e.g., BIDSApps¹⁵ [27]), by providing in a single environment tools from preprocessing to machine learning (e.g., Nilearn¹⁶ [28]), or by providing automatic pipelines that do not require a particular expertise in image processing (e.g., Clinica¹⁷ [29]). Other tools facilitate the application of deep learning approaches to neuroimages or medical images in general: for instance MONAI¹⁸, TorchIO¹⁹ [30] or ClinicaDL²⁰ [31].

3. Magnetic resonance imaging

Magnetic resonance imaging is the modality of choice to study brain anatomy thanks to its high resolution and excellent soft-tissue contrast, but the applications of MRI go well beyond studying anatomy. This technique can be used to examine tissue micro-architecture (diffusion MRI, covered in Section 3.2) or neuronal activity (functional MRI, covered in Section 3.3), but also to visualise the brain vasculature (MR angiography), study tissue perfusion and permeability (perfusion MRI), assess iron deposits and calcifications (susceptibility-based imaging) or measure the levels of different metabolites (MR spectroscopy). Note that MRI is an extremely versatile modality and that new sequences are constantly developed to study other brain characteristics.

3.1 Anatomical MRI

3.1.1. Basic principles

In MRI, most images are obtained by exploiting a magnetic property, called spin, of the hydrogen atomic nuclei found in the water molecules

⁹SPM: <https://www.fil.ion.ucl.ac.uk/spm>

¹⁰FSL: <https://fsl.fmrib.ox.ac.uk>

¹¹FreeSurfer: <https://surfer.nmr.mgh.harvard.edu>

¹²ANTs: <http://stnava.github.io/ANTs>

¹³MRtrix: <https://www.mrtrix.org>

¹⁴AFNI: <https://afni.nimh.nih.gov>

¹⁵BIDSApps: <https://bids-apps.neuroimaging.io/apps>

¹⁶Nilearn: <https://nilearn.github.io>

¹⁷Clinica: <https://www.clinica.run>

¹⁸MONAI: <https://monai.io>

¹⁹TorchIO: <https://torchio.readthedocs.io>

²⁰ClinicaDL: <https://clinicadl.readthedocs.io>

present in the human body. In the absence of a strong external magnetic field, the directions of the proton's spins are random, thus cancelling each other out (Figure 7, a). When the spins enter a strong external magnetic field (B_0) they align either parallel or anti-parallel and they all precess around the B_0 axis, referred to as the z axis (Figure 7, b). As a result, they cancel each other out in the transverse (x, y) plane but they add up along the z axis. The result of this vector addition, called net magnetisation M_0 , is proportional to the proton density (Figure 7, c). With the application of a radio frequency pulse denoted as B_1 , the system of spins and the net magnetisation are tipped by an angle determined by the strength and duration of the radio frequency pulse. For a 90° radio frequency pulse, the magnetisation along the z axis (M_z) becomes zero and the magnetisation in the transverse plane (M_{xy}) becomes equal to M_0 (Figure 7, d). As this radio frequency pulse provides energy, or excites, the spins, we also talk of radio frequency excitation.

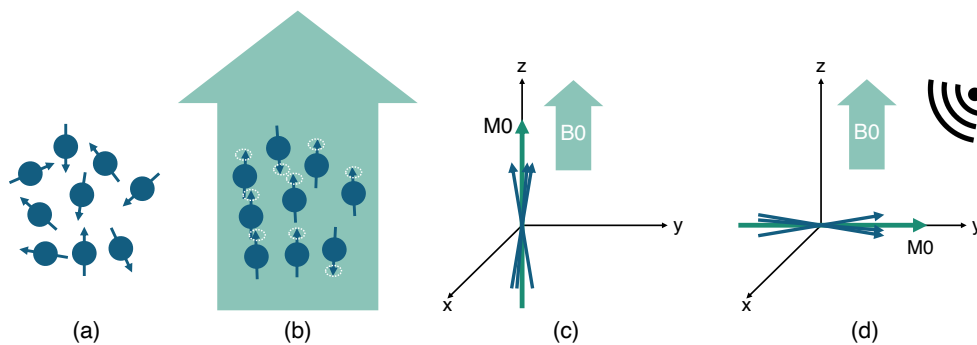


Figure 7: *MRI physics in a nutshell.* (a) In the absence of a magnetic field, the directions of the proton's spins are random. (b) When the spins enter a strong external magnetic field (B_0) they align either parallel or anti-parallel and they all precess around the B_0 axis. (c) The net magnetisation M_0 is proportional to the proton density. (d) With the application of a radio frequency pulse, the system of spins is tipped.

When the radio frequency pulse is then turned off, two phenomena occur. First, the system of spins relaxes back to its preferred energy state of being parallel with B_0 in a time T_1 , called longitudinal or spin-lattice relaxation time, and the longitudinal magnetisation M_z slowly recovers to its original magnitude M_0 . Second, each spin starts precessing at a frequency that is slightly different from the one of its neighbouring spins because the field of the MRI scanner is not uniform and because each spin is influenced by the small magnetic fields of the neighbouring spins. When the spins are completely dephased, they are evenly spread in the transverse plane and M_{xy} becomes zero. M_{xy} decreases at a much faster

rate than that at which M_z recovers to M_0 . The transverse relaxation time T_2 , also called spin-spin relaxation time, describes the M_{xy} decrease because of interference from neighbouring spins, while T_2^* describes the decrease because of both spin-spin interactions and non-uniformities of B_0 . Finally, the MRI signal is obtained by measuring the transverse magnetisation as an electrical current by induction.

The contrast in MR images depends on three main parameters: the proton density, the longitudinal relaxation time T_1 , and the transverse relaxation time T_2 . These parameters can be adjusted by changing the time at which the signal is recorded, called echo time, and the interval between successive excitation pulses, called repetition time. A T_1 -weighted image is created by choosing a short repetition time, a T_2 -weighted image by choosing a long echo time and a proton density (PD)-weighted image by minimising both the T_1 and T_2 weighting of the image (long repetition time and short echo time). The corresponding images are referred to as T_1 -weighted MRI, T_2 -weighted MRI and PD-weighted MRI. Note that many variations of these sequences exist (for instance gradient-echo vs spin-echo) and the corresponding implementation by different manufacturers usually comes with a specific commercial name (e.g., MPRAGE is a T_1 -weighted sequence available on Siemens scanners). Furthermore, many more anatomical sequences exist including T_2^* -weighted, T_2 -FLAIR (fluid attenuated inversion recovery) or DIR (double inversion recovery). Examples are displayed in Figure 8. The set of sequences chosen by the radiologist will depend on the potential disease that is being investigated. Some examples in the context of machine learning are given in Section 3.1.3.

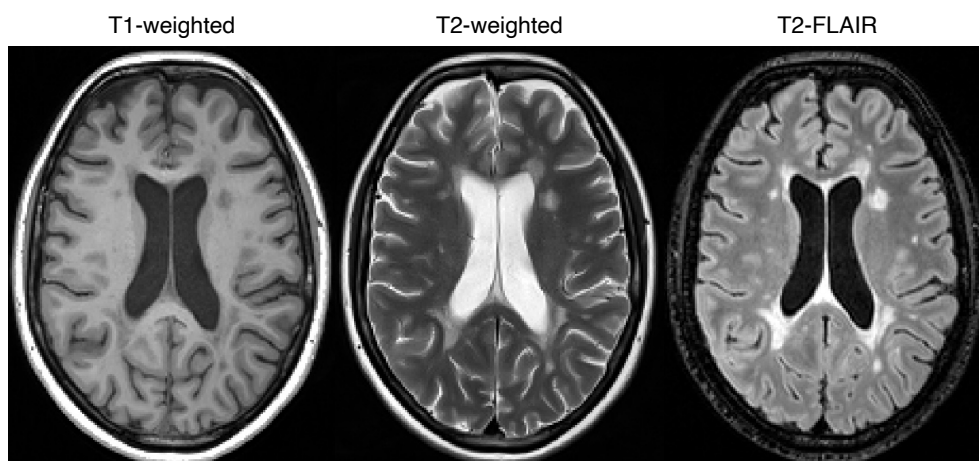


Figure 8: Example of anatomical MR images. T_1 -weighted, T_2 -weighted and T_2 -FLAIR images of a patient with multiple sclerosis from the MSSEG MICCAI 2016 challenge data set [32, 33].

3.1.2. Extracting features from anatomical MRI

Several preprocessing steps are often necessary before analysing anatomical MR images to correct imperfections and ease their comparison.

Bias field correction MR images can be corrupted by a low frequency and smooth signal caused by magnetic field inhomogeneity. This bias field induces variations in the intensity of the same tissue in different locations of the image, which deteriorates the performance of image analysis algorithms such as registration or segmentation. Several methods exist to correct these intensity inhomogeneities, the most popular being the N4 algorithm [34] available in ANTs [24].

Intensity rescaling and standardisation As MRI is usually not a quantitative imaging modality, MR images can have different intensity ranges and the intensity distribution of the same tissue type may be different between two images, which might affect the subsequent image preprocessing steps. The first point can be dealt with by globally rescaling the image, for example between 0 and 1 using the minimum and maximum intensity values. More robust choices exist such as the z-score normalisation (at each voxel, one subtracts the mean intensity of the image and the result is divided by the standard-deviation across the image), which can be made even more robust by only considering a percentile of the intensities for computing the mean and standard deviation. Intensity standardisation, to solve the second point, can be achieved using techniques such as histogram matching [35].

Skull stripping Extra-cranial tissues can be an obstacle for image analysis algorithms [36]. A large number of methods have been developed for brain extraction, also called skull stripping. Some are available in neuroimaging software platforms such as FSL [22] or BrainSuite [37], and others as independent tools^{21,22} [38, 39]. Note that these methods can be sensitive to the presence of noise and artefacts, which can result in over or under segmentation of the brain.

Image registration Medical image registration consists in spatially aligning two or more images, either globally (rigid and affine registration) or locally (non-rigid registration), so that voxels in corresponding positions contain comparable information. A large number of software tools have been developed for MRI-based registration [40]. They are available

²¹HD-BET: <https://github.com/MIC-DKFZ/HD-BET>

²²SynthStrip: <https://surfer.nmr.mgh.harvard.edu/docs/synthstrip>

in all the major platforms (e.g., SPM [21], FSL [22], FreeSurfer [23] or ANTs [24]).

Image segmentation Medical image segmentation consists in partitioning an image into a set of non-overlapping regions. When processing brain images, these regions can correspond to tissue types, e.g., grey matter, white matter and cerebrospinal fluid [41], but also to anatomical (e.g., hippocampus, pons) or functional (e.g., language network, sensorimotor network) regions defined by an atlas [42]. As for registration, many tools have been developed for MRI-based segmentation and are available, among others, in SPM [21], FSL [22], FreeSurfer [23] or ANTs [24].

Resulting features Based on the combination of one, several, or all, of the previously mentioned preprocessing steps, various types of features can be extracted that correspond to those described in Section 2.2. For deep learning algorithms, which usually exploit voxel-based features, it is quite common to perform only very basic preprocessing. At the simplest, it can be intensity normalisation (this step is mandatory for deep learning methods to work correctly). It is often combined with a bias field correction and a linear registration to a common space. Another common type of voxel-based features is that of tissue density maps (e.g., grey matter or white matter density) [43]. Their extraction involves bias field correction, registration to a common space and tissue segmentation. Common vertex-based features are the local thickness and the local surface area [44]. Regional features are usually the volume of different regions of the brain but they can also be the average intensity within the region or the average of another image-derived value. They can as well be related to lesions (for instance the volume of multiple sclerosis lesions or of different compartments of a brain tumour) rather than anatomical regions. Finally, graph-based features can also be computed from anatomical MRI [45] even though this representation is more common for diffusion MRI and functional MRI.

3.1.3. Examples of applications in machine learning studies

T1-weighted MRI is the sequence the most commonly found in machine learning studies applied to brain disorders. Several features can be extracted from T1-weighted MRI such as the volume of the whole brain or of regions of interest, the density of a particular tissue, e.g., grey matter, or the local cortical thickness and surface area. All these features, as well as the raw T1-weighted MR images, have for example largely been used for the computer-aided diagnosis of dementia, in particular Alzheimer's

disease, as they highlight atrophy, i.e., the neuronal loss that is a marker of neurodegenerative diseases [46, 47, 48, 49].

T1-weighted MR images acquired with and without the injection of a contrast agent are often used in the context of brain tumour detection and segmentation, progression assessment, and survival prediction as they allow distinguishing active tumour structures [50]. Such tasks also typically rely on another sequence called T2-weighted fluid-attenuated inversion recovery (T2-FLAIR) that allows visualising a wide range of lesions on top of tumours [51], such as those appearing with multiple sclerosis [52, 53] or age-related white matter hyperintensities (also called leukoaraiosis, which is linked to small vessel disease).

3.2 Diffusion-weighted MRI

3.2.1. Basic principles

Diffusion MRI [54, 55] allows visualising tissue micro-architecture thanks to the diffusion of water molecules. Depending on their surroundings, water molecules are able to either move freely, e.g., in the extracellular space, or move following surrounding constraints, e.g., within a neuron. In the former situation the diffusion is isotropic while in the later it is anisotropic. Contrast in a diffusion MR image originates from the fact that, following the application of an excitation pulse, water molecules that move in a particular direction, and so the protons they contain, do not have the same magnetic properties as the ones that move randomly but not far from their origin point. The excitation pulse is parametrised by a weighting coefficient b : the higher the b -value, the more sensitive the acquisition is to water diffusion, but the lower the signal-to-noise ratio. Several diffusion MRI volumes, each volume corresponding to a particular b -value and gradient direction, are usually acquired. See examples in Figure 9 (top row).

3.2.2. Extracting features from diffusion MRI

Diffusion MR images are typically acquired with echo-planar imaging, a technique that spatially encodes the MRI signal in a way that enables fast acquisitions with a relatively high signal-to-noise ratio. However, echo-planar imaging induces geometric distortions and signal losses known as magnetic susceptibility artefacts. Other artefacts include eddy currents (due to the rapid switching of diffusion gradients), intensity inhomogeneities (as for anatomical MRI) and potential movements of the subject during the acquisition. These artefacts need to be corrected before further analysing the images. Various methods exist to do so, they

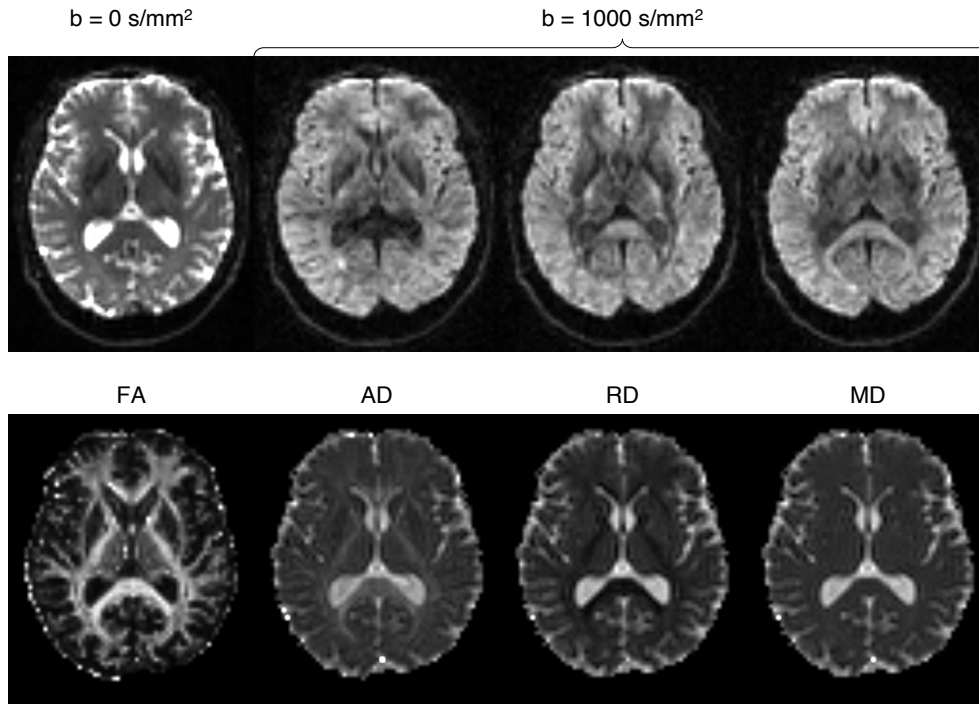


Figure 9: Example of diffusion-weighted MR images. Top: Diffusion volumes acquired using different b -values (0 and 1000 s/mm^2) and gradient directions. Bottom: Parametric maps resulting from diffusion tensor modelling (fractional anisotropy - FA, axial diffusivity - AD, radial diffusivity - RD, and mean diffusivity - MD).

are reviewed in [56]. Two widely used tools enabling the preprocessing of diffusion MR images are FSL [22] and MRtrix [25], but others exist²³ [56].

Once artefacts have been corrected, diffusion MR images can be analysed in different ways. One of the earliest strategy for modelling water diffusion is the diffusion tensor imaging (DTI) model [57]. Such model can output parametric maps describing several diffusion properties: fractional anisotropy (FA - directional preference of diffusion), mean diffusivity (MD - overall diffusion rate, also called apparent diffusion coefficient), axial diffusivity (AD - diffusion rate along the main axis of diffusion) and radial diffusivity (RD - diffusion rate in the transverse direction). Examples of parametric maps are displayed in Figure 9 (bottom row). DTI tractography [58] goes one step further by reconstructing white matter tracts. Other diffusion models have been developed to better characterise tissue micro-architecture. This is for example the case of neurite orientation dispersion and density imaging (NODDI) [59], which enables the

²³List of tools and software packages to process diffusion MRI: <https://github.com/dmripreprocessing/neuroimage-review-2022>

study of neurite morphology by disentangling neurite density and orientation dispersion that both independently influence fractional anisotropy.

One can then again compute most of the different types of features covered in Section 2.2. Voxel-based features will represent the value of a given parametric map (e.g., FA, MD). Surface-based features are seldom used because diffusion MRI often focuses on the white matter even though it is in principle possible to project maps that are of interest in the grey matter onto the cortical surface. Regional features represent the average of a given map (e.g., FA, MD) in a set of anatomical regions. Graph-based features can be computed as follows: vertices are often regions of the cortex, and edges correspond to the connection strength, which can be derived for instance from the number of tracts connecting two regions or the average FA within those tracts.

3.2.3. Examples of applications in machine learning studies

Machine learning studies have mainly used diffusion MRI to assess white matter integrity. This has been done in a very wide variety of disorders. For example, fractional anisotropy and mean diffusivity have been used to differentiate cognitively normal subjects from patients with mild cognitive impairment or Alzheimer's disease [60, 61]. Diffusion MRI has also been exploited to perform tumour grading or subtyping [62] following the assumption that the cellular structure may differ between cancerous and healthy tissues.

3.3 Functional MRI

3.3.1. Basic principles

When a region of the brain gets activated by a cognitive task, two phenomena occur: a local increase in cerebral blood flow and changes in oxygenation concentration [63]. Functional MRI (fMRI) is used to measure the latter phenomenon. The blood oxygen level dependent (BOLD) contrast originates from the fact that haemoglobin molecules that carry oxygen have different magnetic properties than haemoglobin molecules that do not carry oxygen.

Task fMRI consists in inducing particular neural states, for example by performing tasks involving the visual or auditory systems, and then comparing the signals recorded during the different states. As the differences observed are small, it is important to preserve at best the signal-to-noise ratio that could be degraded because of head motion or polluted by fluctuations of the cardiac and respiratory cycles. This is done by quickly acquiring multiple image volumes with echo-planar imaging. The

BOLD signal also varies when the brain is not performing any particular task [64]. These spontaneous fluctuations are studied with resting-state fMRI.

3.3.2. Extracting features from functional MRI

The preprocessing of functional MR images has two main objectives: limit the effect of non-neural sources of variability and correct acquisition-related artefacts [65]. Preprocessing steps can for example include susceptibility distortion correction (as for diffusion MRI); head-motion correction, by registering each volume in the time series to a reference volume (e.g., the first volume); slice-timing correction, to eliminate differences between the time of acquisition of each slice in the volume; or physiologic noise correction, by temporal filtering [63, 65]. These preprocessing steps can be performed using tools such as SPM [21], FSL [22] or AFNI [26], but also using the dedicated fMRIPrep workflow [65].

The majority of machine learning studies in brain disorders focuses on resting-state rather than task fMRI [66]. This can be explained by the fact that the resting-state protocol is simpler and allows multi-site studies (as it is less sensitive to changes in local experimental settings) [66], which should result in larger samples. Depending on the application, preprocessed resting-state fMRI data may be further processed to extract features. One can directly use voxel-based features (or vertex-based features by projecting the functional MRI signal onto the cortical surface) [67]. Nevertheless, to the best of our knowledge, the most common features are graph-based. Indeed, most supervised algorithms for classification or regression use brain networks extracted from resting-state time-series. In these networks, also called connectomes, the vertices correspond to brain regions, which size may vary, and the edges encode the functional connectivity strength, which corresponds to the correlation between time-series.

3.3.3. Examples of applications in machine learning studies

Machine learning methods exploiting resting-state fMRI data have been used to investigate brain development and aging, but also neurodegenerative and psychiatric disorders [66]. Functional connectivity patterns have for instance been used to distinguish patients with schizophrenia from healthy controls [68] or discriminate schizophrenia and bipolar disorder from healthy controls [69].

4. X-ray imaging

X-ray imaging is built on the work of Röntgen who observed that if a ‘hand be held before the fluorescent screen, the shadow shows the bones darkly, with only faint outlines of the surrounding tissues’ [3].

4.1 X-ray and angiography

When an X-ray beam passes through the body, part of its energy is absorbed or scattered: the number of X-ray photons are reduced by attenuation (Figure 10, left). On the opposite side of the body, detectors capture the remaining X-ray photons and an image is generated. In an X-ray image, the contrast, defined as the relative intensity change produced by an object, originates from the variations in linear attenuation coefficient with tissue type and density.

X-ray imaging provides excellent contrast between bone, air and soft-tissue but very little contrast between the different types of soft-tissue, hence its limited use when studying brain disorders. However, coupled with the injection of an iodine-based contrast agent, X-ray imaging enables visualising cerebral blood vessels and detecting potential abnormalities such as an aneurysm. This technique is called X-ray angiography.

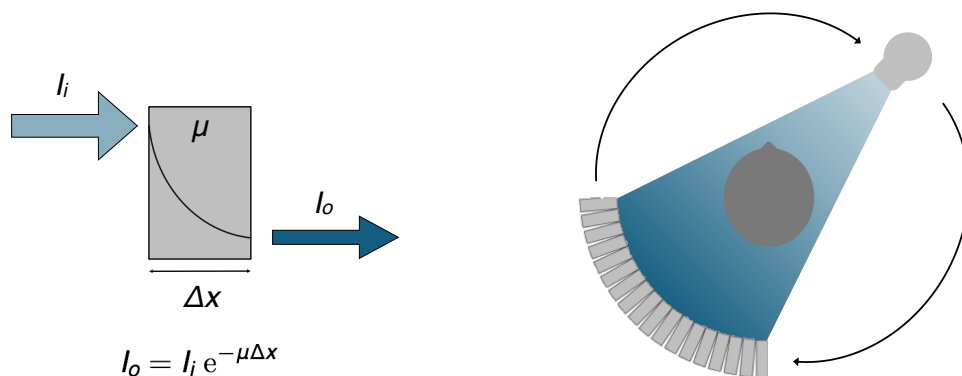


Figure 10: *Left: Attenuation of X-rays by matter. As it passes through a material of thickness Δx and linear attenuation coefficient μ , the x-ray beam is attenuated. Its intensity decreases exponentially with the distance travelled: $I_o = I_i e^{-\mu\Delta x}$, where I_i and I_o are the input and output X-ray intensities. Right: Third generation CT. A 3D image is created by rotating the X-ray source and detectors around the body.*

4.2 Computed tomography

4.2.1. Basic principles

Although the X-ray images produced were originally in 2D, X-ray computed tomography enables the reconstruction of 3D images by rotating the X-ray source and detectors around the body (Figure 10, right). Rather than using the absolute values of the linear attenuation coefficients, CT image intensities are expressed in a standard unit, the Hounsfield unit (HU). The tissue attenuation coefficient is compared to the attenuation value of water and displayed on the Hounsfield scale

$$x_{HU} = 1000 \times \frac{x_{\mu} - \mu_{water}}{\mu_{water} - \mu_{air}}$$

where μ_{water} and μ_{air} are the linear attenuation coefficients of water and air, respectively. For example, air has an attenuation of -1000 HU, water of 0 HU and cortical bone between 500 and 1900 HU.

As for 2D X-ray imaging, the injection of an iodine-based contrast agent improves the visualisation of cerebral blood vessels. This technique, called CT angiography, is not the only one relying on a contrast agent. CT perfusion tracks the bolus of contrast agent over time and measures the resulting change in signal intensity. Perfusion parameters such as the cerebral blood flow or volume can then be derived [70].

4.2.2. Extracting features from CT images

Contrary to MRI, CT images usually do not require extensive preprocessing steps [71]. It can however be useful to extract the head from the hardware elements visible on the image (e.g., the bed or pillow) or extract the brain. This can be done using thresholding and morphological operators. Another common step is spatial normalisation.

In the context of stroke, non-contrast CT is useful to detect an intracranial haemorrhage, which appears brighter than the surrounding tissues, or to estimate the extent of early ischemic injury, which results in a loss of grey-white matter differentiation. CT angiography can help identify a potential intracranial arterial occlusion and CT perfusion allows differentiating the regions with nonviable/non-salvageable tissue, which have very low cerebral blood flow and volume, from the viable and potentially salvageable regions [70]. These techniques may also be employed in the context of brain tumours. In particular, contrast-enhanced CT can detect areas presenting a blood-brain barrier breakdown [72]. An example of CT acquired before and after contrast injection is displayed in Figure 11.

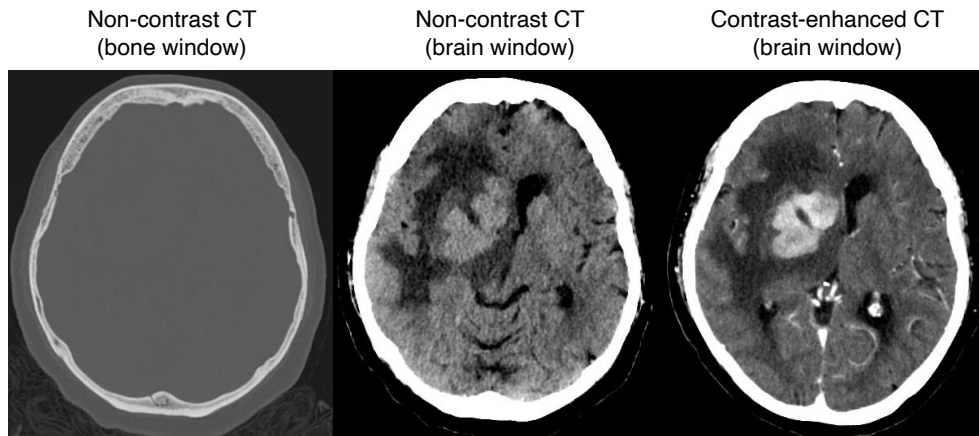


Figure 11: *Example of CT images. Non-contrast CT images, whose window levels were adjusted to better visualise bone or brain tissues, and contrast-enhanced CT image of a patient with lymphoma. Case courtesy of Dr Yair Glick, [Radiopaedia.org](https://radiopaedia.org), rID: 94844.*

To the best of our knowledge, CT is most often used in machine learning in the form of voxel-based features (the image intensities after some minimal preprocessing steps).

4.2.3. Examples of applications in machine learning studies

The vast majority of machine learning studies relying on CT images, particularly non-contrast CT, focus on cerebrovascular disorders [73, 74]. Non-contrast CT images were for example used for the detection of intracranial haemorrhage and its five subtypes [75]. A first neural network was in charge of identifying the presence or absence of intracranial haemorrhage and a second of determining the intracranial haemorrhage subtype, which depends on the bleeding location [75]. In [76], non-contrast CT and CT perfusion images were used to segment the core of stroke lesions, as the lesion volume is a key measurement to assess the prognosis of acute ischemic stroke patients.

5. Nuclear imaging

In X-ray CT imaging, the photons that are detected originate from an X-ray source. In nuclear imaging, and more precisely emission computed tomography, the photons detected are emitted from a radiopharmaceutical that has been intravenously injected to the patient.

5.1 Positron emission tomography

5.1.1. Basic principles

Positron emission tomography is an imaging technique that requires the injection of a substance labelled with a positron-emitting radioactive isotope [77]. The labelled substance is distributed throughout the patient's body by the blood circulation and accumulates in target regions. The positrons emitted by the radioactive isotope combine with the electrons present in the tissues and annihilate. Each annihilation produces two nearly colinear photons (Figure 12). The two photons are simultaneously detected by two opposing detectors and a coincidence event is assigned to a line of response connecting the two detectors.

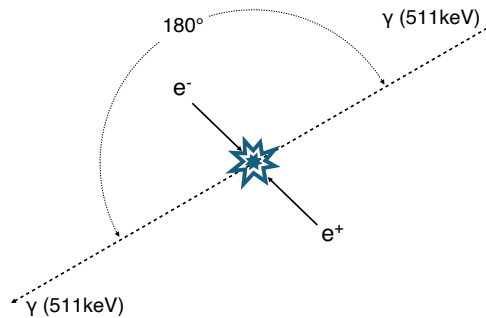


Figure 12: PET annihilation. When a positron (e^+) and an electron (e^-) collide, they annihilate and create a pair of collinear gamma rays (γ).

Note that the most common isotope in clinical routine is fluorine-18 (^{18}F), which has the advantage of a relatively long half-life (110 min) and thus does not require the presence of a cyclotron at the scanning site. Nevertheless, other isotopes are used. In particular, carbon-11 (^{11}C), which has a shorter half-life (20 min), is often used in research facilities equipped with a cyclotron.

In a time of flight PET system, the difference in arrival times between the two coincident photons is measured. Without time of flight information, the annihilation is located with equal probability along the line of response, while with time of flight information, the annihilation site can be reduced to a limited range (Figure 13), thus decreasing the spatial uncertainty and increasing the signal-to-noise ratio. Once reconstructed, the PET image is a map of the radioactivity distribution throughout the body.

Two main protocols exist when acquiring PET data. Most acquisitions are static: the radiotracer is injected several minutes before the

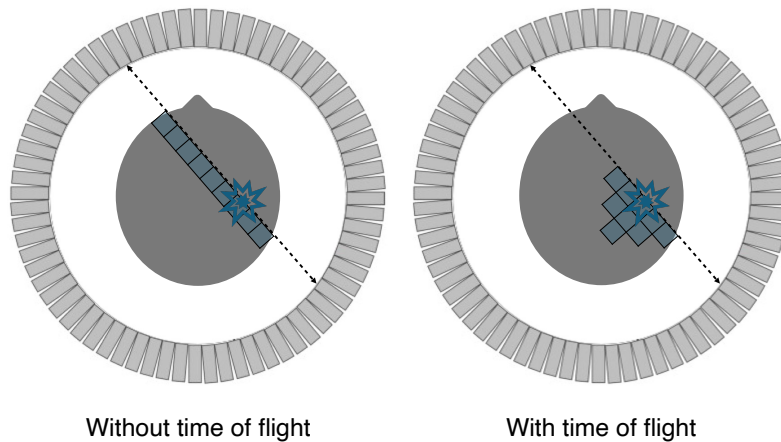


Figure 13: *Illustration of PET data detection. Without time of flight, the annihilation is located with equal probability along the line of response, while with time of flight, it is located in a limited portion of the line of response.*

acquisition (e.g., between 30 and 60 min), which gives the tracer time to diffuse in the body and accumulate in the target regions. The subject is then placed in the scanner and the acquisition lasts typically around 15 min. In the dynamic protocol, the subject is first installed in the scanner and the acquisition starts at the same time the tracer is being injected. This allows recording how the tracer diffuses in the body. Dynamic acquisitions are less common than static ones because of their duration of 60–90 min, which reduces patient throughput. In both the static and dynamic protocols, the acquisition is often split in frames of fix (in the static case) or increasing (in the dynamic case) duration. A static acquisition of 15 min can typically be split into three frames of 5 min, resulting in three PET volumes, each corresponding to the average amount of radioactivity detected at each voxel during the time frame.

^{18}F -fluorodeoxyglucose (FDG) is the most widely used PET radiopharmaceutical [78, 77]. As an analogue of glucose, FDG is transported to a cell but, unlike glucose, it remains trapped in the cell. This radiopharmaceutical is an excellent marker of changes in glucose metabolism. In the brain, FDG acts as an indirect marker of synaptic dysfunction and is part of the diagnosis of epilepsy and neurodegenerative diseases, such as Alzheimer’s disease [79].

If ^{18}F -FDG is a non-specific tracer, other radiopharmaceuticals target specific molecular or biological processes and are thus preferentially used for studying specific diseases. Amyloid tracers, such as the ^{11}C Pittsburgh compound B, ^{18}F -florbetapir, ^{18}F -florbetaben and ^{18}F -flutemetamol, which bind to fibrillar $A\beta$ plaques, or tau tracers, such as ^{18}F -flortaucipir

and ^{18}F -MK-6240, which bind to neurofibrillary tangles, are for example used in the diagnosis of dementia syndromes [80]. Examples are displayed in Figure 14. Of note, the so-called amyloid tracers are in fact not specific of amyloid and also bind to myelin in the white matter, making them of interest for demyelinating disorders such as multiple sclerosis [81]. ^{11}C -methionine and ^{18}F -fluoroethyltyrosine are both used in neuro-oncology [82]. Note that these are just examples of tracers and dozens of tracers exist for imaging specific molecular or biological processes.

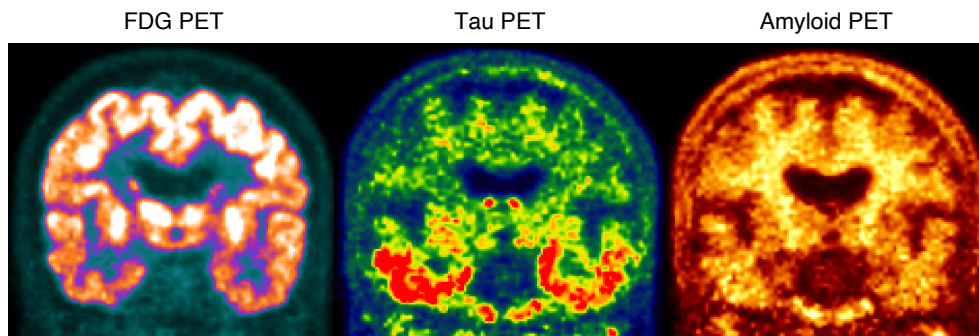


Figure 14: Example of PET images. Left: ^{18}F -FDG PET displaying brain glucose metabolism. Middle: ^{18}F -flortaucipir PET displaying the presence of tau neurofibrillary tangles. Right: ^{18}F -florbetapir PET displaying the presence of amyloid plaques. All the images correspond to the same Alzheimer’s disease patient from the ADNI study [83].

5.1.2. Extracting features from PET images

The reconstruction procedure of the PET signal already includes several corrections (e.g., attenuation and scatter corrections), but several processing steps can be performed before further analysing PET images. The first one is often motion correction. This is typically done by rigidly registering each frame to a reference frame. The registered frames are then averaged to form a single volume. To allow for inter-subject comparison, brain PET images need to be intensity normalised, for example to compensate for variations in the patients’ weight or dose injected. Standardised uptake value ratios (SUVRs) are generated by dividing a PET image by the mean uptake in a reference region. This region can be obtained from an atlas, and in this case chosen depending on the tracer and disorder suspected, or in a data-driven manner [84]. Partial volume correction can be performed to limit the spill-out of activity outside of the region where the tracer is meant to accumulate [85] using tools such as PETPVC [86]. Finally, PET images can also be spatially normalised.

If an anatomical image (preferably MRI but also CT) of the subject is available, the PET image is rigidly registered to the anatomical image and the anatomical image is registered to a template, often in standard space. By composing the two transformations, the PET image is spatially normalised. Alternatively, if no anatomical image is available, the PET image can directly be registered to a PET template, for example as implemented in SPM [87]. Dynamic PET images are further processed to extract quantitative physiological data using kinetic modelling, which is introduced in [78, 77].

One can then obtain different types of features, as described in Section 2.2. Voxel-based features will very often be the SUVR at each voxel, usually after spatial normalisation. Vertex-based features will generally be the SUVR projected onto the cortical surface [88]. Regional features will usually correspond to the average SUVR in each region of a parcellation. Graph-based features are less used than for diffusion or functional MRI but are still employed to study the so-called ‘metabolic connectivity’ [89].

5.1.3. Examples of applications in machine learning studies

Machine learning studies have mainly exploited brain PET images in the context of dementia [90]. For example, the usefulness of ^{18}F -FDG PET to differentiate patients with Alzheimer’s disease from healthy controls and patients with stable mild cognitive impairment from those who subsequently progressed to Alzheimer’s disease has been shown in [48, 91, 92]. ^{18}F -FDG PET has also been used to differentiate fronto-temporal dementia from Alzheimer’s disease [93]. In neuro-oncology, ^{11}C -methionine has been used to predict glioma survival [94] or to differentiate recurrent brain tumour from radiation necrosis [95].

5.2 Single-photon emission computed tomography

5.2.1. Basic principles

Single-photon emission computed tomography is an imaging technique that requires the injection of a substance labelled with an isotope that directly emits gamma radiation. Typical isotopes employed in neurology are technetium-99m ($^{99\text{m}}\text{Tc}$) and iodine-123 (^{123}I). As for PET, the labelled substance is distributed throughout the patient’s body by the blood circulation and accumulates in target regions. The photons emitted are detected by one to three detector heads, called gamma cameras, that rotate around the patient. Having multiple heads allows reducing image acquisition time and improving sensitivity as more photons can

be detected. Collimators are placed in front of the detector heads to localise the origin of the gamma rays: a gamma ray moving from the patient towards the camera has a higher probability of being detected if its direction aligns with the collimator (Figure 15) [96]. Once reconstructed, the SPECT image is a map of the radioactivity distribution throughout the body. Both dynamic and static protocols exist when acquiring SPECT data.

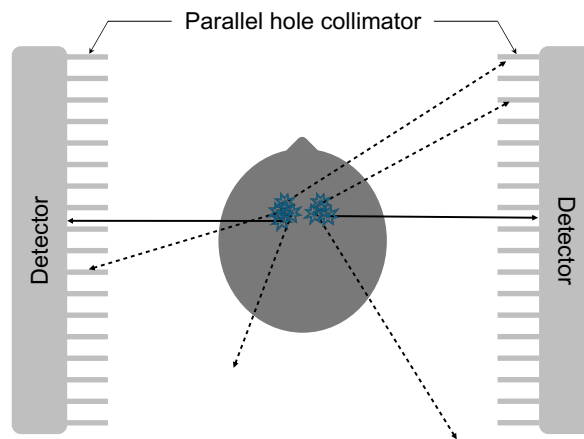


Figure 15: *Illustration of a two-head SPECT system with a parallel hole collimator. The photons whose emission direction is perpendicular to the detector heads have a higher probability of being detected (solid lines).*

SPECT is able to visualise and quantify changes in cerebral blood flow and neurotransmitter systems, such as the dopamine system [97, 98]. To image cerebral blood flow, the two most widely used tracers are ^{99m}Tc -HMPAO and ^{99m}Tc -ECD [97, 99]. These tracers can for example be employed in the context of dementia as a decrease in neural function will result in a decrease in cerebral blood flow in different regions. SPECT plays a key role when studying Parkinsonian syndromes, which are characterised by a loss of dopaminergic neurons. In this context, tracers targeting the dopaminergic system, such as ^{123}I - β -CIT and ^{123}I -FP-CIT (also called DaTscan), are employed to differentiate essential tremor from neurodegenerative Parkinsonian syndromes or distinguish dementia with Lewy bodies from other dementias [98]. Examples of SPECT images are displayed in Figure 16.

5.2.2. Extracting features from SPECT images

After the reconstruction of a SPECT image, which includes several corrections, two processing steps are typically performed: intensity normalisation and spatial normalisation [97, 98]. As for PET, the intensity of

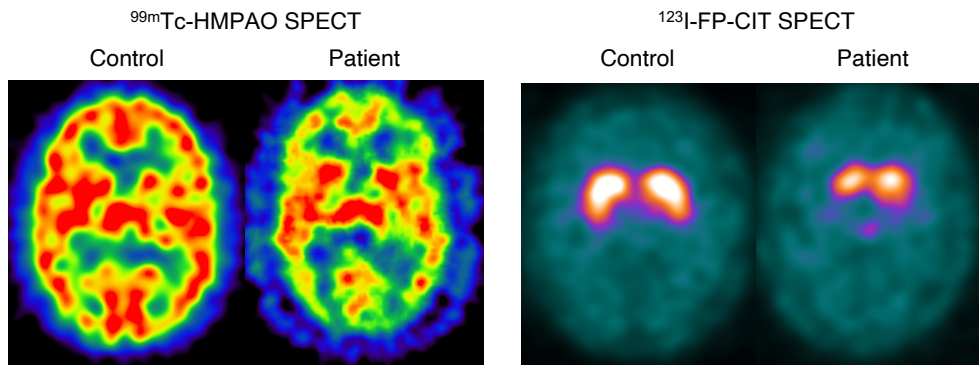


Figure 16: Examples of SPECT images. Left: ^{99m}Tc -HMPAO SPECT images of a normal control and an epileptic patient (<http://spect.yale.edu>) [100]. Right: ^{123}I -FP-CIT SPECT images of a normal control and a patient with Parkinson's disease from the PPMI study [101].

a SPECT image can be normalised using a reference region, and the image can be spatially normalised by directly registering it to a SPECT template or by registering it first to an anatomical image.

As for PET, the most common feature types are voxel-based (the normalised signal at each voxel) and regional features (often the average normalised signal within a region). To the best of our knowledge, vertex-based and graph-based features are rarely used although they could in principle be computed.

5.2.3. Examples of applications in machine learning studies

Machine learning studies have mainly exploited brain SPECT images for the computer-aided diagnosis of Parkinsonian syndromes [102]. ^{123}I -FP-CIT SPECT was for instance used to distinguish Parkinson's disease from healthy controls [103, 104], predict future motor severity [105], discriminate Parkinson's disease from non-Parkinsonian tremor [104], or identify patients clinically diagnosed with Parkinson's disease but who have scans without evidence of dopaminergic deficit [104].

In studies targeting dementia, both ^{99m}Tc -HMPAO [106] and ^{99m}Tc -ECD [107] tracers were used to differentiate between images from healthy subjects and images from Alzheimer's disease patients.

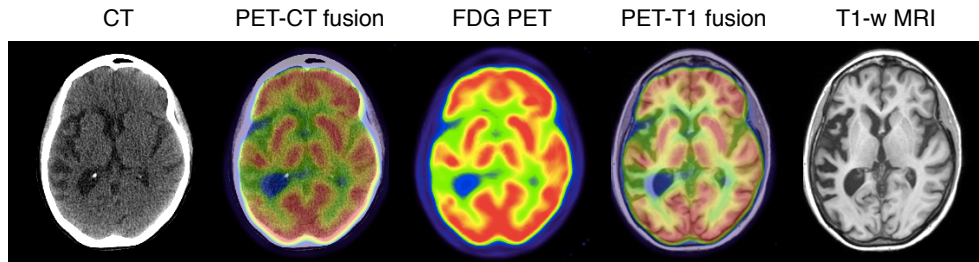


Figure 17: Example of ^{18}F -FDG PET, CT, T1-weighted MRI and fused images.

6. Conclusion

Neuroimaging plays a key role for the study of brain disorders. If some modalities provide information regarding the anatomy of the brain (CT and MRI), others provide functional or molecular information (MRI, PET and SPECT). To provide a complete picture of biological processes and their alterations, it is often necessary to combine multiple brain imaging modalities (Figure 17). This can be done by acquiring images with multiple standalone systems or with hybrid systems such as SPECT/CT, PET/CT or PET/MRI scanners [108].

When analysing neuroimages, both modality-specific and modality-agnostic processing steps must often be performed. These should be performed with care to obtain reliable features. Machine learning and deep learning are widely used to analyse neuroimaging data. The most common tasks are classification for computer-aided diagnosis, prognosis and disease subtyping, and segmentation to characterise anatomical structures and lesions.

Acknowledgments

The author would like to thank the editor for useful suggestions. The research leading to these results has received funding from the French government under management of Agence Nationale de la Recherche as part of the “Investissements d’avenir” program, reference ANR-19-P3IA-0001 (PRAIRIE 3IA Institute) and reference ANR-10-IAHU-0006 (Agence Nationale de la Recherche-10-IA Institut Hospitalo-Universitaire-6).

References

- [1] Ambrose J (1973) Computerized transverse axial scanning (tomography): Part 2. Clinical application. *The British Journal of Radiology* 46(552):1023–1047, DOI 10.1259/0007-1285-46-552-1023
- [2] Hounsfield GN (1973) Computerized transverse axial scanning (tomography): Part 1. Description of system. *The British Journal of Radiology* 46(552):1016–1022, DOI 10.1259/0007-1285-46-552-1016
- [3] Röntgen WC (1896) On a New Kind of Rays. *Science* 3(59):227–231
- [4] Ter-Pogossian MM, Phelps ME, Hoffman EJ, Mullani NA (1975) A Positron-Emission Transaxial Tomograph for Nuclear Imaging (PETT). *Radiology* 114(1):89–98, DOI 10.1148/114.1.89
- [5] Jaszczak RJ, Murphy PH, Huard D, Burdine JA (1977) Radionuclide Emission Computed Tomography of the Head with ^{99m}Tc and a Scintillation Camera. *Journal of Nuclear Medicine* 18(4):373–380
- [6] Keyes JW, Orlandea N, Heetderks WJ, Leonard PF, Rogers WL (1977) The Humongotron—A Scintillation-Camera Transaxial Tomograph. *Journal of Nuclear Medicine* 18(4):381–387
- [7] Becquerel H (1903) Recherches Sur Une Propriété Nouvelle de La Matière: Activité Radiante Spontanée Ou Radioactivité de La Matière. *Mémoires de l'Académie Des Sciences de l'Institut de France, L'Institut de France*
- [8] Young IR, Bailes DR, Burl M, Collins AG, Smith DT, McDonnell MJ, Orr JS, Banks LM, Bydder GM, Greenspan RH, Steiner RE (1982) Initial Clinical Evaluation of a Whole Body Nuclear Magnetic Resonance (NMR) Tomograph. *Journal of Computer Assisted Tomography* 6(1):1–18, DOI 10.1097/00004728-198202000-00001
- [9] Bloch F (1946) Nuclear Induction. *Physical Review* 70(7-8):460–474, DOI 10.1103/PhysRev.70.460
- [10] Townsend DW, Beyer T, Blodgett TM (2003) PET/CT scanners: A hardware approach to image fusion. *Seminars in Nuclear Medicine* 33(3):193–204, DOI 10.1053/snuc.2003.127314
- [11] Schlemmer HP, Pichler B, Wienhard K, Schmand M, Nahmias C, Townsend D, Heiss WD, Claussen C (2007) Simultaneous MR/PET for brain imaging: First patient scans. *Journal of Nuclear Medicine* 48(supplement 2):45P–45P
- [12] Schmand M, Burbar Z, Corbeil J, Zhang N, Michael C, Byars L, Eriksson L, Grazioso R, Martin M, Moor A, Camp J, Matschl V, Ladebeck R, Renz W, Fischer H, Jattke K, Schnur G, Rietsch N, Bendriem B, Heiss WD (2007) BrainPET: First human tomograph for simultaneous (functional) PET and MR imaging. *Journal of Nuclear Medicine* 48(supplement 2):45P–45P
- [13] Patton JA, Delbeke D, Sandler MP (2000) Image fusion using an integrated, dual-head coincidence camera with X-ray tube-based attenuation maps. *Journal of Nuclear Medicine* 41(8):1364–1368
- [14] Hutton BF, Occhipinti M, Kuehne A, Máthé D, Kovács N, Waiczies H, Erlandsson K, Salvado D, Carminati M, Montagnani GL, et al (2018) Development of clinical simultaneous SPECT/MRI. *The British journal of radiology* 91(1081):20160690, DOI 10.1259/bjr.20160690
- [15] Smith-Bindman R, Kwan ML, Marlow EC, Theis MK, Bolch W, Cheng SY, Bowles EJA, Duncan JR, Greenlee RT, Kushi LH, Pole JD, Rahm AK, Stout NK, Weimann S, Miglioretti DL (2019) Trends in Use of Medical Imaging in US Health Care Systems and in Ontario, Canada, 2000-2016. *JAMA* 322(9):843–856, DOI 10.1001/jama.2019.11456
- [16] Evans AC, Janke AL, Collins DL, Baillet S (2012) Brain templates and atlases. *Neuroimage* 62(2):911–922, DOI 10.1016/j.neuroimage.2012.01.024
- [17] Dale AM, Fischl B, Sereno MI (1999) Cortical surface-based analysis: I. Segmentation and surface reconstruction. *Neuroimage* 9(2):179–194, DOI 10.1006/nimg.1998.0395
- [18] Fischl B, Sereno MI, Dale AM (1999) Cortical surface-based analysis: II: inflation, flattening, and a surface-based coordinate system. *Neuroimage* 9(2):195–207, DOI 10.1006/nimg.1998.0396

- [19] de Vico Fallani F, Richiardi J, Chavez M, Achard S (2014) Graph analysis of functional brain networks: practical issues in translational neuroscience. *Philosophical Transactions of the Royal Society B: Biological Sciences* 369(1653):20130521, DOI 10.1098/rstb.2013.0521
- [20] Gorgolewski KJ, Auer T, Calhoun VD, Craddock RC, Das S, Duff EP, Flandin G, Ghosh SS, Glatard T, Halchenko YO, Handwerker DA, Hanke M, Keator D, Li X, Michael Z, Maumet C, Nichols BN, Nichols TE, Pellman J, Poline JB, Rokem A, Schaefer G, Sochat V, Triplett W, Turner JA, Varoquaux G, Poldrack RA (2016) The brain imaging data structure, a format for organizing and describing outputs of neuroimaging experiments. *Scientific Data* 3:sdata201644, DOI 10.1038/sdata.2016.44
- [21] Penny WD, Friston KJ, Ashburner JT, Kiebel SJ, Nichols TE (2011) *Statistical parametric mapping: the analysis of functional brain images*. Elsevier
- [22] Jenkinson M, Beckmann CF, Behrens TE, Woolrich MW, Smith SM (2012) FSL. *NeuroImage* 62(2):782–790, DOI 10.1016/j.neuroimage.2011.09.015
- [23] Fischl B (2012) Freesurfer. *NeuroImage* 62(2):774–781, DOI 10.1016/j.neuroimage.2012.01.021
- [24] Avants BB, Tustison N, Song G (2009) Advanced normalization tools (ANTS). *The Insight Journal* 2(365):1–35, DOI 10.54294/uvnhin
- [25] Tournier JD, Calamante F, Connelly A (2012) MRtrix: diffusion tractography in crossing fiber regions. *International Journal of Imaging Systems and Technology* 22(1):53–66, DOI 10.1002/ima.22005
- [26] Cox RW (1996) AFNI: software for analysis and visualization of functional magnetic resonance neuroimages. *Computers and Biomedical Research* 29(3):162–173, DOI 10.1006/cbmr.1996.0014
- [27] Gorgolewski KJ, Alfaro-Almagro F, Auer T, Bellec P, Capotă M, Chakravarty MM, Churchill NW, Cohen AL, Craddock RC, Devenyi GA, Eklund A, Esteban O, Flandin G, Ghosh SS, Guntupalli JS, Jenkinson M, Keshavan A, Kiar G, Liem F, Raamana PR, Raffelt D, Steele CJ, Quirion PO, Smith RE, Strother SC, Varoquaux G, Wang Y, Yarkoni T, Poldrack RA (2017) BIDS apps: Improving ease of use, accessibility, and reproducibility of neuroimaging data analysis methods. *PLoS Computational Biology* 13(3):1–16, DOI 10.1371/journal.pcbi.1005209
- [28] Abraham A, Pedregosa F, Eickenberg M, Gervais P, Mueller A, Kossaifi J, Gramfort A, Thirion B, Varoquaux G (2014) Machine learning for neuroimaging with scikit-learn. *Frontiers in neuroinformatics* 8:14, DOI 10.3389/fninf.2014.00014
- [29] Routier A, Burgos N, Díaz M, Bacci M, Bottani S, El-Rifai O, Fontanella S, Gori P, Guillon J, Guyot A, Hassanaly R, Jacquemont T, Lu P, Marcoux A, Moreau T, Samper-González J, Teichmann M, Thibeau-Sutre E, Vaillant G, Wen J, Wild A, Habert MO, Durrleman S, Colliot O (2021) Clinica: An Open-Source Software Platform for Reproducible Clinical Neuroscience Studies. *Frontiers in Neuroinformatics* 15:39, DOI 10.3389/fninf.2021.689675
- [30] Pérez-García F, Sparks R, Ourselin S (2021) TorchIO: a Python library for efficient loading, preprocessing, augmentation and patch-based sampling of medical images in deep learning. *Computer Methods and Programs in Biomedicine* 208:106236, DOI 10.1016/j.cmpb.2021.106236
- [31] Thibeau-Sutre E, Díaz M, Hassanaly R, Routier A, Dormont D, Colliot O, Burgos N (2022) ClinicaDL: An open-source deep learning software for reproducible neuroimaging processing. *Computer Methods and Programs in Biomedicine* 220:106818, DOI 10.1016/j.cmpb.2022.106818
- [32] Commowick O, Istace A, Kain M, Laurent B, Leray F, Simon M, Pop SC, Girard P, Améli R, Ferré JC, Kerbrat A, Tourdias T, Cervenansky F, Glatard T, Beaumont J, Doyle S, Forbes F, Knight J, Khademi A, Mahbod A, Wang C, McKinley R, Wagner F, Muschelli J, Sweeney E, Roura E, Lladó X, Santos MM, Santos WP, Silva-Filho AG, Tomas-Fernandez X, Urien H, Bloch I, Valverde S, Cabezas M, Vera-Olmos FJ, Malpica N, Guttmann C, Vukusic S, Edan G, Dojat M, Styner M, Warfield SK, Cotton F, Barillot C (2018) Objective Evaluation of Multiple Sclerosis Lesion Segmentation using a Data Management and Processing Infrastructure. *Scientific Reports* 8(1):13650, DOI 10.1038/s41598-018-31911-7
- [33] Commowick O, Kain M, Casey R, Ameli R, Ferré JC, Kerbrat A, Tourdias T, Cervenansky F, Camarasu-Pop S, Glatard T, Vukusic S, Edan G, Barillot C, Dojat M, Cotton F (2021) Multiple sclerosis lesions segmentation from multiple

- experts: The MICCAI 2016 challenge dataset. *NeuroImage* 244:118589, DOI 10.1016/j.neuroimage.2021.118589
- [34] Tustison NJ, Avants BB, Cook PA, Zheng Y, Egan A, Yushkevich PA, Gee JC (2010) N4ITK: Improved N3 Bias Correction. *IEEE Transactions on Medical Imaging* 29(6):1310–1320, DOI 10.1109/TMI.2010.2046908
- [35] Nyúl LG, Udupa JK, Zhang X (2000) New variants of a method of mri scale standardization. *IEEE Transactions on Medical Imaging* 19(2):143–150, DOI 10.1109/42.836373
- [36] Kalavathi P, Prasath V (2016) Methods on skull stripping of MRI head scan images—a review. *Journal of Digital Imaging* 29(3):365–379, DOI 10.1007/s10278-015-9847-8
- [37] Shattuck DW, Leahy RM (2002) BrainSuite: an automated cortical surface identification tool. *Medical Image Analysis* 6(2):129–142, DOI 10.1016/S1361-8415(02)00054-3
- [38] Isensee F, Schell M, Pflueger I, Brugnara G, Bonekamp D, Neuberger U, Wick A, Schlemmer HP, Heiland S, Wick W, et al (2019) Automated brain extraction of multisequence MRI using artificial neural networks. *Human Brain Mapping* 40(17):4952–4964, DOI 10.1002/hbm.24750
- [39] Hoopes A, Mora JS, Dalca AV, Fischl B, Hoffmann M (2022) SynthStrip: skull-stripping for any brain image. *NeuroImage* 260:119474, DOI 10.1016/j.neuroimage.2022.119474
- [40] Oliveira FP, Tavares JMR (2014) Medical image registration: a review. *Computer Methods in Biomechanics and Biomedical Engineering* 17(2):73–93, DOI 10.1080/10255842.2012.670855
- [41] Dora L, Agrawal S, Panda R, Abraham A (2017) State-of-the-art methods for brain tissue segmentation: A review. *IEEE Reviews in Biomedical Engineering* 10:235–249, DOI 10.1109/RBME.2017.2715350
- [42] González-Villà S, Oliver A, Valverde S, Wang L, Zwiggelaar R, Lladó X (2016) A review on brain structures segmentation in magnetic resonance imaging. *Artificial Intelligence in Medicine* 73:45–69, DOI 10.1016/j.artmed.2016.09.001
- [43] Ashburner J, Friston KJ (2000) Voxel-Based Morphometry—The Methods. *NeuroImage* 11(6):805–821, DOI 10.1006/nimg.2000.0582
- [44] Fischl B, Dale AM (2000) Measuring the thickness of the human cerebral cortex from magnetic resonance images. *Proceedings of the National Academy of Sciences* 97(20):11050–11055, DOI 10.1073/pnas.200033797
- [45] He Y, Chen ZJ, Evans AC (2007) Small-world anatomical networks in the human brain revealed by cortical thickness from MRI. *Cerebral cortex* 17(10):2407–2419, DOI 10.1093/cercor/bhl149
- [46] Klöppel S, Stonnington CM, Chu C, Draganski B, Scahill RI, Rohrer JD, Fox NC, Jack Jr CR, Ashburner J, Frackowiak RS (2008) Automatic classification of MR scans in Alzheimer’s disease. *Brain* 131(3):681–689, DOI 10.1093/brain/awm319
- [47] Rathore S, Habes M, Iftikhar MA, Shacklett A, Davatzikos C (2017) A review on neuroimaging-based classification studies and associated feature extraction methods for alzheimer’s disease and its prodromal stages. *NeuroImage* 155:530–548, DOI 10.1016/j.neuroimage.2017.03.057
- [48] Samper-González J, Burgos N, Bottani S, Fontanella S, Lu P, Marcoux A, Routier A, Guillon J, Bacci M, Wen J, Bertrand A, Bertin H, Habert MO, Durrleman S, Evgeniou T, Colliot O (2018) Reproducible evaluation of classification methods in Alzheimer’s disease: Framework and application to MRI and PET data. *NeuroImage* 183:504–521, DOI 10.1016/j.neuroimage.2018.08.042
- [49] Wen J, Thibeau-Sutre E, Diaz-Melo M, Samper-González J, Routier A, Bottani S, Dormont D, Durrleman S, Burgos N, Colliot O (2020) Convolutional neural networks for classification of Alzheimer’s disease: Overview and reproducible evaluation. *Medical Image Analysis* 63:101694, DOI 10.1016/j.media.2020.101694
- [50] Bakas S, Reyes M, Jakab A, ···, Davatzikos C, van Leemput K, Menze B (2018) Identifying the best machine learning algorithms for brain tumor segmentation, progression assessment, and overall survival prediction in the BRATS challenge. *arXiv preprint arXiv:181102629*
- [51] Zeineldin RA, Karar ME, Coburger J, Wirtz CR, Burgert O (2020) DeepSeg:

- Deep neural network framework for automatic brain tumor segmentation using magnetic resonance FLAIR images. *International Journal of Computer Assisted Radiology and Surgery* 15(6):909–920, DOI 10.1007/s11548-020-02186-z
- [52] Sweeney EM, Vogelstein JT, Cuzzocreo JL, Calabresi PA, Reich DS, Crainiceanu CM, Shinohara RT (2014) A comparison of supervised machine learning algorithms and feature vectors for MS lesion segmentation using multimodal structural MRI. *PLoS one* 9(4):e95753, DOI 10.1371/journal.pone.0095753
- [53] La Rosa F, Abdulkadir A, Fartaria MJ, Rahmanzadeh R, Lu P, Galbusera R, Barakovic M, Thiran J, Granziera C, Cuadra MB (2020) Multiple sclerosis cortical and WM lesion segmentation at 3T MRI: A deep learning method based on FLAIR and MP2RAGE. *NeuroImage: Clinical* 27, DOI 10.1016/j.nicl.2020.102335
- [54] Le Bihan D, Breton E, Lallemand D, Grenier P, Cabanis E, Laval-Jeantet M (1986) MR imaging of intravoxel incoherent motions: application to diffusion and perfusion in neurologic disorders. *Radiology* 161(2):401–407
- [55] Tournier JD (2019) Diffusion MRI in the brain—Theory and concepts. *Progress in Nuclear Magnetic Resonance Spectroscopy* 112:1–16, DOI 10.1016/j.pnmrs.2019.03.001
- [56] Tax CM, Bastiani M, Veraart J, Garyfallidis E, Irfanoglu MO (2022) What’s new and what’s next in diffusion MRI preprocessing. *NeuroImage* 249:118830, DOI 10.1016/j.neuroimage.2021.118830
- [57] Soares JM, Marques P, Alves V, Sousa N (2013) A hitchhiker’s guide to diffusion tensor imaging. *Frontiers in Neuroscience* 7:31, DOI 10.3389/fnins.2013.00031
- [58] Jeurissen B, Descoteaux M, Mori S, Leemans A (2019) Diffusion MRI fiber tractography of the brain. *NMR in Biomedicine* 32(4):e3785, DOI 10.1002/nbm.3785
- [59] Zhang H, Schneider T, Wheeler-Kingshott CA, Alexander DC (2012) NODDI: practical in vivo neurite orientation dispersion and density imaging of the human brain. *NeuroImage* 61(4):1000–1016, DOI 10.1016/j.neuroimage.2012.03.072
- [60] Maggipinto T, Bellotti R, Amoroso N, Diacono D, Donvito G, Lella E, Monaco A, Scelsi MA, Tangaro S (2017) DTI measurements for Alzheimer’s classification. *Physics in Medicine & Biology* 62(6):2361, DOI 10.1088/1361-6560/aa5dbe
- [61] Wen J, Samper-González J, Bottani S, Routier A, Burgos N, Jacquemont T, Fontanella S, Durrleman S, Epelbaum S, Bertrand A, Colliot O (2021) Reproducible evaluation of diffusion MRI features for automatic classification of patients with Alzheimer’s disease. *Neuroinformatics* 19(1):57–78, DOI /10.1007/s12021-020-09469-5
- [62] Park YW, Oh J, You SC, Han K, Ahn SS, Choi YS, Chang JH, Kim SH, Lee SK (2019) Radiomics and machine learning may accurately predict the grade and histological subtype in meningiomas using conventional and diffusion tensor imaging. *European Radiology* 29(8):4068–4076, DOI 10.1007/s00330-018-5830-3
- [63] Glover GH (2011) Overview of functional magnetic resonance imaging. *Neurosurgery Clinics* 22(2):133–139, DOI 10.1016/j.nec.2010.11.001
- [64] Fox MD, Raichle ME (2007) Spontaneous fluctuations in brain activity observed with functional magnetic resonance imaging. *Nature Reviews Neuroscience* 8(9):700–711, DOI 10.1038/nrn2201
- [65] Esteban O, Markiewicz CJ, Blair RW, Moodie CA, Isik AI, Erramuzpe A, Kent JD, Goncalves M, DuPre E, Snyder M, Oya H, Ghosh SS, Wright J, Durnez J, Poldrack RA, Gorgolewski KJ (2019) fMRIPrep: A robust preprocessing pipeline for functional MRI. *Nature Methods* 16(1):111–116, DOI 10.1038/s41592-018-0235-4
- [66] Khosla M, Jamison K, Ngo GH, Kuceyeski A, Sabuncu MR (2019) Machine learning in resting-state fMRI analysis. *Magnetic Resonance Imaging* 64:101–121, DOI 10.1016/j.mri.2019.05.031
- [67] Fischl B, Sereno MI, Tootell RB, Dale AM (1999) High-resolution intersubject averaging and a coordinate system for the cortical surface. *Human brain mapping* 8(4):272–284, DOI 10.1002/(SICI)1097-0193(1999)8:4<272::AID-HBM10>3.0.CO;2-4
- [68] Kim J, Calhoun VD, Shim E, Lee JH (2016) Deep neural network with weight sparsity control and pre-training extracts

- hierarchical features and enhances classification performance: Evidence from whole-brain resting-state functional connectivity patterns of schizophrenia. *NeuroImage* 124:127–146, DOI 10.1016/j.neuroimage.2015.05.018
- [69] Rashid B, Arbabshirani MR, Damaraju E, Cetin MS, Miller R, Pearlson GD, Calhoun VD (2016) Classification of schizophrenia and bipolar patients using static and dynamic resting-state fMRI brain connectivity. *NeuroImage* 134:645–657, DOI 10.1016/j.neuroimage.2016.04.051
- [70] Wannamaker R, Buck B, Butcher K (2019) Multimodal CT in Acute Stroke. *Current Neurology and Neuroscience Reports* 19(9):63, DOI 10.1007/s11910-019-0978-z
- [71] Muschelli J (2019) Recommendations for Processing Head CT Data. *Frontiers in Neuroinformatics* 13, DOI 10.3389/fninf.2019.00061
- [72] Chourmouzi D, Papadopoulou E, Marias K, Drevelegas A (2014) Imaging of Brain Tumors. *Surgical Oncology Clinics* 23(4):629–684, DOI 10.1016/j.soc.2014.07.004
- [73] Yeo M, Tahayori B, Kok HK, Maingard J, Kutaiba N, Russell J, Thijs V, Jhamb A, Chandra RV, Brooks M, Barras CD, Asadi H (2021) Review of deep learning algorithms for the automatic detection of intracranial hemorrhages on computed tomography head imaging. *Journal of NeuroInterventional Surgery* 13(4):369–378, DOI 10.1136/neurintsurg-2020-017099
- [74] Buchlak QD, Milne MR, Seah J, Johnson A, Samarasinghe G, Hachey B, Esmaili N, Tran A, Leveque JC, Farrokhi F, Goldschlager T, Edelstein S, Brotchie P (2022) Charting the potential of brain computed tomography deep learning systems. *Journal of Clinical Neuroscience* 99:217–223, DOI 10.1016/j.jocn.2022.03.014
- [75] Ye H, Gao F, Yin Y, Guo D, Zhao P, Lu Y, Wang X, Bai J, Cao K, Song Q, Zhang H, Chen W, Guo X, Xia J (2019) Precise diagnosis of intracranial hemorrhage and subtypes using a three-dimensional joint convolutional and recurrent neural network. *European Radiology* 29(11):6191–6201, DOI 10.1007/s00330-019-06163-2
- [76] Clerigues A, Valverde S, Bernal J, Freixenet J, Oliver A, Lladó X (2019) Acute ischemic stroke lesion core segmentation in CT perfusion images using fully convolutional neural networks. *Computers in Biology and Medicine* 115:103487, DOI 10.1016/j.combiomed.2019.103487
- [77] Hooker JM, Carson RE (2019) Human positron emission tomography neuroimaging. *Annual review of biomedical engineering* 21:551–581, DOI 10.1146/annurev-bioeng-062117-121056
- [78] Heurling K, Leuzy A, Jonasson M, Frick A, Zimmer ER, Nordberg A, Lubberink M (2017) Quantitative positron emission tomography in brain research. *Brain research* 1670:220–234, DOI 10.1016/j.brainres.2017.06.022
- [79] Guedj E, Varrone A, Boellaard R, Albert NL, Barthel H, van Berckel B, Brendel M, Cecchin D, Ekmekcioglu O, Garibotto V, Lammertsma AA, Law I, Peñuelas I, Semah F, Traub-Weidinger T, van de Giessen E, Van Weehaeghe D, Morbelli S (2022) EANM procedure guidelines for brain PET imaging using [18F]FDG, version 3. *European Journal of Nuclear Medicine and Molecular Imaging* 49(2):632–651, DOI 10.1007/s00259-021-05603-w
- [80] Cho H, Choi JY, Hwang MS, Kim YJ, Lee HM, Lee HS, Lee JH, Ryu YH, Lee MS, Lyoo CH (2016) In vivo cortical spreading pattern of tau and amyloid in the Alzheimer disease spectrum. *Annals of Neurology* 80(2):247–258, DOI 10.1002/ana.24711
- [81] Stankoff B, Freeman L, Aigrot MS, Chardain A, Dollé F, Williams A, Galanaud D, Armand L, Lehericy S, Lubetzki C, et al (2011) Imaging central nervous system myelin by positron emission tomography in multiple sclerosis using [methyl-11C]-2-(4'-methylaminophenyl)-6-hydroxybenzothiazole. *Annals of neurology* 69(4):673–680, DOI 10.1002/ana.22320
- [82] Galldiks N, Lohmann P, Albert NL, Tonn JC, Langen KJ (2019) Current status of pet imaging in neuro-oncology. *Neuro-Oncology Advances* 1(1):vdz010, DOI 10.1093/naajnl/vdz010
- [83] Weiner MW, Veitch DP, Aisen PS, Beckett LA, Cairns NJ, Green RC, Harvey D, Jack CR, Jagust W, Morris JC, Petersen RC, Salazar J, Saykin AJ, Shaw LM, Toga AW, Trojanowski JQ (2017) The Alzheimer's Disease Neuroimaging Initiative 3: Continued innovation for clinical trial improvement. *Alzheimer's & Dementia* 13(5):561–571, DOI 10.1016/j.jalz.2016.10.006

- [84] López-González FJ, Silva-Rodríguez J, Paredes-Pacheco J, Niñerola-Baizán A, Efthimiou N, Martín-Martín C, Moscoso A, Ruibal Á, Roé-Vellvé N, Aguiar P (2020) Intensity normalization methods in brain fdg-pet quantification. *Neuroimage* 222:117229, DOI 10.1016/j.neuroimage.2020.117229
- [85] Erlandsson K, Buvat I, Pretorius PH, Thomas BA, Hutton BF (2012) A review of partial volume correction techniques for emission tomography and their applications in neurology, cardiology and oncology. *Physics in Medicine and Biology* 57(21):R119, DOI 10.1088/0031-9155/57/21/R119
- [86] Thomas BA, Cuplov V, Bousse A, Mendes A, Thielemans K, Hutton BF, Erlandsson K (2016) PETPVC: A toolbox for performing partial volume correction techniques in positron emission tomography. *Physics in Medicine and Biology* 61(22):7975–7993, DOI 10.1088/0031-9155/61/22/7975
- [87] Della Rosa PA, Cerami C, Gallivanone F, Prestia A, Caroli A, Castiglioni I, Gilaridi MC, Frisoni G, Friston K, Ashburner J, Perani D (2014) A Standardized 18F-FDG-PET Template for Spatial Normalization in Statistical Parametric Mapping of Dementia. *Neuroinformatics* 12(4):575–593, DOI 10.1007/s12021-014-9235-4
- [88] Marcoux A, Burgos N, Bertrand A, Teichmann M, Routier A, Wen J, Samper-González J, Bottani S, Durrleman S, Habert MO, Colliot O (2018) An Automated Pipeline for the Analysis of PET Data on the Cortical Surface. *Frontiers in Neuroinformatics* 12, DOI 10.3389/fninf.2018.00094
- [89] Yakushev I, Drzezga A, Habeck C (2017) Metabolic connectivity: methods and applications. *Current opinion in neurology* 30(6):677–685, DOI 10.1097/WCO.0000000000000494
- [90] Duffy IR, Boyle AJ, Vasdev N (2019) Improving PET imaging acquisition and analysis with machine learning: a narrative review with focus on Alzheimer’s disease and oncology. *Molecular imaging* 18:1536012119869070, DOI 10.1177/1536012119869070
- [91] Gray KR, Wolz R, Heckemann RA, Aljabar P, Hammers A, Rueckert D, Initiative ADN, et al (2012) Multi-region analysis of longitudinal FDG-PET for the classification of Alzheimer’s disease. *NeuroImage* 60(1):221–229, DOI 10.1016/j.neuroimage.2011.12.071
- [92] Lu D, Popuri K, Ding GW, Balachandar R, Beg MF (2018) Multiscale deep neural network based analysis of FDG-PET images for the early diagnosis of Alzheimer’s disease. *Medical Image Analysis* 46:26–34, DOI 10.1016/j.media.2018.02.002
- [93] Higdon R, Foster NL, Koeppe RA, DeCarli CS, Jagust WJ, Clark CM, Barbas NR, Arnold SE, Turner RS, Heidebrink JL, Minoshima S (2004) A comparison of classification methods for differentiating frontotemporal dementia from Alzheimer’s disease using FDG-PET imaging. *Statistics in medicine* 23(2):315–326, DOI 10.1002/sim.1719
- [94] Papp L, Pötsch N, Grahovac M, Schmidbauer V, Woehrer A, Preusser M, Mitterhauser M, Kiesel B, Wadsak W, Beyer T, et al (2018) Glioma survival prediction with combined analysis of in vivo 11C-MET PET features, ex vivo features, and patient features by supervised machine learning. *Journal of Nuclear Medicine* 59(6):892–899, DOI 10.2967/jnumed.117.202267
- [95] Hotta M, Minamimoto R, Miwa K (2019) 11C-methionine-PET for differentiating recurrent brain tumor from radiation necrosis: radiomics approach with random forest classifier. *Scientific reports* 9(1):1–7, DOI 10.1038/s41598-019-52279-2
- [96] Accorsi R (2008) Brain Single-Photon Emission CT Physics Principles. *American Journal of Neuroradiology* 29(7):1247–1256, DOI 10.3174/ajnr.A1175
- [97] Kapucu ÖL, Nobili F, Varrone A, Booi J, Vander Borgh T, Nägren K, Darcourt J, Tatsch K, Van Laere KJ (2009) EANM procedure guideline for brain perfusion SPECT using 99mTc-labelled radiopharmaceuticals, version 2. *European Journal of Nuclear Medicine and Molecular Imaging* 36(12):2093, DOI 10.1007/s00259-009-1266-y
- [98] Morbelli S, Esposito G, Arbizu J, Barthel H, Boellaard R, Bohnen NI, Brooks DJ, Darcourt J, Dickson JC, Douglas D, Drzezga A, Dubroff J, Ekmekcioglu O, Garibotto V, Herscovitch P, Kuo P, Lammertsma A, Pappata S, Peñuelas I, Seibyl J, Semah F, Tossici-Bolt L, Van de Giessen E, Van Laere K, Varrone A, Wanner M, Zubal G, Law I (2020) EANM practice guideline/SNMMI procedure standard for dopaminergic imaging in Parkinsonian syndromes 1.0. *European Journal of Nuclear Medicine and Molecular Imaging* 47(8):1885–1912, DOI 10.1007/s00259-020-04817-8

- [99] Yeo JM, Lim X, Khan Z, Pal S (2013) Systematic review of the diagnostic utility of SPECT imaging in dementia. *European Archives of Psychiatry and Clinical Neuroscience* 263(7):539–552, DOI 10.1007/s00406-013-0426-z
- [100] McNally KA, Paige AL, Varghese G, Zhang H, Novotny Jr EJ, Spencer SS, Zubal IG, Blumenfeld H (2005) Localizing value of ictal-interictal SPECT analyzed by SPM (ISAS). *Epilepsia* 46(9):1450–1464, DOI 10.1111/j.1528-1167.2005.06705.x
- [101] Marek K, Chowdhury S, Siderowf A, Lasch S, Coffey CS, Caspell-Garcia C, Simuni T, Jennings D, Tanner CM, Trojanowski JQ, Shaw LM, Seibyl J, Schuff N, Singleton A, Kieburtz K, Toga AW, Mollenhauer B, Galasko D, Chahine LM, Weintraub D, Foroud T, Tosun-Turgut D, Poston K, Arnedo V, Frasier M, Sherer T (2018) The Parkinson’s progression markers initiative (PPMI) – establishing a PD biomarker cohort. *Annals of Clinical and Translational Neurology* 5(12):1460–1477, DOI 10.1002/acn3.644
- [102] Khachnaoui H, Mabrouk R, Khelifa N (2020) Machine learning and deep learning for clinical data and PET/SPECT imaging in Parkinson’s disease: A review. *IET Image Processing* 14(16):4013–4026, DOI 10.1049/iet-ipr.2020.1048
- [103] Prashanth R, Roy SD, Mandal PK, Ghosh S (2014) Automatic classification and prediction models for early Parkinson’s disease diagnosis from SPECT imaging. *Expert Systems with Applications* 41(7):3333–3342, DOI 10.1016/j.eswa.2013.11.031
- [104] Choi H, Ha S, Im HJ, Paek SH, Lee DS (2017) Refining diagnosis of parkinson’s disease with deep learning-based interpretation of dopamine transporter imaging. *NeuroImage: Clinical* 16:586–594, DOI 10.1016/j.nicl.2017.09.010
- [105] Rahmim A, Huang P, Shenkov N, Foutouhi S, Davoodi-Bojd E, Lu L, Mari Z, Soltanian-Zadeh H, Sossi V (2017) Improved prediction of outcome in Parkinson’s disease using radiomics analysis of longitudinal DAT SPECT images. *NeuroImage: Clinical* 16:539–544, DOI 10.1016/j.nicl.2017.08.021
- [106] Fung G, Stoeckel J (2007) Svm feature selection for classification of spect images of alzheimer’s disease using spatial information. *Knowledge and Information Systems* 11(2):243–258, DOI 10.1007/s10115-006-0043-5
- [107] Górriz J, Segovia F, Ramírez J, Lassl A, Salas-Gonzalez D (2011) GMM based SPECT image classification for the diagnosis of Alzheimer’s disease. *Applied Soft Computing* 11(2):2313–2325, DOI 10.1016/j.asoc.2010.08.012
- [108] de Galiza Barbosa F, Delso G, Ter Voert E, Huellner M, Herrmann K, Veit-Haibach P (2016) Multi-technique hybrid imaging in PET/CT and PET/MR: what does the future hold? *Clinical Radiology* 71(7):660–672, DOI 10.1016/j.crad.2016.03.013