

# A new vessel-based method to estimate automatically the position of the non-functional fovea on altered retinography from maculopathies

Calabrèse Aurélie<sup>1,2</sup>, Fournet Vincent<sup>2</sup>, Dours Séverine<sup>1</sup>, Matonti Frédéric<sup>3</sup>, Castet Eric<sup>1</sup>, Kornprobst Pierre<sup>2</sup>

poster #F0085

1. Aix-Marseille University, France.
2. Université Côte d'Azur, Inria, France.
3. Ophthalmology Paradis Monticelli, France.

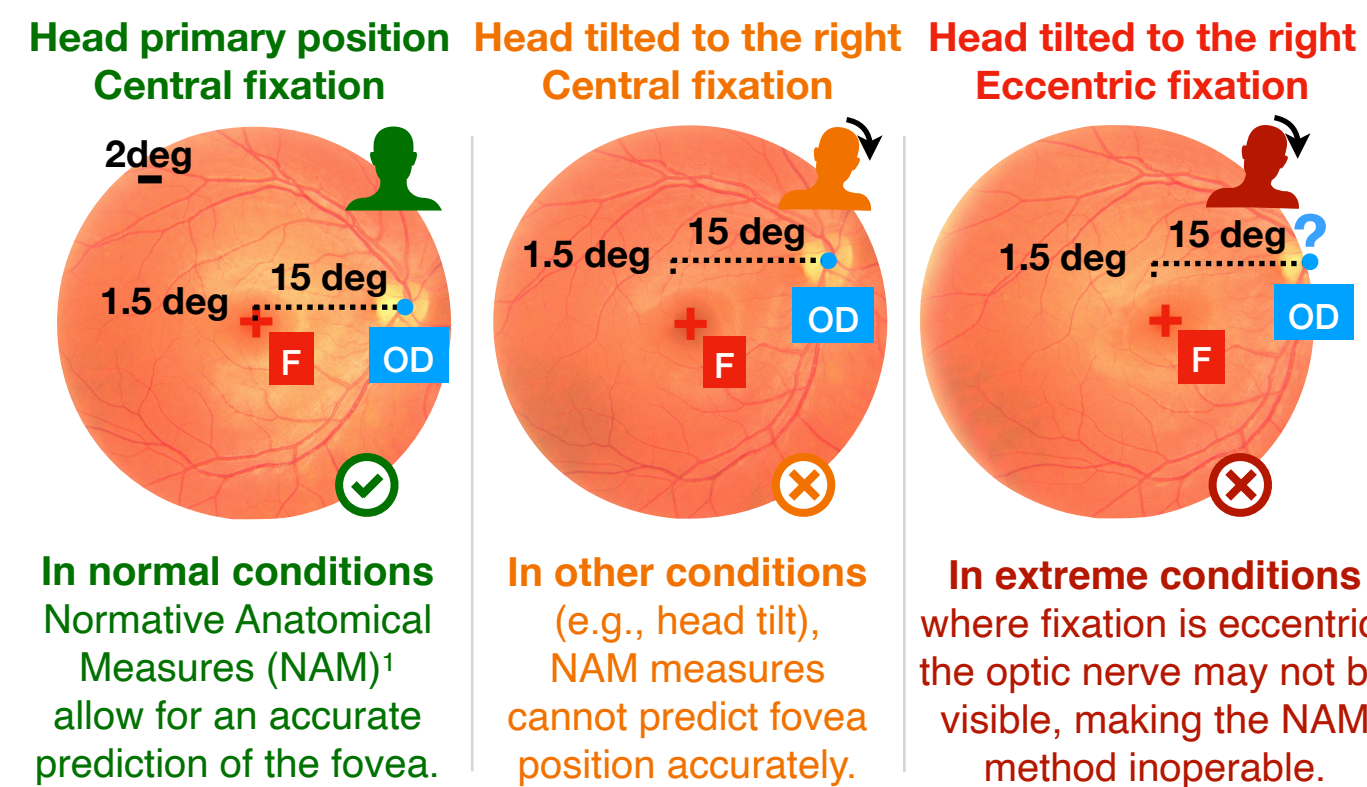


aurelie.calabrese@univ-amu.fr

## Background

- For normal eyes, fundus images show the retina main visible structures:
  - **optic disk OD** → head of the optic nerve,
  - **fovea F** → central and darkest spot of the retina,
  - **vascular structure** branching out from OD.
- Patients with macular lesions, usually develop a new area of fixation: the Preferred Retinal Locus (PRL).

Because fovea-PRL distance allows to better understand the progression and functional impact of maculopathies, the exact position of the former fovea must be estimated precisely in those patients with central field loss.



## Objective

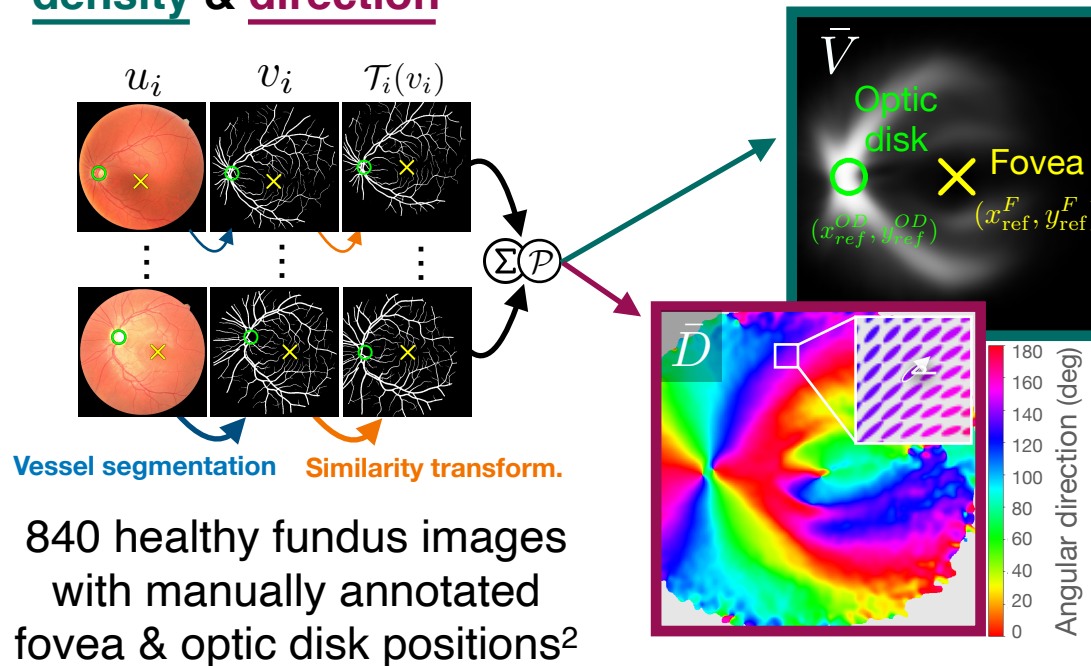
To go beyond current methods of automated fovea detection for normal fundus images and develop a new approach that:

- (1) works efficiently on images with macular lesions,
- (2) using both density & direction of the vascular structure

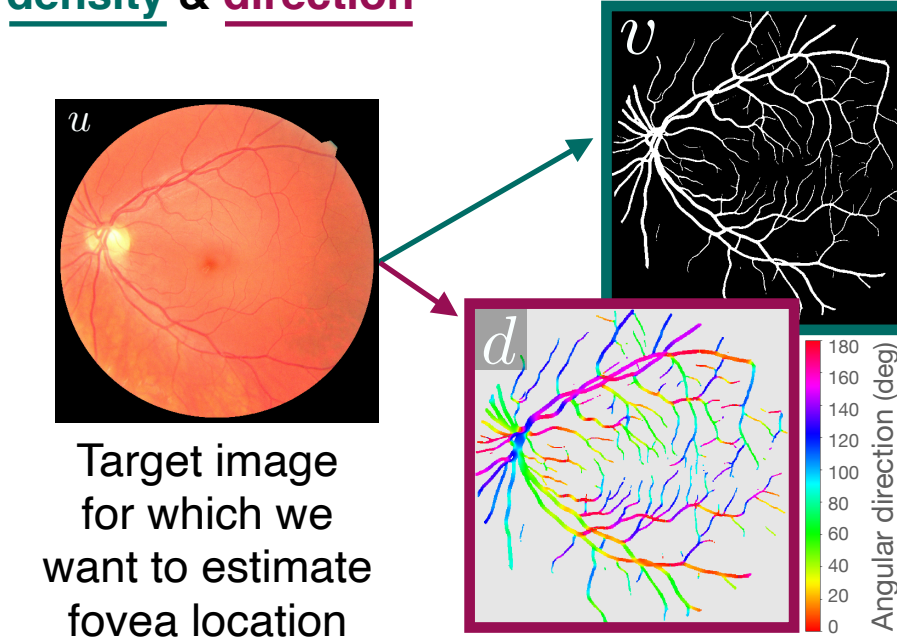
1- Rohrschneider, K. (2004). Determination of the Location of the Fovea on the Fundus. *Investigative Ophthalmology & Visual Science*, 45(9).  
 2- Orlando, J. I., Fu, H., Barbosa Breda, J., et al. (2020). REFUGE Challenge: A unified framework for evaluating automated methods for glaucoma assessment from fundus photographs. *Medical Image Analysis*, 59, 101570.  
 3- Fang, H., Li, F., Fu, H., et al. (2022). ADAM Challenge: Detecting Age-related Macular Degeneration from Fundus Images. *ArXiv:2202.07983*

## Vessel-Based Fovea Localization method (VBFL)

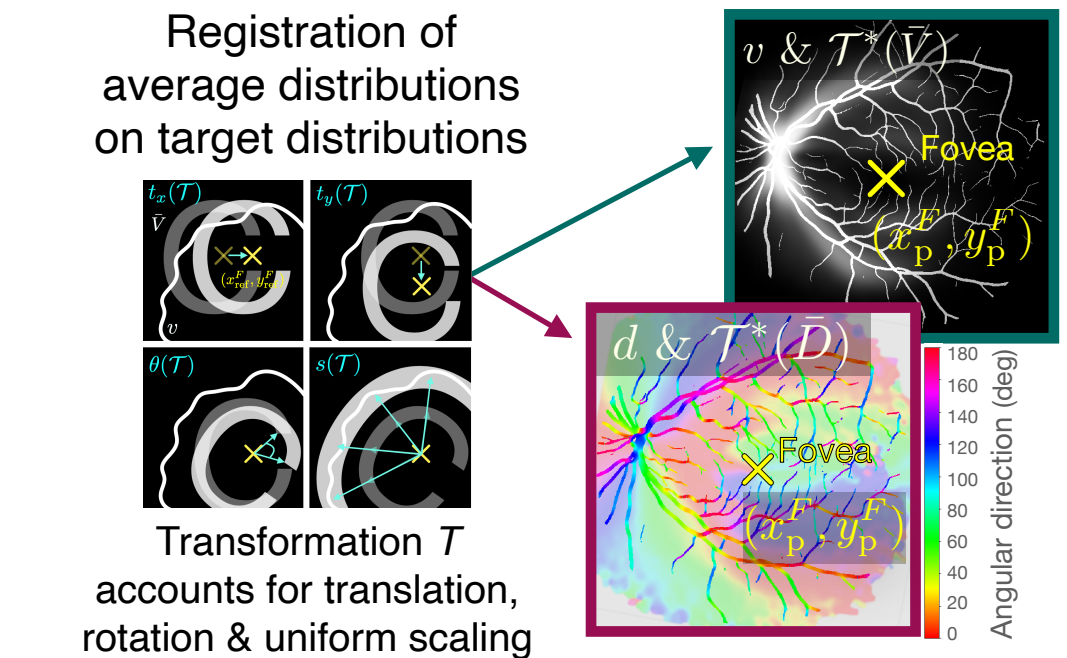
**Step 1: Average representation maps of vessel density & direction**



**Step 2: Target representation maps of vessel density & direction**



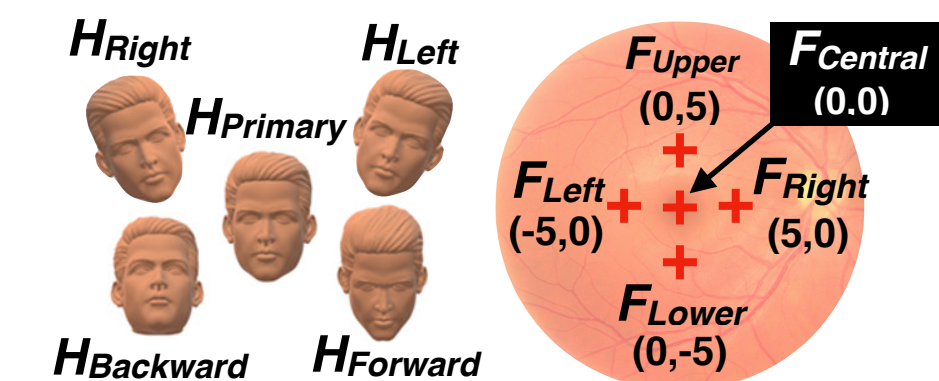
**Step 3: Fovea location prediction**



## Methods

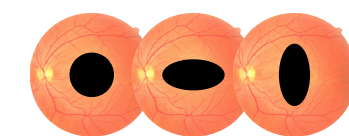
**Healthy fundus images (N = 198)**

- 21 eyes from 19 normally sighted subject
- 10 different fundus images per eye
- 5 head positions x 2 fixation locations



**Images with simulated lesions (N = 3564)**

- 198 healthy images with 18 different lesions
- 3 shapes x 6 sizes (0, 20, 50, 100, 200 & 400 deg<sup>2</sup>)

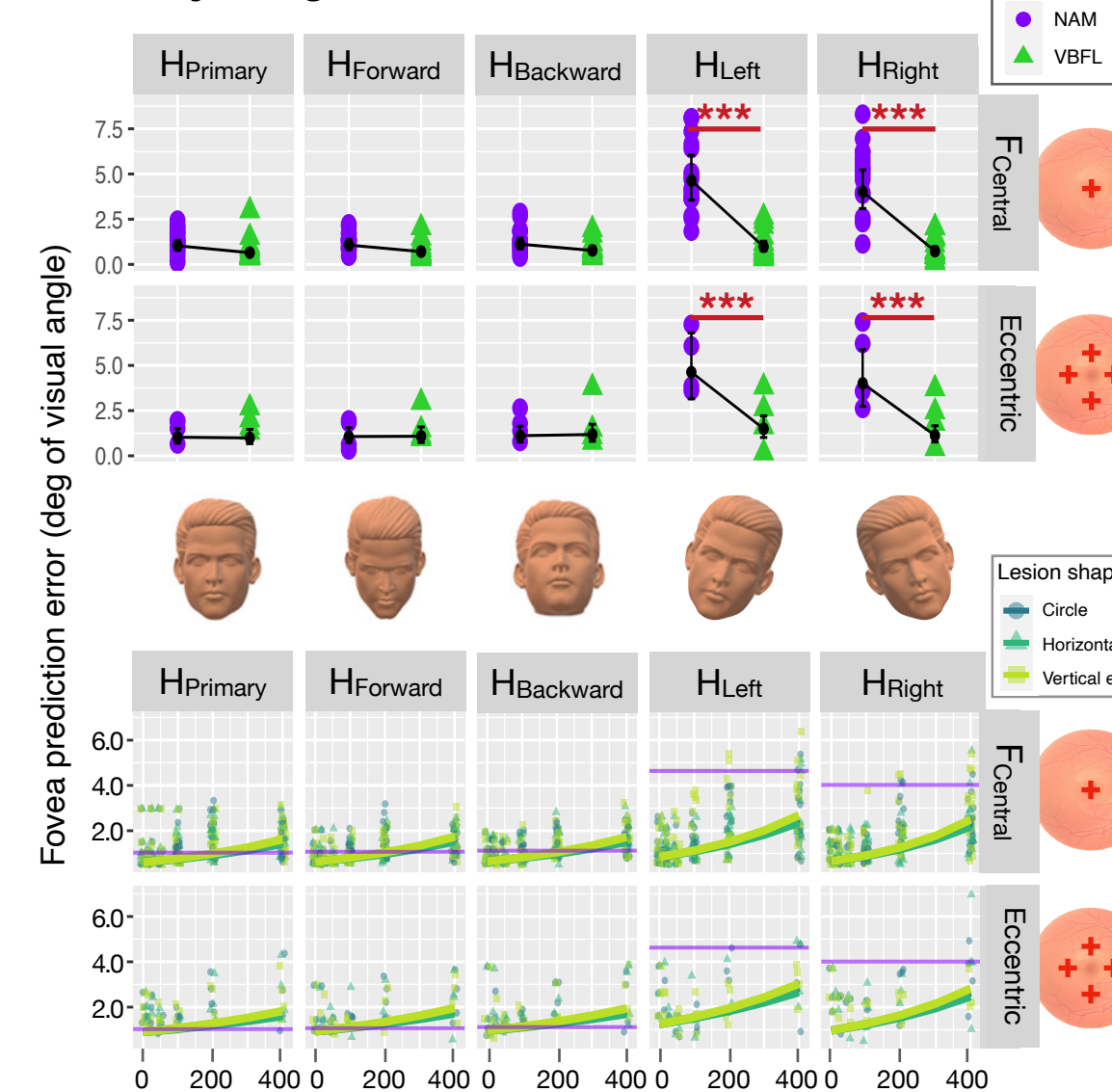


**Pathological images (N = 89)**

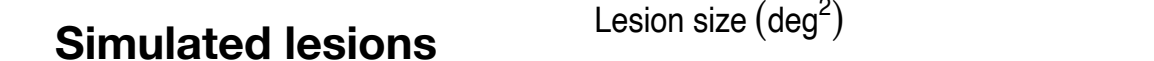- From 89 eyes with AMD, showing drusens, exudates, haemorrhages and/or scars<sup>3</sup>
- Manually annotated fovea position

## Results

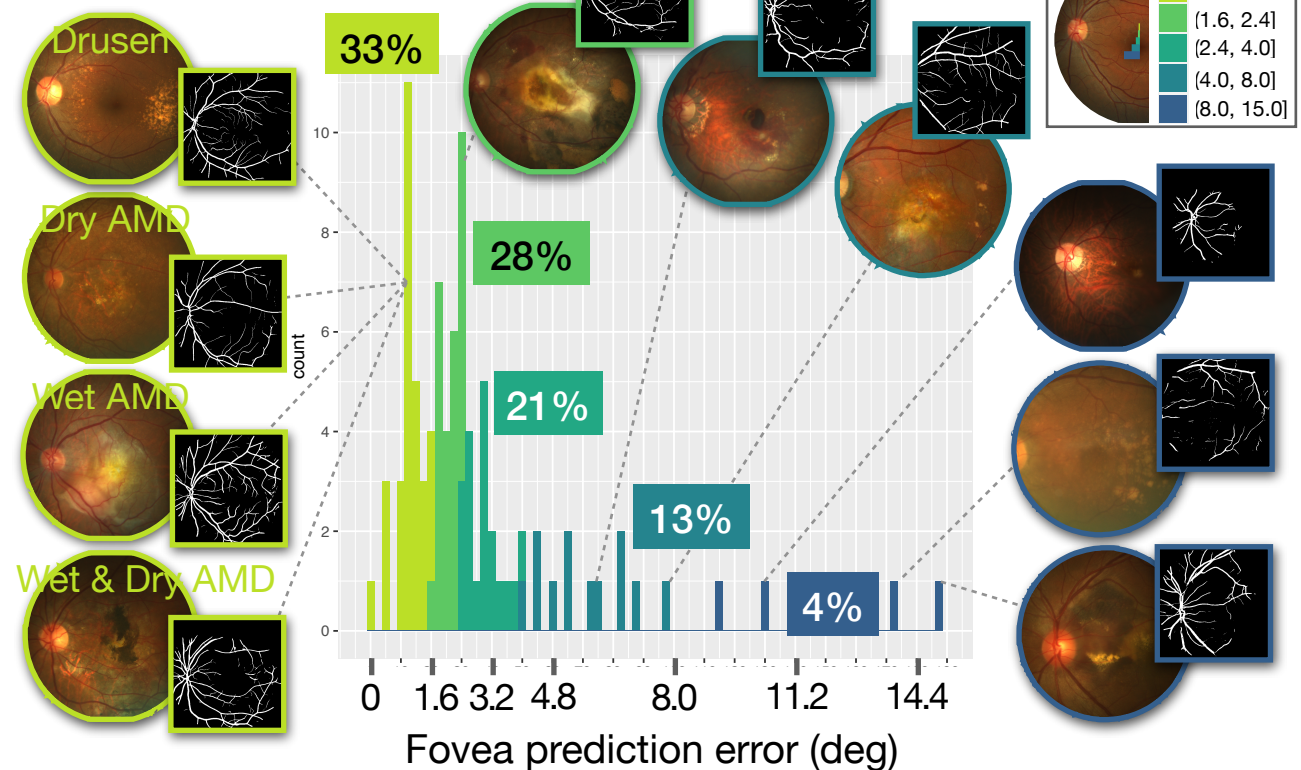
**Healthy images**



**Simulated lesions**



**Pathological images**



## Conclusions

- The VBFL method seems to be more robust to head tilt than the NAM approach, irrespective of fixation location.
- The VBFL method seems to be efficient for macular lesions up to 200 degrees<sup>2</sup>, no matter their shape.
- Relying on the vascular structure may be a valuable asset for further improvement of automated fovea location methods.