



HAL
open science

Anomaly detection in the MRI data of newly diagnosed Parkinsonian patients

Verónica Muñoz Ramírez, Florence Forbes, Alexis Arnaud, Elena Moro,
Michel Dojat

► **To cite this version:**

Verónica Muñoz Ramírez, Florence Forbes, Alexis Arnaud, Elena Moro, Michel Dojat. Anomaly detection in the MRI data of newly diagnosed Parkinsonian patients. 4e congrès de la Société Française de Résonance Magnétique en Biologie et Médecine - SFRMBM 2019, Mar 2019, Strasbourg, France. . hal-02436613

HAL Id: hal-02436613

<https://inria.hal.science/hal-02436613v1>

Submitted on 13 Jan 2020

HAL is a multi-disciplinary open access archive for the deposit and dissemination of scientific research documents, whether they are published or not. The documents may come from teaching and research institutions in France or abroad, or from public or private research centers.

L'archive ouverte pluridisciplinaire **HAL**, est destinée au dépôt et à la diffusion de documents scientifiques de niveau recherche, publiés ou non, émanant des établissements d'enseignement et de recherche français ou étrangers, des laboratoires publics ou privés.

ANOMALY DETECTION IN THE MRI DATA OF NEWLY DIAGNOSED PARKINSONIAN PATIENTS

Muñoz Ramírez, V. ^{1,2}; Forbes, F ²; Arnaud, A. ^{1,2}; Moro, E. ¹; Dojat, M ¹

1. Univ. Grenoble Alpes, Inserm U1216, CHU Grenoble Alpes, Grenoble Institut Neurosciences, 38000 Grenoble, France
2. Univ. Grenoble Alpes, CNRS, Inria, Grenoble INP, LJK Laboratoire Jean Kuntzmann, 38000 Grenoble, France

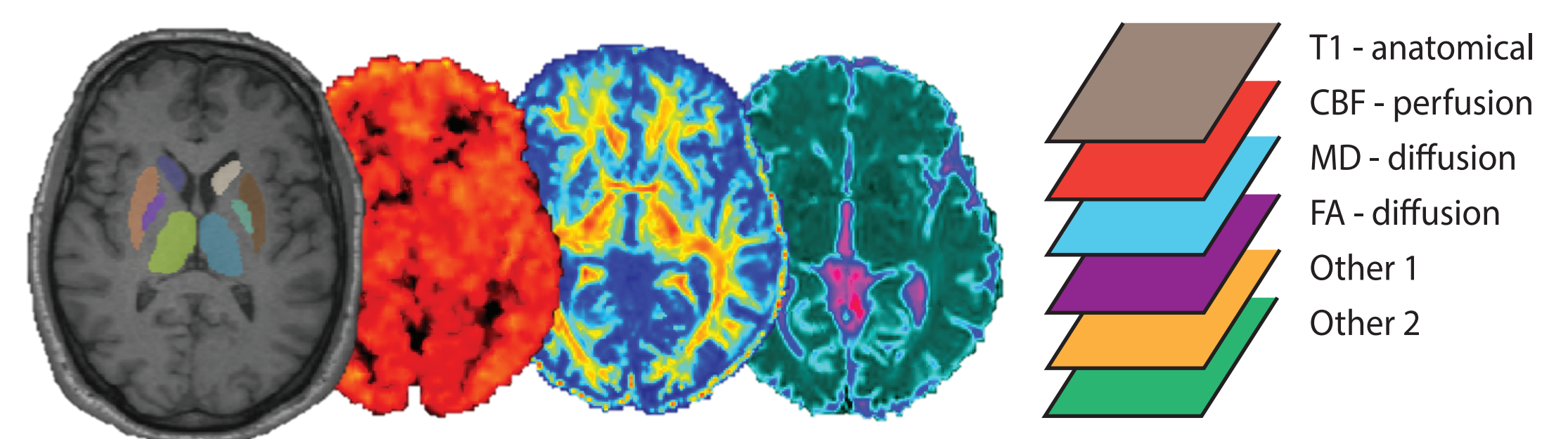
I. Abstract

The putative delay between the onset of **neurodegeneration** and the manifestation of clinical symptoms of **Parkinson's disease** drives the quest to find **biomarkers** present in the pre-motor stages of PD that can lead to earlier diagnosis and more tailored treatments to slow down the disease process.

In this context, our project employs **Magnetic Resonance neuroimaging** and **unsupervised classification** methods to study the interaction of several physiological and structural brain characteristics and ultimately, to draw out specific **signatures** in newly diagnosed Parkinson patients.

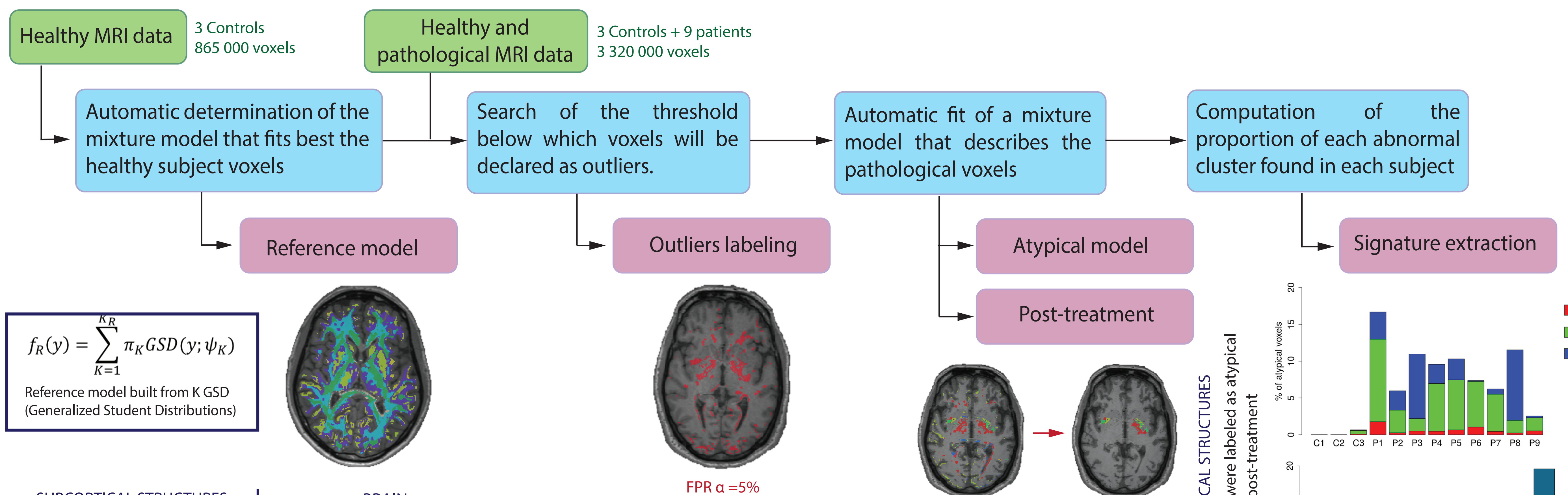
II. MRI parameters extraction

Quantitative features from different MR modalities are extracted and coregistered to an anatomical T1-weighted scan with a subcortical structure mask [1] for each subject. These features currently come from diffusion imaging (**FA, MD**) and perfusion imaging (**CBF**).



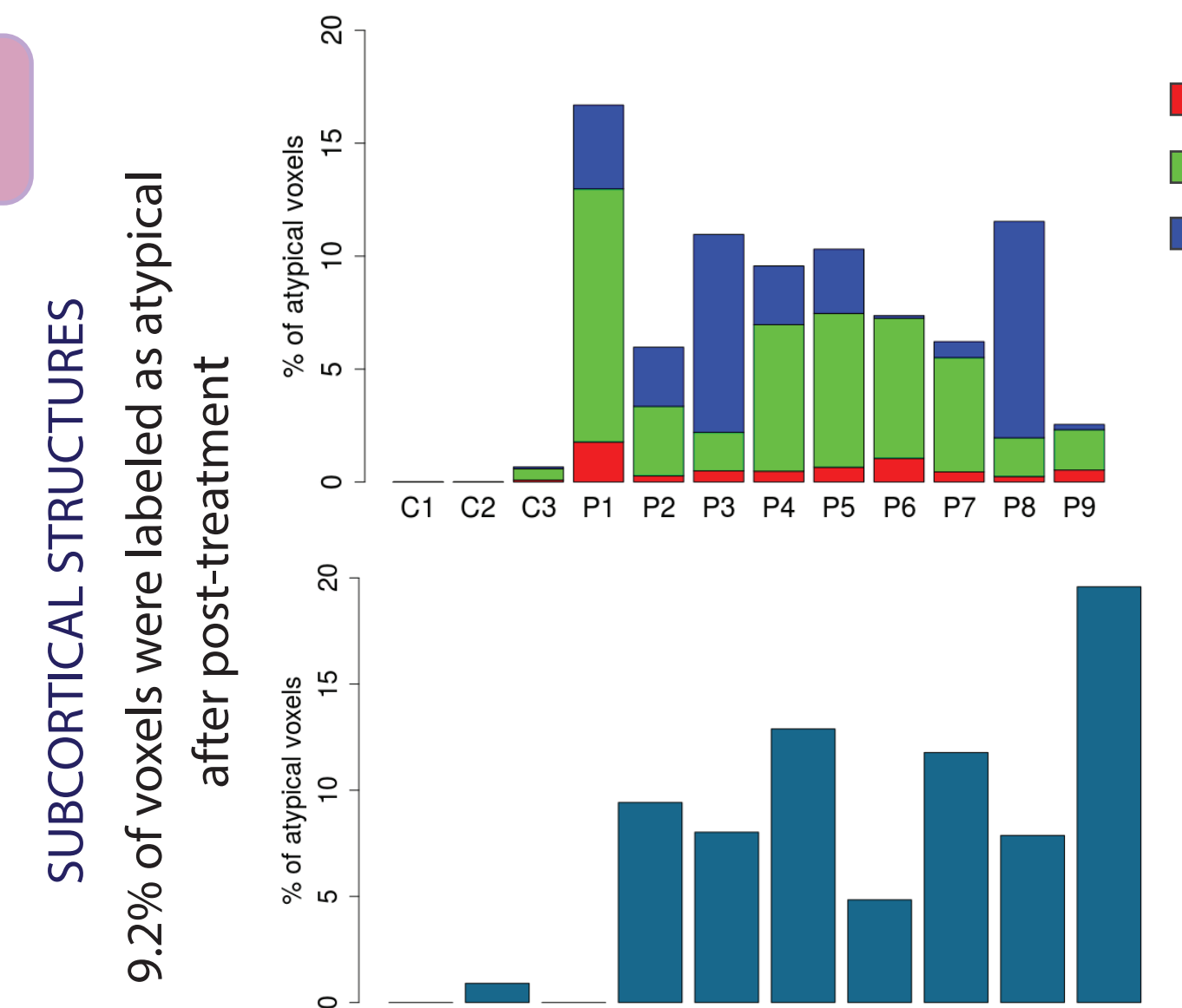
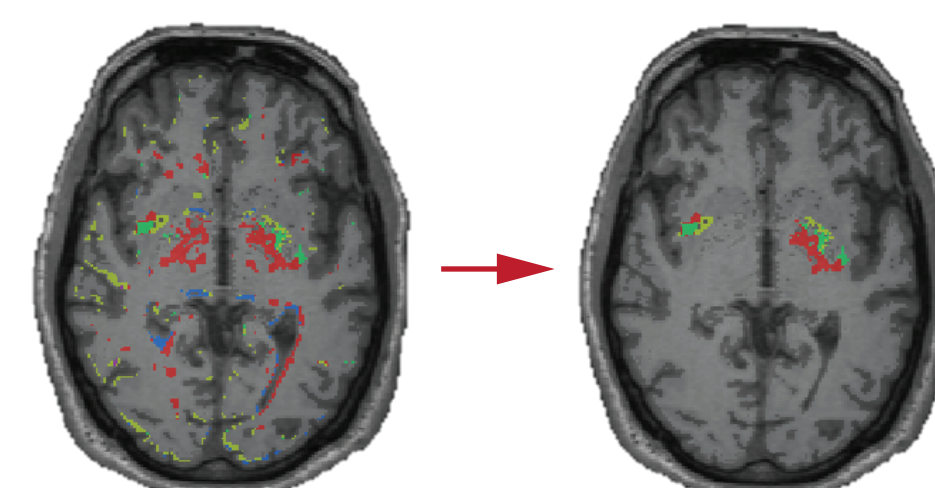
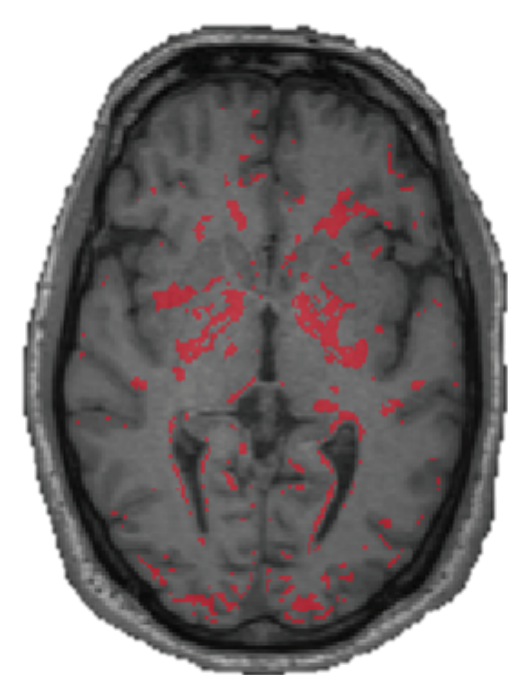
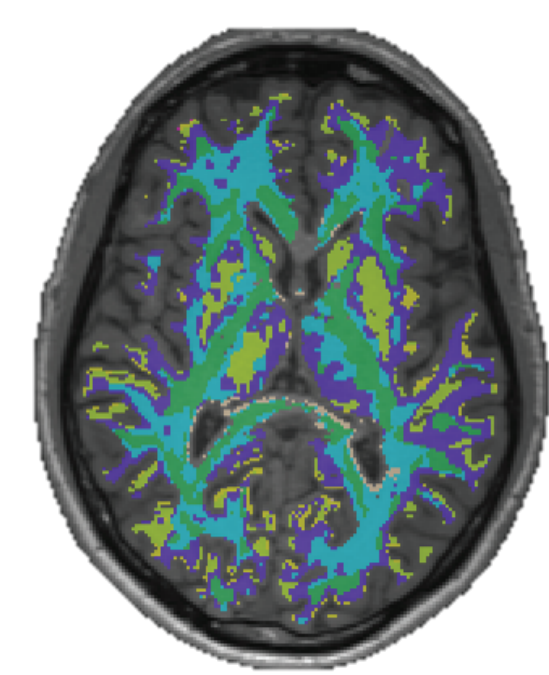
III. Signatures extraction

This method was previously validated by Arnaud & al. [2] to characterize different kinds of brain tumors in rats. The **mixture models** are built from **generalized Student distributions** as they provide a larger variety of distributional shapes compared to the mode standard Gaussian distributions [3].

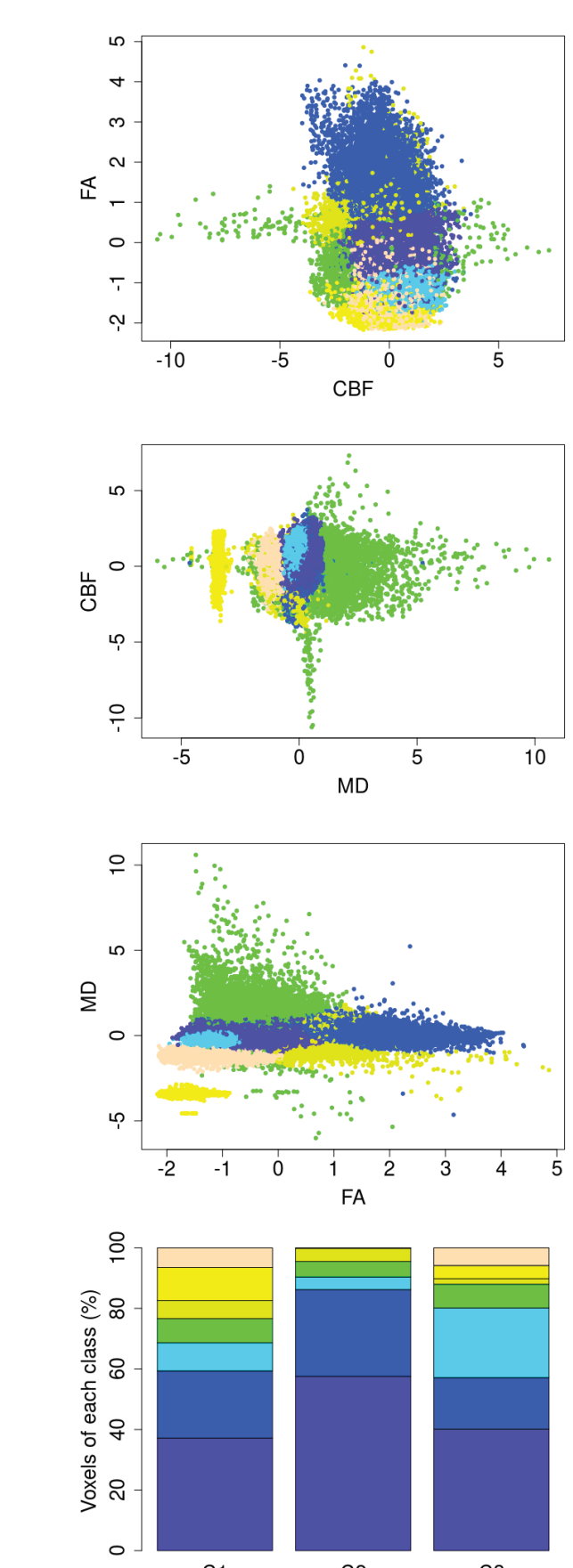


$$f_R(y) = \sum_{K=1}^{K_R} \pi_K GSD(y; \psi_K)$$

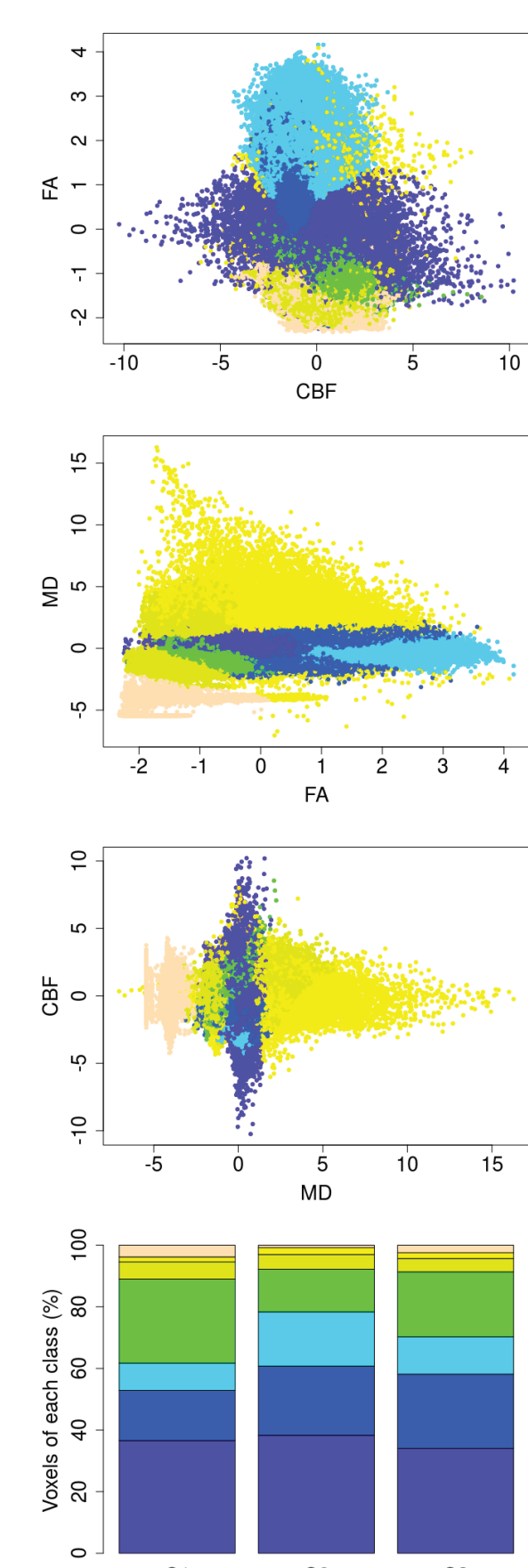
Reference model built from K GSD (Generalized Student Distributions)



SUBCORTICAL STRUCTURES



BRAIN



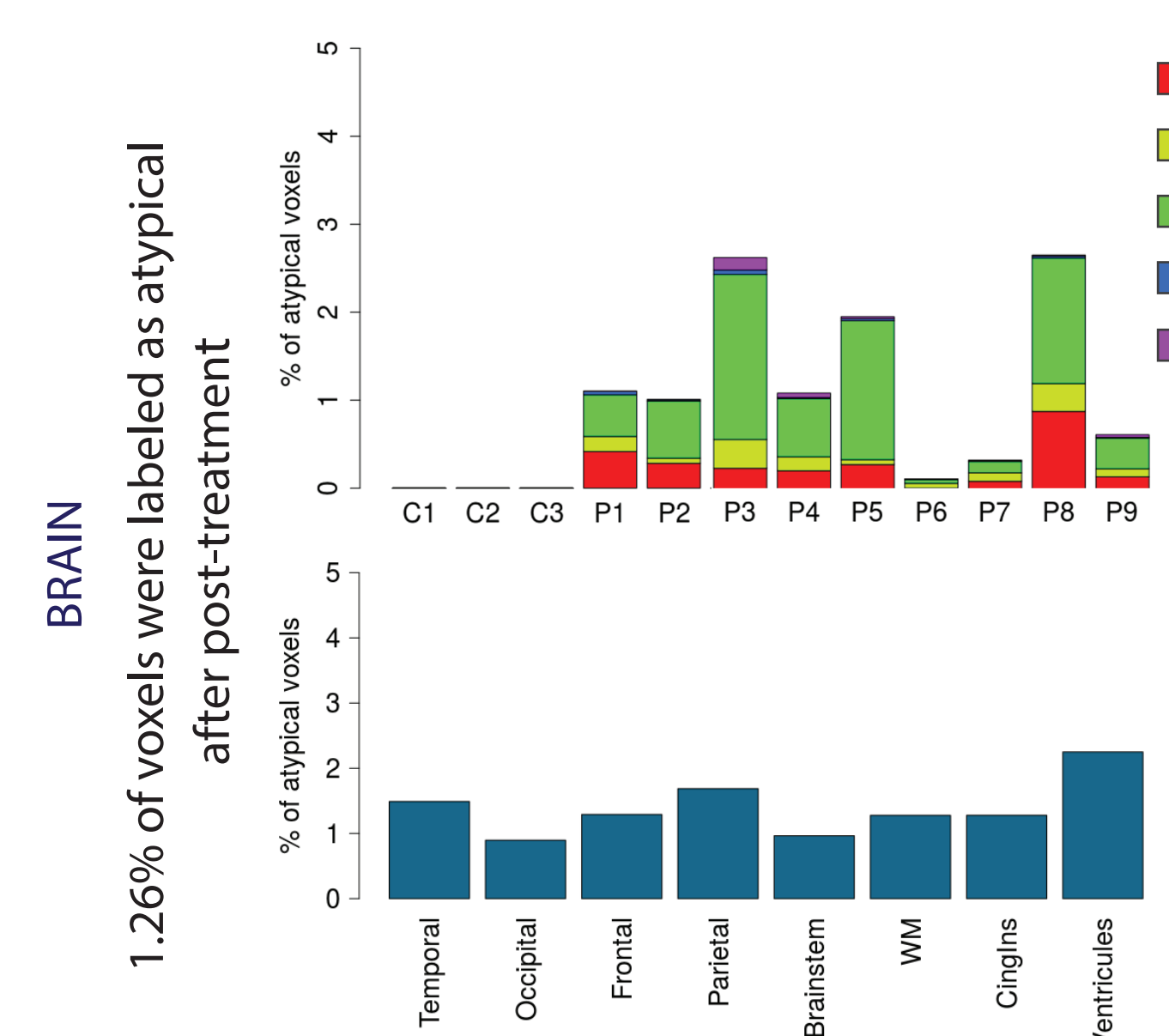
Classification of all healthy voxels in the subcortical structures [K=7] (left) and the brain [K=6] (right) following their respective reference model. In the first 3 rows the different 2D views of the voxels distribution with respect to features CBF, FA and MD. The barplot on the last row contains the proportions of each K class.

IV. Conclusions

Our method allows the **classification of brain tissues** in healthy subjects, as well as the **identification of atypical** and thus potentially pathological tissues in the brain of newly diagnosed Parkinsonian patients.

Further work must be done to provide a **physio pathological explanation** to the signatures found based on their clusters location and characteristics.

In addition, we will include **more patients** and **other MR modalities** to our study to have a more complete picture of the changes undergone by the Parkinsonian brain.



The repartition of each K class from the Atypical Model in the atypical voxels of each subject defines their individual signature. Above appears the population signatures (top) and the localisation of the detected atypical voxels in a set of relevant regions for the subcortical structures (top) and the brain (bottom).

References :

- [1] Xiao, Y. & al. (2015). "Multi-contrast unbiased MRI atlas of a Parkinson's disease population". International Journal of Computer Assisted Radiology and Surgery.
- [2] Arnaud, A. & al. (2017). "Fully Automatic Lesion Localization and Characterization: Application to Brain Tumors Using Multiparametric MRI Data". IEEE Transactions on Medical Imaging.
- [3] Forbes, F. & Wraith, D. (2014). "A new family of multivariate heavy-tailed distributions with variable marginal amounts of tailweights: Application to robust clustering." Statistics and Computing.

Verónica Muñoz Ramírez is supported by a grant from NeuroCoG IDEX UGA in the framework of the "Investissements d'avenir" program (ANR-15-IDEX-02).