HAL
open science

No Structural Differences Are Revealed by VBM in 'de novo' Parkinsonian Patients

Verónica Muñoz Ramírez, Florence Forbes, Pierrick Coupé, Michel Dojat

To cite this version:

Verónica Muñoz Ramírez, Florence Forbes, Pierrick Coupé, Michel Dojat. No Structural Differences Are Revealed by VBM in 'de novo' Parkinsonian Patients. MEDINFO 2019 - 17th World Congress On Medical And Health Informatics, Aug 2019, Lyon, France. pp.268-272, 10.3233/SHTI190225 . hal-02426273

HAL Id: hal-02426273

https://inria.hal.science/hal-02426273

Submitted on 2 Jan 2020

HAL is a multi-disciplinary open access archive for the deposit and dissemination of scientific research documents, whether they are published or not. The documents may come from teaching and research institutions in France or abroad, or from public or private research centers.

L'archive ouverte pluridisciplinaire **HAL**, est destinée au dépôt et à la diffusion de documents scientifiques de niveau recherche, publiés ou non, émanant des établissements d'enseignement et de recherche français ou étrangers, des laboratoires publics ou privés.

MEDINFO 2019: Health and Wellbeing e-Networks for All
L. Ohno-Machado and B. Séroussi (Eds.)
© 2019 International Medical Informatics Association (IMIA) and IOS Press.
This article is published online with Open Access by IOS Press and distributed under the terms of the Creative Commons Attribution Non-Commercial License 4.0 (CC BY-NC 4.0).
doi:10.3233/SHTI190225

No Structural Differences Are Revealed by VBM in 'De Novo' Parkinsonian Patients

Verónica Muñoz Ramírez[a,b], Florence Forbes[b], Pierrick Coupé[c], Michel Dojat[a]

[a] *Univ. Grenoble Alpes, Inserm U1216, CHU Grenoble Alpes, Grenoble Institut Neurosciences, 38000 Grenoble, France*
[b] *Univ. Grenoble Alpes, CNRS, Inria, Grenoble INP, LJK Laboratoire Jean Kuntzmann, 38000 Grenoble, France*
[c] *Laboratoire Bordelais de Recherche en Informatique, UMR 5800, Univ. Bordeaux, Talence, France*

Abstract

The identification of brain morphological alterations in newly diagnosed PD patients (i.e. 'de novo') could potentially serve as a biomarker and accelerate diagnosis. However, presently no consensus exists in the literature possibly due to several factors: small size cohorts, differences in segmentation techniques or bad control of false positive rates. In this study, we use the CAT12 pipeline, to seek for morphological brain differences in gray and white matter of 66 controls and 144 de novo PD patients from the PPMI database. Moreover, we search for subcortical structure differences using the VolBrain pipeline. We found no structural brain differences in this de novo Parkinsonian population, neither in tissues using a whole brain analysis nor in any of nine subcortical structures analyzed separately. We conclude that some results published in the literature may appear as false positives and we contest their reproductibility.

Keywords:

Biomarkers, Magnetic Resonance Imaging, Brain

Introduction

Parkinson's Disease (PD) is a complex neurodegenerative disorder that affects more than 10 million people worldwide [1]. It is mainly characterized by the depletion of dopaminergic neurons situated in the substantia nigra that consequentially disturbs the functions of subcortical nuclei and triggers cortical neuropathological changes causing a plethora of heavily disabling motor and non-motor symptoms [2].

In general, the diagnosis of PD takes place after the manifestation of motor symptoms, which have been found to occur once 50 % of nigrostriatal neurons are lost and dopamine levels are dropped by 80 % [2], [3], creating an urgent need to detect PD biomarkers at the earliest pre-clinical stages of illness possible [4].

The study of morphological brain differences between pathological and healthy groups could potentially identify key regions affected during the PD prodromal phase to better understand PD pathophysiology and its treatment. Magnetic Resonance Imaging (MRI) has positioned itself as a valuable tool for the non-invasive study of the brain's structure. Many automated non operator-dependent techniques have been developed for the analysis of structural MRI data. Voxel-based morphometry (VBM) is the most popular, it allows the detection of subtle morphometric group differences at voxel level [5].

In order to elucidate the nature of morphological differences in de novo PD patients, we investigated 210 subjects from the PPMI (Parkinson Progressive Markers Initiative) through both 1) the well-established Computational Anatomy Toolbox (CAT12) (University of Jena) via the current version of the Statistical Parametric Mapping (SPM12) software and 2) via a new online platform: volBrain [6]. Both pipelines have complementary strengths that are exploited in this study: volBrain performs state of the art quality segmentation of subcortical nuclei [7] and CAT12 facilitates group analysis. Furthermore, we looked for quantitative differences between the tissue classification performed by the two approaches, both including partial volume estimation.

Methods

It is well-known that gathering large cohorts of subjects is a time and resource-consuming task. This is why several efforts have been made by the community to generate databases that benefit for more than one research group. The PPMI (Parkinson Progression Markers Initiative) project is a longitudinal study that gathers data from 35 centers that follows PD patients for five years. The database is openly available for researchers and contains, among other clinical test results, structural MRI images at baseline for 412 patients and 182 healthy subjects.

The scans being heterogeneous, we chose to pool data acquired with the same acquisition parameters, notably magnetic field and scanner manufacturer, to eliminate any additional sources of bias. As a result, our study included 144 de novo PD patients (age: 61.30 ± 9.06; sex: 53 F, 91 M) and 66 healthy controls (age: 60.12 ± 11.39; sex: 23 F, 43 M) from the PPMI database. The structural T1-weighted MRI images extracted were acquired with a 3T Siemens Trio Tim scanner with repetition time (TR) = 2300 ms; echo time (TE) = 2.98 ms; flip angle = 9 degrees; field of view (FOV) = 240 x 256 mm; matrix size : 240 x 256; thickness = 1mm. We note that although T2-weighted images are generally prefered to the delineation of brain structures in neurodegenerative diseases, the available scans on PPMI are provided with low-resolution and thus barely suitable for VBM studies.

Using the CAT12 pipeline

Imaging data were first analyzed using the CAT12 toolbox included in SPM12. All 3D T1-w MRI scans follow a pre-processing protocol including intensity normalization, bias and noise-correction with the Spatially Adaptive Non-Local Means (SANLM) filter introduced in [8] that removes spatially varying noise while maintaining edges. Then the images were spatially normalized using an affine and non-linear (DARTEL and Geodesic Shooting) registration to a reference template brain. Tissue segmentation served to classify the MRI scans into gray matter (GM), white matter (WM) and cerebrospinal fluid (CSF) components. CAT12 integrates a classical Markov Random Field and the Adaptive Maximum Posterior (AMAP) technique that reduces the dependency on Tissue Probability Maps (TPM). In addition, the segmentation approach uses a Partial Volume Estimation (PVE), taking the three pure tissue classes

as input and estimating two additional mixed classes: GM-WM and GM-CSF. This allows for more precise segmentation as single voxels are likely to contain more than one tissue type. Next, the total intracranial volumes (TIV) were estimated for each subject and the segmented images were modulated by scaling with the amount of volume changes due to non-linear spatial registration, so that the total amount of grey matter in the modulated image remains the same as it would be in the original image.

The resulting images, appearing in Figure 1, were smoothed with an isotropic Gaussian kernel (8mm), and ready for statistical analysis.

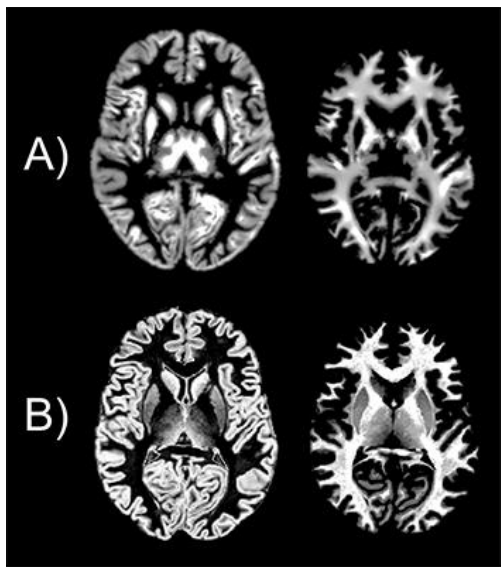

Figure 1– A) CAT12 GM and WM segmentations (modulated) B) volBrain GM and WM segmentations (raw).

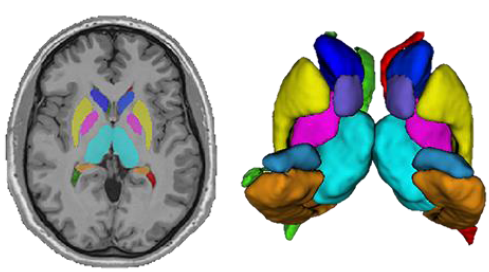

Figure 2– Segmented structures using volBrain.

Using the volBrain pipeline

In parallel, imaging data were analyzed via the volBrain online platform. This system not only provides a state-of-the-art segmentation of the brain tissues (WM, GM, CSF and TIV) (Figure 1), but also segments brain regions like the cerebrum, cerebellum and brainstem; the ventricules; and GM structures such as the putamen, the caudate, the globus pallidus, the thalamus, the hipocampus, the amygdala, and the accumbens [9], as shown in Figure 2.

The multi-template method employed to segment the above mentioned structures considers non-local label fusion schemes using a library built from the manual segmentation of 50 subjects.

The segmentation performed by volBrain provides results in the native and MNI space along with a report containing normality bounds corresponding to the age and sex of the considered subject. These bounds were estimated from the IXI dataset containing 600 normal subjects covering most of adult lifespan.

The pipeline starts by some pre-processing steps. The image is denoised using a SANLM filter, goes through a rough inhomogeneity correction using the N4 method, is registered to the MNI space with a linear affine transformation, goes though a fine SPM based inhomogeneity correction and intensity normalization. Then, segmentation takes place. Tissue classification is obtained by the TMS method that robustly estimates the mean values of the different tissues by excluding partial volume voxels from the estimation jointly with the use of an unbiased robust mean estimator. Partial Volume Coefficients (PVC) are computed from the mean values and completely leave aside tissue probability maps. Next, GM and WM are divided into cerebrum, cerebellum and brainsteam, discriminating between the two hemispheres; and last, subcortical structure segmentation is performed.

VolBrain results analysis by CAT12

Since some subcortical structures of the brain are impacted by PD, we decided to do VBM analysis for the regions provided by volBrain. To do this, we brought volBrain output images to the template space of CAT12 by applying the forward deformation DARTEL field. Once in the same space, the segmented images were used as input for the subsequent statistical analysis. For tissue segmentation analysis (GM & WM), corresponding volBrain's PVC maps were, similarly to CAT12's PVE maps, spatially smoothed with a 8mm kernel.

Statistical analysis

We chose to employ a two-sample T-test to compare the CAT12 modulated tissue maps (GM and WM) of patients versus controls with a general linear model (GLM) where age, sex, and TIV were entered as covariates. The same test was effectuated on volBrain's PVC maps.

A recent study investigating the high rate of false positive present in VBM studies recommends the use of the same group size to detect morphological differences between two groups [10]. Following this recommendation, we repeated our analysis five times to compare the tissue maps of 66 controls versus 66 randomly selected patients using sampling with replacement technique. Their age and sex characteristics are summarized on Table 1.

Table 1– Characteristics of the original study population and the 5 sub-samples of patients equal in size to the control group

	Age	Sex
Controls	60.1 ± 11.4	43 M, 23F
Patients	61.3 ± 9.1	91 M, 53F
PD sample 1	61.0 ± 8.7	40 M, 26F
PD sample 2	60.6 ± 9.7	41 M, 25F
PD sample 3	61.7 ± 9.5	44 M, 22F
PD sample 4	61.9 ± 8.7	38 M, 28F
PD sample 5	59.6 ± 8.6	38 M, 28F

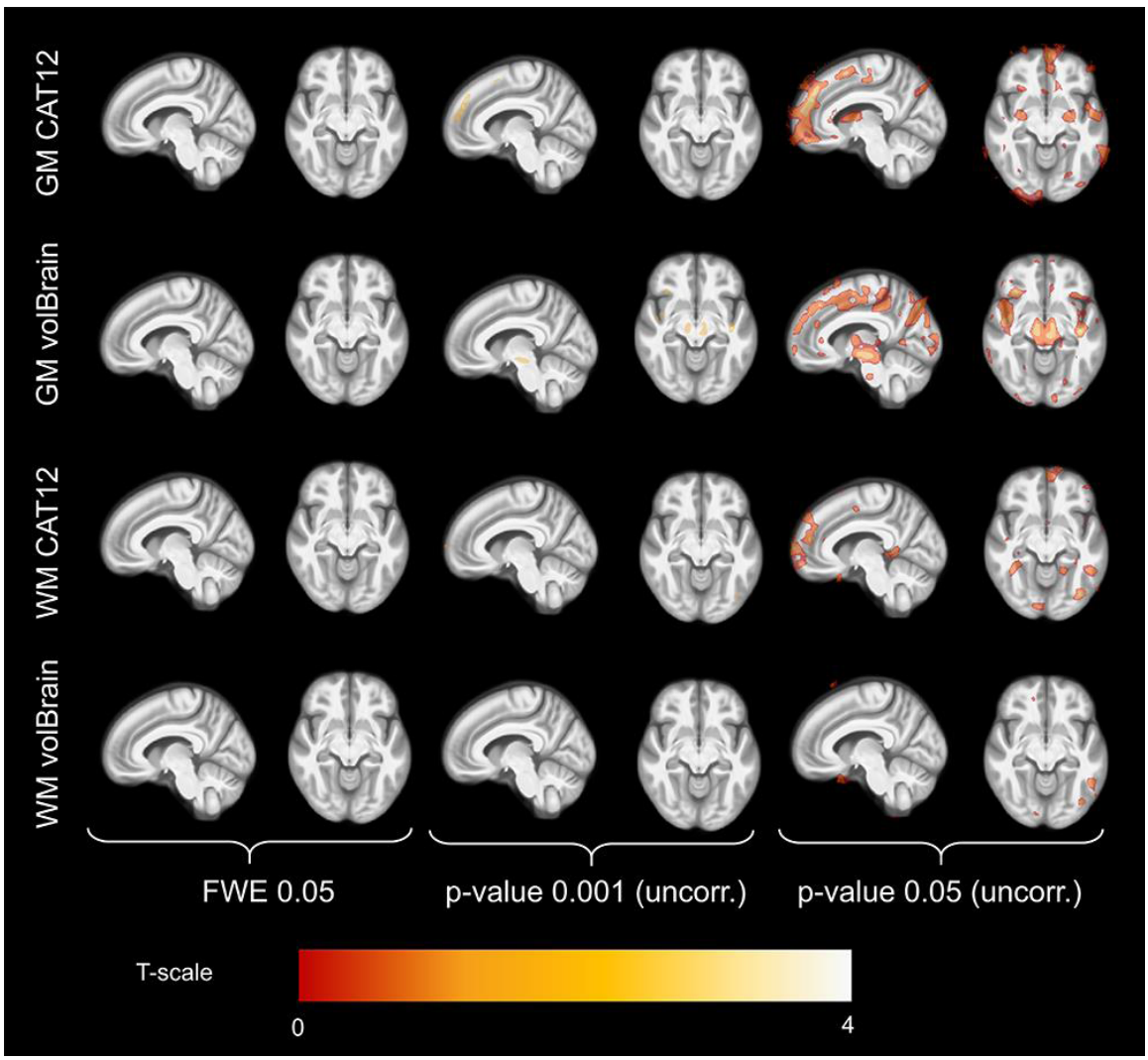

Figure 3– Comparison of PD patients vs controls. Clusters detected for GM an WM diminution in patients using CAT12 and volBrain for different statistical thresholds. The selected slices in the template's MNI space are x=99 and z=64.

Results

When choosing a p-value of 0.05 with Family Wise Error (FWE) correction for multiple comparisons, no voxels survive the difference analysis between PD patient and control groups with tissue map computed with CAT12 or volBrain. In order to replicate some literature results (exploratory study), we decreased the statistical threshold to $p<0.001$ and $p<0.05$ and refrained from any type of correction. Several clusters were then found in PD patients showing volume decrease both in GM and WM as seen in Figure 3.

Also, two-sample T-test comparisons of each independent subcortical structure (computed by volBrain) failed to detect any differences in GM and WM contents $p<0.05$ while FWE corrected. Differences were found in the caudate nucleus, the hipocampus and the putamen for an uncorrected p-value of 0.001.

"Small volume" analysis in SPM12 was used as well to study possible morphometric changes in the substantia nigra, key structure in PD research, using volBrain maps. We observed that differences were only present in gray matter for an uncorrected p-value of 0.001 and did not survived multiple comparison correction.

For all of the 5 new equal size sub-populations (see Table 1), no differences were found in GM or WM for $p< 0.05$ FWE corrected, whilst several significant clusters appeared for an uncorrected p-value of 0.001, esspecially in the frontal cortex for gray matter.

Discussion

Using two recent approaches for accurate segmentation of tissues (CAT12 and volBrain) and subcortical structures (volBrain) we failed to detect robust structural differences in de novo PD patients and healthy controls. We took special care to consider a relatively large cohort of subjects, consider the

effects of an unbalanced number of patients and controls and correct for multiple comparisons. We controlled for multiple comparison using FWE approach, which is known nevertheless to produce some false positives [11]. Following these precautions, no morphological differences were found in PD patients, neither on whole brain GM and WM group analysis or on the analysis of several subcortical structures separately.

In the literature, several studies have reported structural brain differences in PD patients compared to controls. However, these findings tend to be contradictory. In studying a different PD population than in our study, Summerfield and colleagues detected gray matter loss on the right hipocampus, the left anterior cingulate region and the left superior temporal gyrus (p=0.001 uncorrected) in PD patients (n= 13) compared to controls (n=13) [12]. Nyberg and colleagues found an augmentation in the volume of the hipocampus (p=0.03 uncorrected) of PD patients (n=21) and shape deformations of the right accumbens nucleus (p=0.005 uncorrected) compared to controls (n=20) [13]. Radziunas and colleagues observed that PD patients (n=28) with sleep disturbances had bigger ventricules and smaller hipocampus (p-FDR<0.05) than healthy controls (n=28) [14].

Similarly to our study, some VBM studies used the PPMI database and reported structural differences in PD patients. Jia and colleagues noted gray matter losses (p-FWE<0.001) in the fronto-parietal areas and the caudate nucleus, as well as an increase in the size of the limbic and paralimbic areas, the globus pallidus and the putamen of PD patients (n=89) [15] versus controls (n=55) using SPM8.

This lack of consensus on the morphological differences present in de novo PD patients may be due to a variety of factors.

Some studies were carried out on small cohorts, no more than 60 subjects in total, so one may argue that the inconsistencies could be resolved with a larger cohort more representative of the population.

Although, in [10], it was brought to light that sample size does not appear to influence false positive rate, a small sample may incorrectly represent a pathological population, hindering the reproductibility of results.

We note that there is a wide variety of softwares for pre-processing MRI images (i.e. SPM, Freesurfer, FSL), all using different techniques that will inevitably influence the final statistical results as proven by [16] on the study of Multiple Sclerosis. By combining the latest improvements on VBM analysis present in CAT12 (notably denoising and partial volume estimation) with the state of the art segmentations of volBrain [7] we sought to reduce estimation bias considerably.

Finally, correction for multiple comparison is vital to reduce the false positive rate, even if it is not perfect to hope providing robust and reproducible results [11]. Exploratory studies, which use lenient statistical thresholds, could be interesting to indicate some trends in the observed population, that should be confirmed by more robust studies. Then, in our exploratory action (p<0.001 uncorrected) we were able to reproduce some GM results reported in [17]. In the case of [15], the tests were FWE corrected, but the the study was effectuated on VBM8 while, according to [18], the CAT12 toolbox can contribute to more robust detection compared to VBM8.

Regarding the differences we observed between the tissue classification with CAT12 versus volBrain, raw volBrain's PVC maps seem to better distinguish the presence of gray and white matter in the subcortical nuclei. However, as in this study, no morphological robust differences were found between PD patients and controls, a more in depth investigation would be necessary to pertinently test the performances of both methods of partial volume estimation.

In order to further this research, other morphometric methods should be explored, notably Surface Based Morphometry (SBM) and Deformation Based Morphometry (DBM) [17].

Conclusions

In sight of the lack of morphological differences, we suspect that early PD biomarkers may lie on the physiological properties of the Parkinsonian brain and could be investigated through quantitative MRI techniques.

Finally, we reinforce the message that VBM is a delicate technique involving many parameters that should be handled with care to avoid false positive influencing the final results.

Acknowledgements

VMR is supported by a grant from NeuroCoG IDEX UGA in the framework of the "Investissements d'avenir" program (ANR-15-IDEX-02).

Data used in the preparation of this article were obtained from the Parkinson's Progression Markers Initiative (PPMI) database (www.ppmi-info.org/data). For up-to-date information on the study, visit www.ppmi-info.org.

PPMI – a public-private partnership – is funded by the Michael J. Fox Foundation for Parkinson's Research and funding partners, including Abbvie, Allergan, Avid, Biogen, BioLegend, Bristol Meyers Squibb, Denali, GE Healthcare, Genentech, GSK, Lilly, Merck, MSD, Pfizer, Piramal, Roche, Sanofi, Servier, Takeda, Teva, UCB.

References

[1] Parkinson's Foundation, "Parkinson's Prevalence Project," 2018. [Online]. Available: http://parkinson.org/Understanding-Parkinsons/Causes-and-Statistics/Statistics.

[2] M. Politis, "Neuroimaging in Parkinson disease: from research setting to clinical practice," *Nat. Publ. Gr.*, vol. 10, pp. 708–722, 2014.

[3] T. R. Barber, J. C. Klein, C. E. Mackay, and M. T. M. Hu, "Neuroimaging in pre-motor Parkinson's disease," *NeuroImage Clin.*, vol. 15, pp. 215–227, Jan. 2017.

[4] W. Poewe, "The natural history of Parkinson's disease," *J. Neurol.*, vol. 253, no. SUPPL. 7, pp. 2–6, 2006.

[5] J. Ashburner and K. J. Friston, "Unified segmentation," *Neuroimage*, vol. 26, no. 3, pp. 839–851, Jul. 2005.

[6] J. V. Manjón and P. Coupé, "volBrain: An Online MRI Brain Volumetry System," *Front. Neuroinform.*, vol. 10, p. 30, Jul. 2016.

[7] J. V. Manjón *et al.*, "Automatic thalamus and hippocampus segmentation from MP2RAGE: comparison of publicly available methods and implications for DTI quantification," *Int. J. Comput. Assist. Radiol. Surg.*, vol. 11, no. 11, pp. 1979–1991, 2016.

[8] J. V. Manjón, P. Coupé, L. Martí-Bonmatí, D. L. Collins, and M. Robles, "Adaptive non-local means denoising of MR images with spatially varying noise

levels," *J. Magn. Reson. Imaging*, vol. 31, no. 1, pp. 192–203, Jan. 2010.

[9] P. Coupé, J. V. Manjón, V. Fonov, J. Pruessner, M. Robles, and D. L. Collins, "Patch-based segmentation using expert priors: Application to hippocampus and ventricle segmentation," *Neuroimage*, vol. 54, no. 2, pp. 940–954, Jan. 2011.

[10] C. Scarpazza, S. Tognin, S. Frisciata, G. Sartori, and A. Mechelli, "False positive rates in Voxel-based Morphometry studies of the human brain: Should we be worried?," *Neurosci. Biobehav. Rev.*, vol. 52, pp. 49–55, May 2015.

[11] A. Eklund, T. E. Nichols, and H. Knutsson, "Cluster failure: Why fMRI inferences for spatial extent have inflated false-positive rates.," *Proc. Natl. Acad. Sci. U. S. A.*, vol. 113, no. 28, pp. 7900–5, Jul. 2016.

[12] C. Summerfield *et al.*, "Structural brain changes in parkinson disease with dementia: A voxel-based morphometry study," *Arch. Neurol.*, vol. 62, no. 2, pp. 281–285, Feb. 2005.

[13] E. M. Nyberg *et al.*, "Morphologic changes in the mesolimbic pathway in Parkinson's disease motor subtypes.," *Parkinsonism Relat. Disord.*, vol. 21, no. 5, pp. 536–40, May 2015.

[14] A. Radziunas *et al.*, "Brain MRI morphometric analysis in Parkinson's disease patients with sleep disturbances," *BMC Neurol.*, vol. 18, no. 1, p. 88, Dec. 2018.

[15] X. Jia, P. Liang, Y. Li, L. Shi, D. Wang, and K. Li, "Longitudinal Study of Gray Matter Changes in Parkinson Disease.," *AJNR. Am. J. Neuroradiol.*, vol. 36, no. 12, pp. 2219–26, Dec. 2015.

[16] A. Versteeg *et al.*, "Grey Matter Atrophy in Multiple Sclerosis: Clinical Interpretation Depends on Choice of Analysis Method," *PLoS One*, vol. 11, no. 1, p. e0143942, 2016.

[17] Y. Zeighami *et al.*, "Network structure of brain atrophy in de novo parkinson's disease," *Elife*, vol. 4, no. September 2015, 2015.

[18] F. Farokhian, I. Beheshti, D. Sone, and H. Matsuda, "Comparing CAT12 and VBM8 for Detecting Brain Morphological Abnormalities in Temporal Lobe Epilepsy," *Front. Neurol.*, vol. 8, p. 428, Aug. 2017.

Address for correspondence

Grenoble Institut des Neurosciences
Bâtiment Edmond J. Safra
Chemin Fortuné Ferrini, Site Santé
38706 La Tronche Cedex
Ph. 04 56 52 05 92
e-mail: veronica.munoz-ramirez@univ-grenoble-alpes.fr