



HAL
open science

Electromagnetic Tracking for Deep Liver Targets: A preliminary feasibility study

Stephen Hinds, Herman Alexander Jaeger, Richard Burke, Brodie O'sullivan, Joseph Keane, Fabian Trauzettel, Bruno Marques, Stéphane Cotin, Brian Bird, Hakon Leira, et al.

► **To cite this version:**

Stephen Hinds, Herman Alexander Jaeger, Richard Burke, Brodie O'sullivan, Joseph Keane, et al.. Electromagnetic Tracking for Deep Liver Targets: A preliminary feasibility study. International Journal of Computer Assisted Radiology and Surgery, 2019, 10.1007/s11548-019-01983-5 . hal-02121900

HAL Id: hal-02121900

<https://inria.hal.science/hal-02121900>

Submitted on 6 May 2019

HAL is a multi-disciplinary open access archive for the deposit and dissemination of scientific research documents, whether they are published or not. The documents may come from teaching and research institutions in France or abroad, or from public or private research centers.

L'archive ouverte pluridisciplinaire **HAL**, est destinée au dépôt et à la diffusion de documents scientifiques de niveau recherche, publiés ou non, émanant des établissements d'enseignement et de recherche français ou étrangers, des laboratoires publics ou privés.

Electromagnetic Tracking for Deep Liver Targets: A preliminary feasibility study [★]

Stephen Hinds¹, H. Alexander Jaeger^{[0000–0003–4771–8469]1}, Richard Burke¹, Brodie O’Sullivan¹, Joseph Keane², Fabian Trauzettel^{1,3}, Bruno Marques⁴, Stephane Cotin⁴, Brian Bird⁵, Hakon Leira⁶, Thomas Langø⁷, and Pádraig Cantillon-Murphy^{[0000–0001–6679–2889]1,8}

¹ School of Engineering, University College Cork, Ireland

² Sunbeam Veterinary Hospital, Cork, Ireland

³ IHU Strasbourg, Strasbourg, France

⁴ INRIA, Strasbourg, France

⁵ Bons Secours Hospital, Cork, Ireland

⁶ St Olavs Hospital, Trondheim, Norway

⁷ SINTEF, Trondheim, Norway

⁸ Tyndall National Institute, Cork, Ireland

1 Purpose

Percutaneous needle-based procedures such as radiofrequency ablation (RFA) and electrochemotherapy are becoming more prevalent in the treatment of hepatocellular carcinoma [6][3]. Ultrasound is a common imaging modality used in RFA, and numerous studies have demonstrated its effectiveness in treating shallow or superficial hepatic lesions (> 2cm) [7]. For smaller tumours, fusion imaging or contrast-enhanced US is often necessary [4]. Ultrasound-guided RFA in conjunction with electromagnetic tracking may improve instrument visualisation by providing out-of-plane electrode tracking and identifying the needle tip in difficult liver environments (e.g subcutaneous fat or ablation artefacts as well as needle tip obstruction [5]).

The purpose of this work is to offer a complimentary workflow for electromagnetic tracking (EMT) of needles in deep-seated liver targeting for RFA or other therapies where ultrasound is not suitable and where CBCT is limited or undesirable. Benchtop and *in vivo* preclinical studies sought to validate RFA using the Anser EMT [2] and CustusX [1] navigation platforms.

2 Methods

For pre-clinical investigations, a 34 kg female swine was anaesthetised using standard procedures (IHU Strasbourg), and 8 radiopaque markers were applied to the animals skin at bony protrusions around the liver. Percutaneous injection of a proprietary *biotumour* model was achieved at four deep-seated liver locations

[★] Supported by Science Foundation Ireland technical innovation and development award number 17/TIDA/4897.

in the right lobe (see Fig. 1) using an 11 gauge needle (Cook Osteo-Site Murphy Diamond Bevel Bone Biopsy Needle) under ultrasound guidance (Siemens Acuson S3000).

Abdominal CT (Siemens Sonatom Definition AS) using a soft tissue reconstruction filter (120 kV and 273 mAs tube parameters and 1 mm slice thickness with 0.7 mm slice overlap and 512×512 resolution) was used to visualise the liver and ITK-Snap was used to segment the liver surface, vessels, rib cage and tumour models from the preoperative CT scan (see Fig. 1). Following surface registration to the skin fiducials, percutaneous cannula introduction with visualisation in the CustusX platform was performed by an expert user with EM tracking provided by the 19 gauge Veran tracked stylet (Always-On Tip Tracked Bx Needle, Veran Medical, St. Louis, MO) inserted through the 11 gauge Murphy cannula. The needle was subject to movement due to respiration and the virtual needle was aimed to coincide with the virtual target on inhalation. The CustusX visualisation platform allowed for tool-tip extension for trajectory planning/prediction and real-time distance-to-target display. Once targeting was complete, the tracking stylet was replaced with a fitted RF electrode probe. RFA was applied to each target for 3 minutes using standard hepatic protocols before the electrode was removed (see Fig. 2a). A postoperative CT and necropsy were performed to analyse targeting and ablation accuracy.

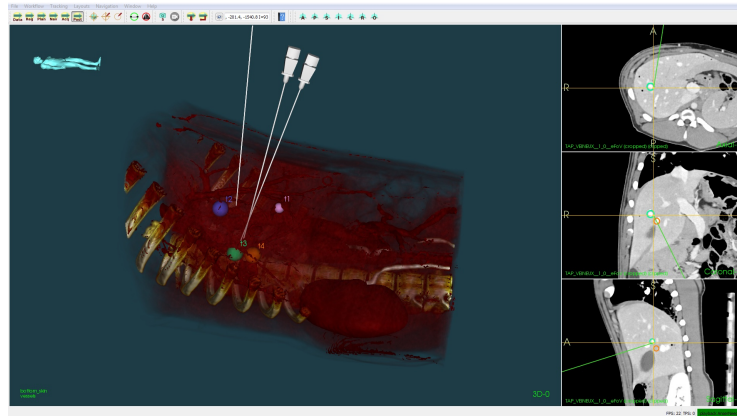


Fig. 1. The positions of the Veran EM tracked needles after targeting tumours, visualised in the CustusX navigation platform.

3 Results

Radiofrequency ablation in conjunction with EM guidance was performed on two tumours. RFA was applied to each target for 3 mins at a temperature of 55°C . Tumour targets 2 and 3 (both right posterior lobe) were targeted from two

different angles and trajectories (see Fig. 1). Tumour targets 1 and 4 (suspected leakage) were not targeted. The average targeting time from point of EM needle insertion to removal was 3.44 min (range, 2 to 5.49 min). A single puncture was used in all cases. The mean size of targets was 1.58×0.89 cm (see Table. 1). The closest distance of separation between the needle and target 3 was $\{1.12\text{cm}, 1.11\text{cm}, 0\text{cm}\}$, this was verified using postoperative CT where $\{x, y, z\}$ are referenced to the CT global imaging frame (see Table. 2). Necropsy indicated two ablations within 5mm of biotumours 2 and 3 (see Fig. 2b). Errors are considered primarily due to breathing as needle deformation due to the 11 gauge cannula are thought to be insignificant.

Table 1. The location and characteristics of the biotumours

Tumour	Size [cm]	Position	Segment
T1	1.36 x 0.82	Anterior right	S8
T2	1.04 x 1.04	Posterior right	S7
T3	2.12 x 0.73	Posterior right	S6
T4	0.65 x 0.74	Posterior right	S7

Table 2. Summary of targeting results

Needle	Tumour	Virtual Dist. [cm]	Actual Dist. [cm]	Time [mins]
1	T3	0.61 - 1.28	1.29 / 1.11 / 0	5.49
2	T3	0.45 - 1.10	1.12 / 1.10 / 0	2.00
3	T2	1.85 - 2.67	3.22 / 2.88 / 3.31	3.23

4 Conclusion

Radiofrequency ablation is an effective minimally invasive treatment for primary hepatic tumours near the liver surface and shallow tumours larger than 2cm [7]. Ultrasound-guidance may be ineffective for deep-seated targets or when no line of puncture is available due to obstacles, such as blood vessels and the gallbladder [5]. In this study, we present preliminary findings from a potential solution using electromagnetic tracking in deep-seated liver targets for RFA or other therapies where ultrasound is not suitable. Open software and hardware solutions (Anser EMT and CustsusX) were used for continuous needle tip tracking, visualised in 3D environments with intraoperative trajectory planning and multiple medical imaging modalities can help ablate difficult to access and obscure lesions and avoid anatomical structures.

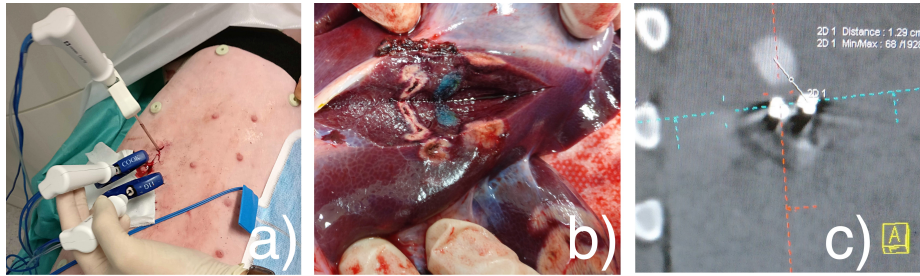


Fig. 2. a) 11 Ga Murphy Needles with RFA probes. b) Two ablations in close proximity to the blue biotumour (T3). The gallbladder is also visible. c) Postoperative CT showing estimated needle-to-target distance.

References

1. Askeland, C., Solberg, O.V., Bakeng, J.B.L., Reinertsen, I., Tangen, G.A., Hofstad, E.F., Iversen, D.H., Vapenstad, C., Selbekk, T., Lango, T., Hernes, T.A.N., Olav Leira, H., Unsgard, G., Lindseth, F.: CustusX: an open-source research platform for image-guided therapy. *International journal of computer assisted radiology and surgery* **11**(4), 505–519 (apr 2016)
2. Jaeger, H.A., Franz, A.M., O’Donoghue, K., Seitel, A., Trauzettel, F., Maier-Hein, L., Cantillon-Murphy, P.: Anser EMT: the first open-source electromagnetic tracking platform for image-guided interventions. *International Journal of Computer Assisted Radiology and Surgery* **12**(6), 1059–1067 (2017)
3. Kunte, C., Letulé, V., Gehl, J., Dahlstroem, K., Curatolo, P., Rotunno, R., Muir, T., Occhini, A., Bertino, G., Powell, B., Saxinger, W., Lechner, G., Liew, S.H., Pritchard-Jones, R., Rutkowski, P., Zdzienicki, M., Mowatt, D., Sykes, A.J., Orlando, A., Mitsala, G., Rossi, C.R., Campana, L., Brizio, M., de Terlizzi, F., Quaglino, P., Odili, J.: Electrochemotherapy in the treatment of metastatic malignant melanoma: a prospective cohort study by InspECT. *British Journal of Dermatology* **176**(6), 1475–1485 (2017)
4. Song, K.D., Lee, M.W., Rhim, H., Kang, T.W., Cha, D.I., Sinn, D.H., Lim, H.K.: Percutaneous US/MRI Fusion-guided Radiofrequency Ablation for Recurrent Sub-centimeter Hepatocellular Carcinoma: Technical Feasibility and Therapeutic Outcomes. *Radiology* **288**(3), 878–886 (2018)
5. Tomonari, A., Tsuji, K., Yamazaki, H., Aoki, H., Kang, J.H., Kodama, Y., Sakurai, Y., Maguchi, H.: Feasibility of the virtual needle tracking system for percutaneous radiofrequency ablation of hepatocellular carcinoma. *Hepatology Research* **43**(12), 1352–1355 (2013)
6. Week, W.: Oncology - Liver Metastasis ; Recent Reports from First Affiliated Hospital of Sun Yat-sen University Highlight Findings in Liver Metastasis (Ultrasound-Guided Percutaneous Radiofrequency Ablation of Liver Metastasis From Ovarian Cancer : A Single-Center **27**(6), 2017–2019 (2017)
7. Wu, J., Lin, S., Wu, W., Yan, K., Dai, Q., Chen, M.: Clinical application of ultrasound-guided radiofrequency ablation for primary hepatocellular carcinoma near the liver surface]. *Zhonghua zhong liu za zhi [Chinese journal of oncology]* **37**(12), 933–7 (dec 2015)