



HAL
open science

Hippocampus and shape analysis

Claire Cury

► **To cite this version:**

Claire Cury. Hippocampus and shape analysis. TIG Symposium for Epilepsy, Mar 2017, London, United Kingdom. hal-02080594

HAL Id: hal-02080594

<https://inria.hal.science/hal-02080594>

Submitted on 26 Mar 2019

HAL is a multi-disciplinary open access archive for the deposit and dissemination of scientific research documents, whether they are published or not. The documents may come from teaching and research institutions in France or abroad, or from public or private research centers.

L'archive ouverte pluridisciplinaire **HAL**, est destinée au dépôt et à la diffusion de documents scientifiques de niveau recherche, publiés ou non, émanant des établissements d'enseignement et de recherche français ou étrangers, des laboratoires publics ou privés.

Hippocampus and shape analysis

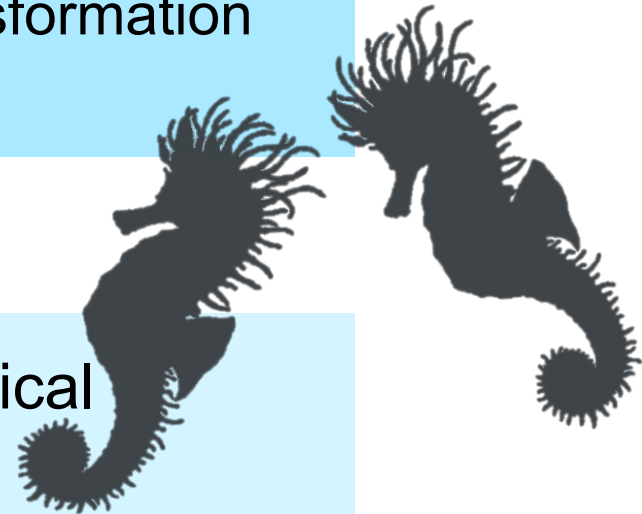
TIG symposium for epilepsy

Claire Cury

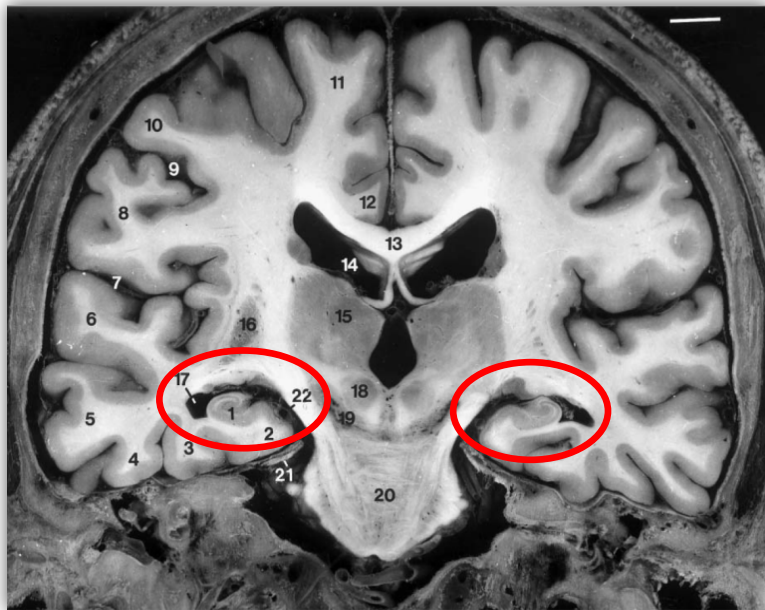
Introduction

- **Position:** Position of the object in its environment.
- **Shape:** 3D edge of an object. Ridge transformation invariant.

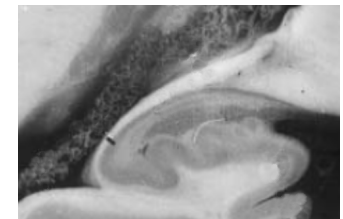
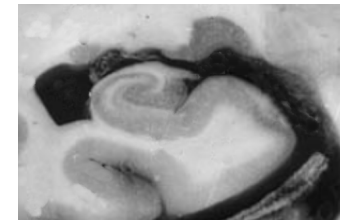
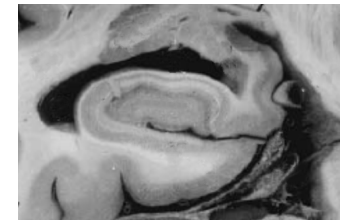
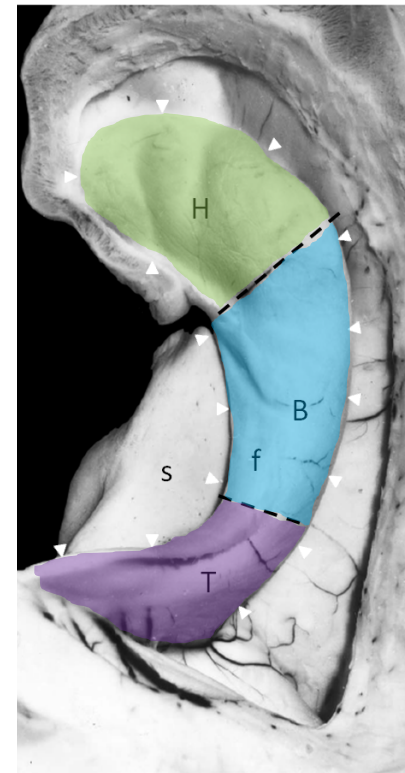
- **Statistical shape analysis** of anatomical structures
 - **Modelisation** of normal and pathological variability.
 - **Prediction** of clinical and biological parameters.



Hippocampus Anatomy



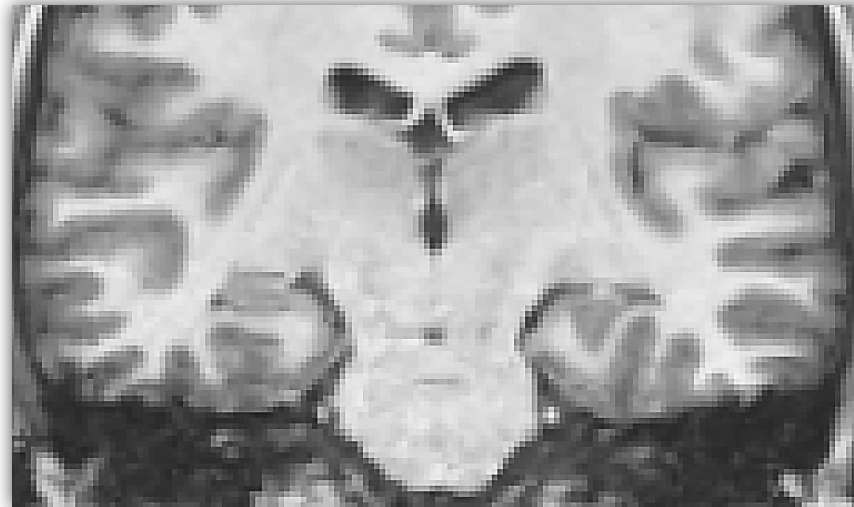Images: Duvernoy et al, 2005



Incomplete Hippocampal Inversion (IHI)

Mainly described in **epileptic patients** (Barsi et al. 2000; Bajic et al. 2009;...) ~ 50%

In healthy population (Bernasconi et al. 2005; Bajic et al. 2008; Gamss et al. 2009) ~ 20%



**Criteria
ill-defined**

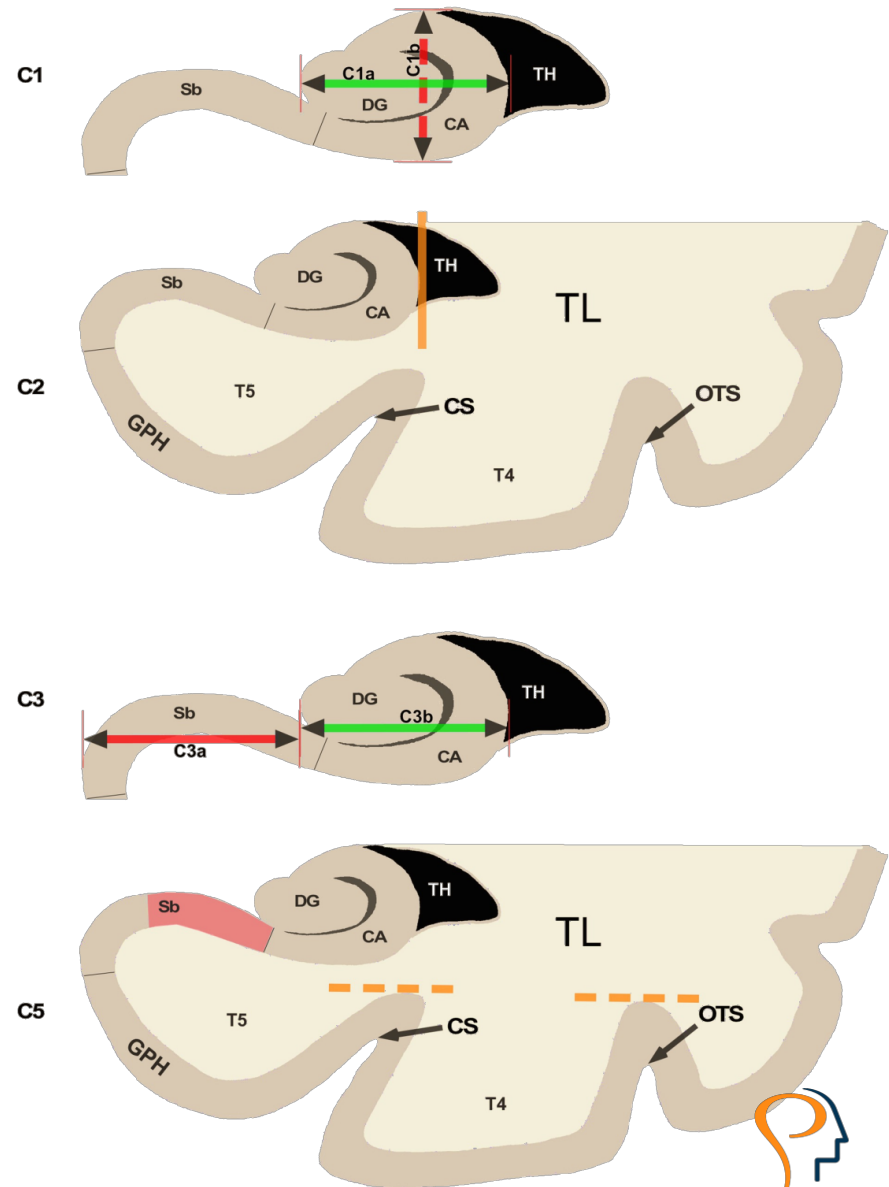

Mix of healthy and controls (non epileptics) (Gamss et al. 2009)

Not enough subjects (Bajic et al. 2008)

IHI : Criteria

- **C1:** roundness and verticality
- **C2:** collateral sulci
- **C3:** position
- **C4:** subiculum
- **C5:** T4 sulci

- **C0, IHI global appraisal:**
 - **0** : normal aspect
 - **1** : Partial IHI
 - **2** : Total IHI



IHI : Results on 2000+ young subjects

Smaller volumes for IHI
(test-t = 5,93; p = 4,1e-9).

Volumes (en cm ³)	IHI	No IHI
Left	2,75	2,95
Right	2,78	2,99

QC seg	IHI	Partial IHI	No IHI
Left	2,06	2,46	2,74
Right	2,38	2,65	2,69



Segmentation quality
deteriorated by IHI
(t-test, p < 1e-10).

IHI more **habitual** on the **left** side (test du χ^2 , p = 8.10⁻²⁹)

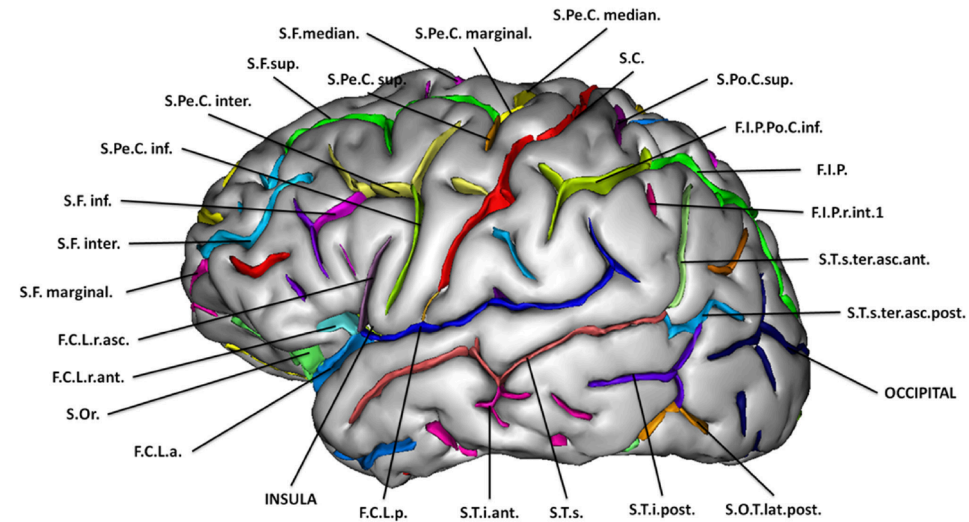
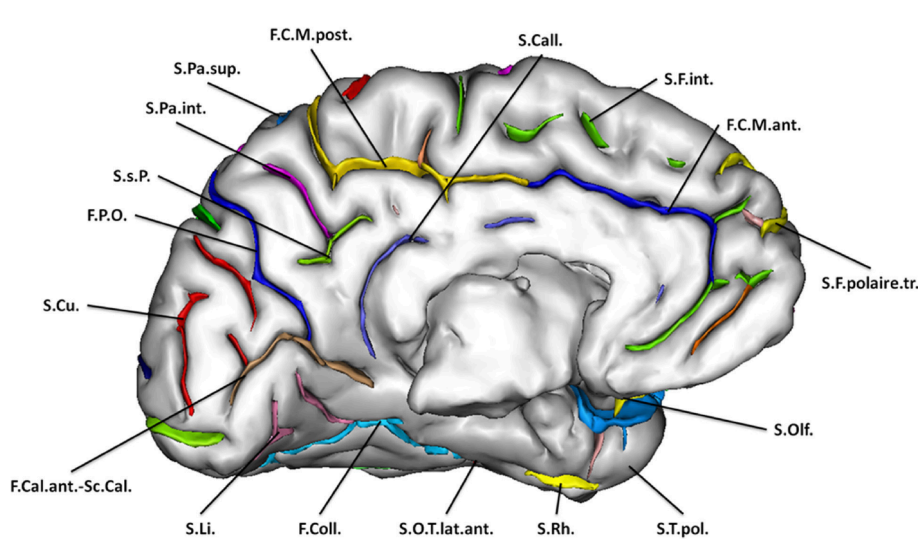
C0	IHI
Left	17.1% CI: [15.5%; 18.7%]
Right	6.5% CI: [5.4%; 7.6%]

Left vs Right	Right IHI
No IHI Left	1.9% CI: [1.3%; 2.5%]
Partial Left IHI	0.5% CI: [0.2%; 0.8%]
Left IHI	4.0% CI: [3.1%; 4.9%]

Right unilateral IHI are **occasional** (test du χ^2 , p = 7.10⁻⁸²)

IHI do **not depend** on **gender** or **hand laterality**.

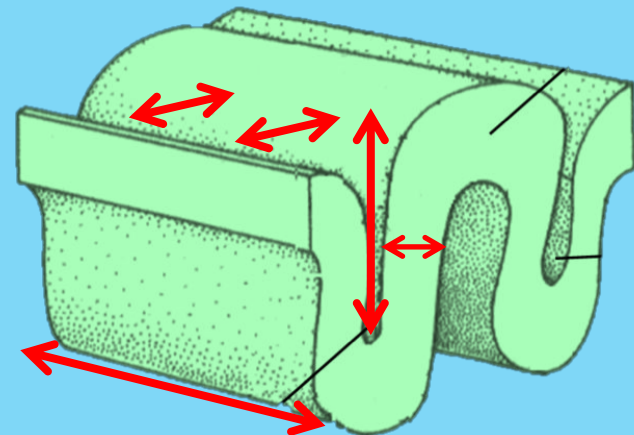
IHI and sulci : Developmental hypothesis



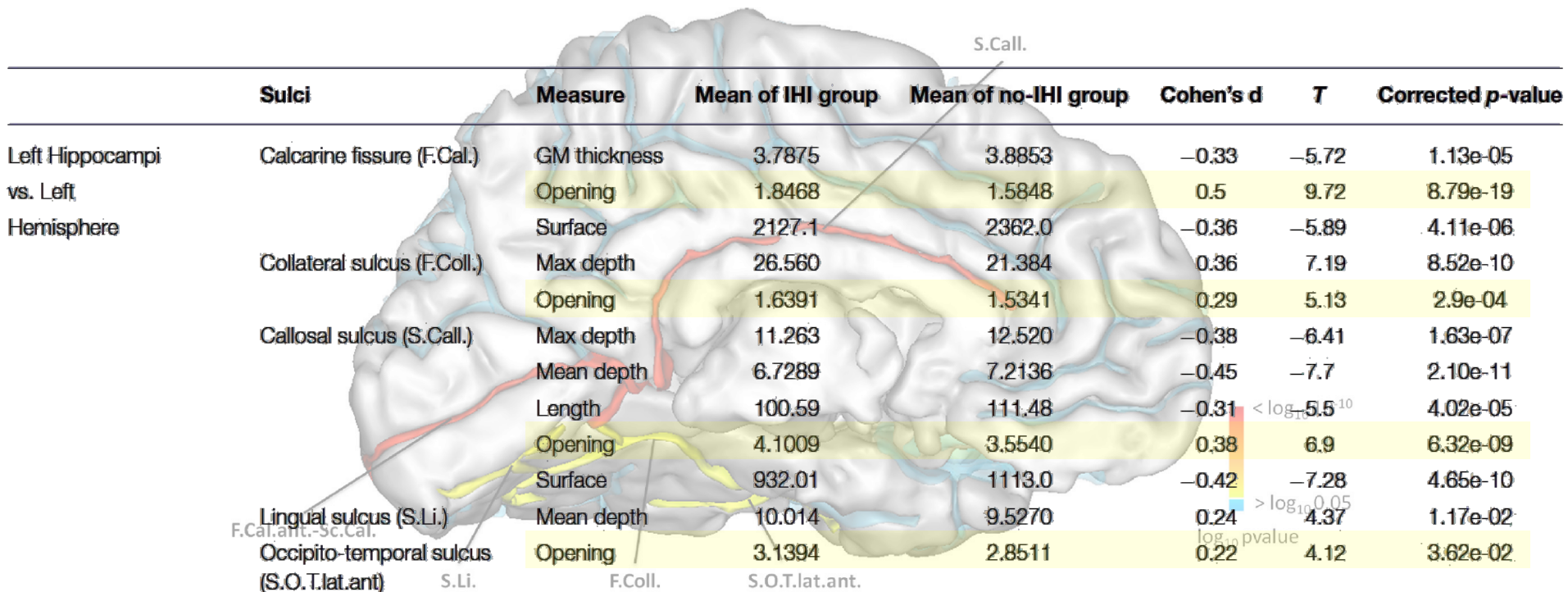
Sulci segmentation and labialisation (Morphologist, Brainvisa).

1705 subjects, 6 measures:

- Surface
- Maximal depth
- Mean depth
- Length
- Grey matter thickness
- Opening




IHI and sulci : Results

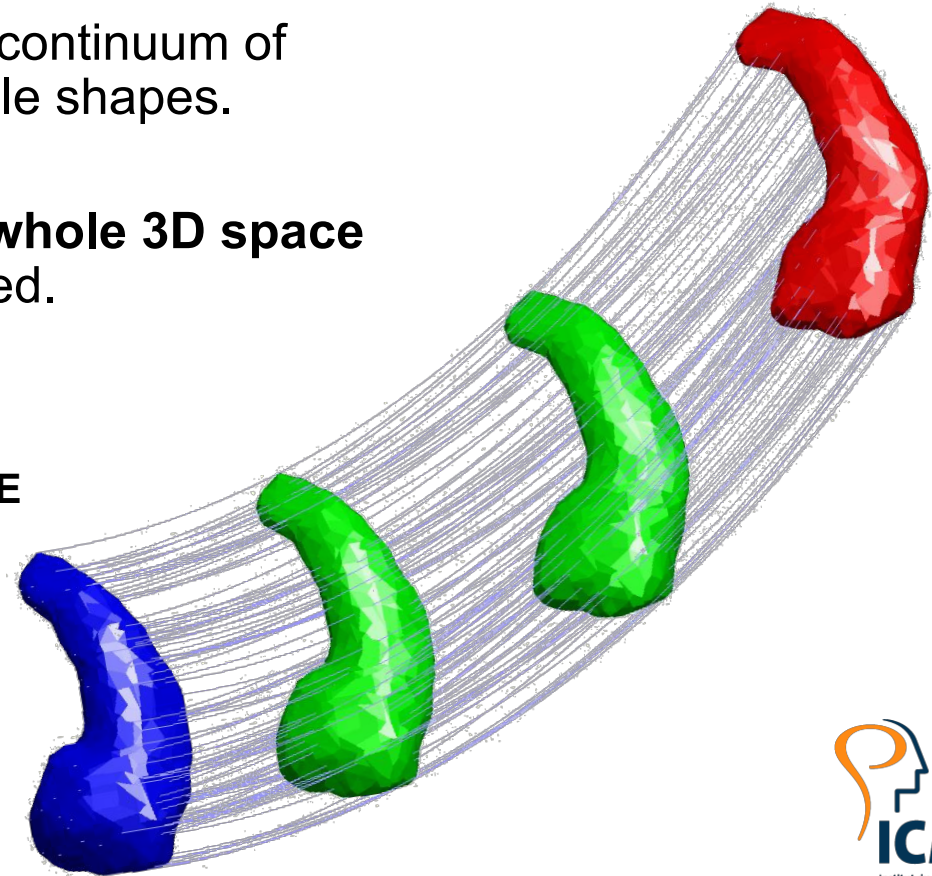


Common point of these sulci: The opening is significantly higher for the IHI group.

Shape analysis

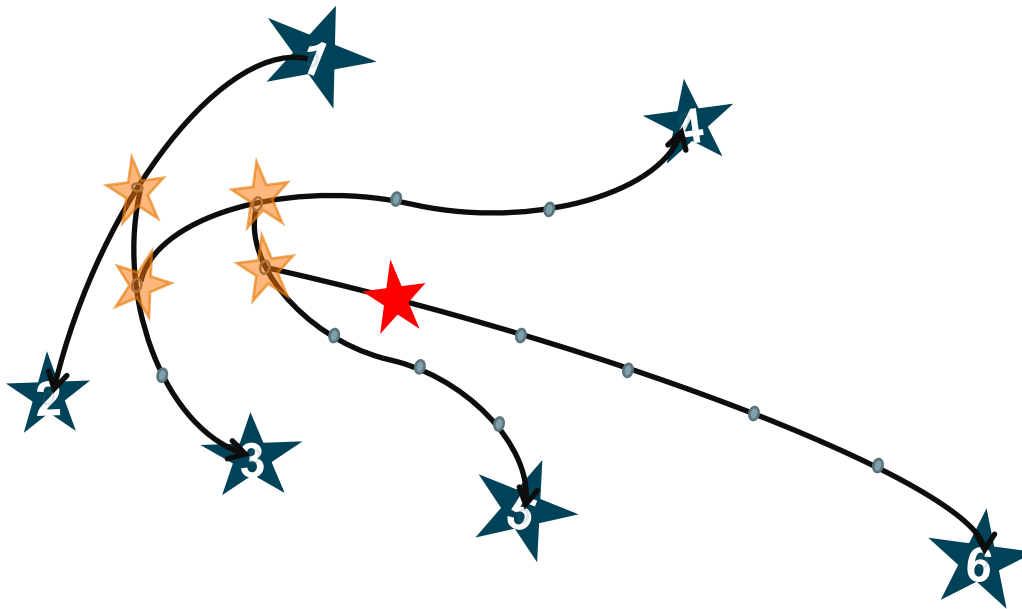
LDDMM Large Deformation Diffeomorphic Metric Mapping : Quantify the differences between shapes.

- 2 shapes can be connected by a continuum of intermediate anatomically plausible shapes.
- Diffeomorphic maps **act on the whole 3D space**
→ spatial organization is preserved.
-  **EXPENSIVE IN COMPUTATION TIME**



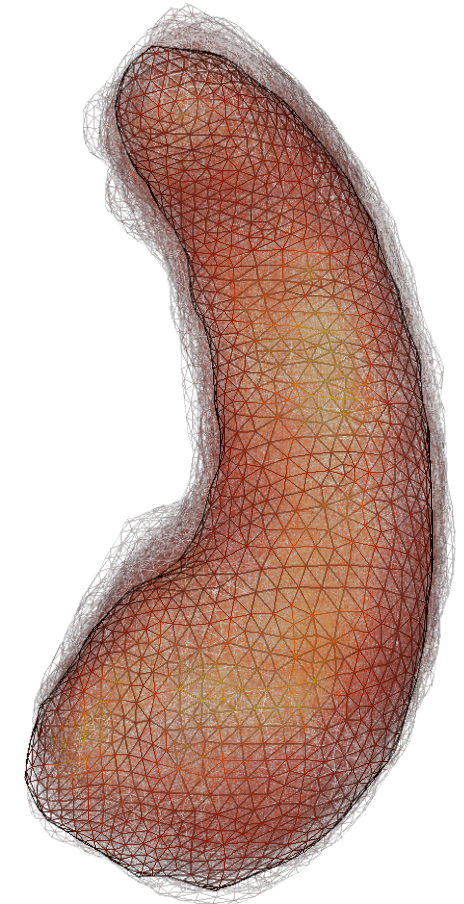
Shape analysis: GroupWise study

Analyse of **shape deformations** from a **centre** of the population.



Prediction of IHI scores using the shape information of **1000** hippocampi. (corr = 0.47)

→ **Need to improve the prediction of IHI scores using sulci measures**



Exemple:
Barycentre of 95 surfaces

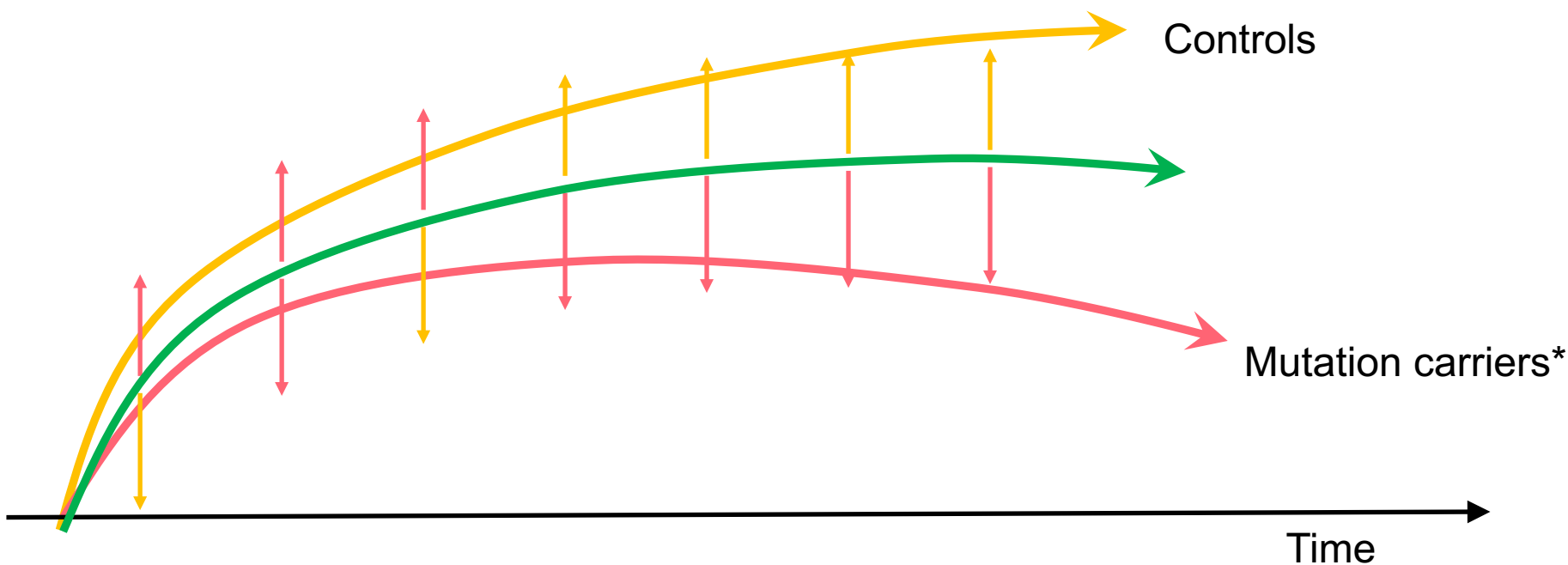
Shape analysis: Spatio-temporal study

Detection of early shape changes in genetic dementia

Neuro-degenerative diseases as AD or FTD have **progressive clinical symptoms** (dementia, memory loss, changes in behaviour,...).

There is evidence of **anatomical changes** [Rohrer et al. 2015] that occur in these diseases much earlier than the onset of these clinical symptoms.

→ Can we detect differences using shape information?



* For genetic form of neurodegenerative disease, the mutation carrier group represent the subject with a mutation on one of the at-risk gene.

Shape analysis: Spatio-temporal study

Kernel PCA on deformation's parametrisations

Mixed effect model on the Principal Components

fixed effects: MC, EYO, MC x EYO, EYO²
random effects: family, center, gender

THE SHAPE ANALYSIS DETECTS CHANGES EARLIER THAN THE VOLUMETRIC ANALYSIS

	p-value for MC status	p-value for EYO int.
1 PC	3e-3	4e-3
2 PCs	3e-3	0.02
3 PCs	< 1e-4	0.02

Wald test every 5 years how long before the EYO we can detect shape differences

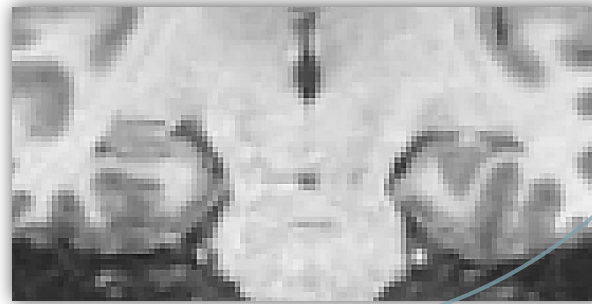
PCs (captured var.) \ EYO	-25	-20	-15	-10	-5	0	+5	+10
PC 1 (20.4%)	0.70	0.94	0.60	0.16	8e-3	<1e-3	<1e-3	<1e-3
PC 2 (11.3%)	0.42	0.26	0.16	0.08	0.03	0.01	0.01	0.03
PC 3 (10.8%)	0.29	0.13	0.08	0.06	0.06	0.08	0.25	0.62
PC 1+2 (31.7%)	0.78	0.80	0.77	0.45	0.07	1e-3	<1e-3	<1e-3
PC 1+2+3 (42.5%)	0.76	0.49	0.23	0.05	2e-3	<1e-3	<1e-3	<1e-3
Total thalamus volume [Rohrer et al.]	0.36	0.50	0.47	0.25	0.04	<1e-3	<1e-3	<1e-3
Total thalamus volume	0.38	0.50	0.47	0.24	0.04	<1e-3	<1e-3	<1e-3
Left thalamus volume	0.77	0.97	0.96	0.96	0.69	0.33	0.14	0.10

Conclusion and perspectives

Prediction of the **IHI** scores using the shape information of hippocampi.

Template-based shape analysis method with diffeomorphic deformation : modelling the **anatomical variability** of **1000 hippocampi**.

Better **evaluation** of the **IHI**:
Detailed
Robust



Understand the **lateralisation** of the IHI
Genetic of the IHI

Prediction can be improved, using **sulci measures**

Great **potential** of **shape analysis** to better understand brain anatomy

- Analysing different brain structures together (hippocampus and sulci)
- Understanding the sulci's opening

Shape analysis Interesting in **longitudinal** studies and for **developmental** studies.

- Follow changes of some biomarker of lesions shape