



HAL
open science

Structural, microstructural and metabolic alterations in Primary Progressive Aphasia variants

Alexandre Routier, Marie-Odile Habert, Anne Bertrand, Aurélie Kas,
Pierre-Maxime David, Hugo Bertin, Olivier Godefroy, Frédérique
Etcharry-Bouyx, Olivier Moreaud, Florence Pasquier, et al.

► **To cite this version:**

Alexandre Routier, Marie-Odile Habert, Anne Bertrand, Aurélie Kas, Pierre-Maxime David, et al.. Structural, microstructural and metabolic alterations in Primary Progressive Aphasia variants. Annual meeting of the Organization for Human Brain Mapping - OHBM 2018, Jun 2018, Singapore, Singapore. hal-01764289

HAL Id: hal-01764289

<https://inria.hal.science/hal-01764289v1>

Submitted on 12 Apr 2018

HAL is a multi-disciplinary open access archive for the deposit and dissemination of scientific research documents, whether they are published or not. The documents may come from teaching and research institutions in France or abroad, or from public or private research centers.

L'archive ouverte pluridisciplinaire **HAL**, est destinée au dépôt et à la diffusion de documents scientifiques de niveau recherche, publiés ou non, émanant des établissements d'enseignement et de recherche français ou étrangers, des laboratoires publics ou privés.

Structural, microstructural and metabolic alterations in Primary Progressive Aphasia variants

Alexandre Routier^{1,2}, Marie-Odile Habert^{3,4,5}, Anne Bertrand^{1,6,7}, Aurélie Kas^{3,4}, Pierre-Maxime David^{3,4}, Hugo Bertin^{3,4,5}, Olivier Godefroy⁸, Frédérique Etcharry-Bouyx⁹, Olivier Moreaud¹⁰, Florence Pasquier¹¹, Philippe Couratier¹², Karim Bennys¹³, Claire Boutoleau Bretoniere¹⁴, Olivier Martinaud^{15,16}, Bernard Laurent¹⁷, Jérémie Pariente^{18,19}, Michèle Puel¹⁸, Serge Belliard^{16,20}, Raphaëlla Migliaccio^{2,21}, Bruno Dubois^{2,21,22}, Olivier Colliot^{1,23,24}, Marc Teichmann^{2,21,22} for the CAPP study group

¹ Inria Paris, Aramis project-team, Paris, France

² Sorbonne Université, Inserm, CNRS, Institut du Cerveau et la Moëlle épinière (ICM), FrontLab, Paris, France

³ Laboratoire d'Imagerie Biomédicale, Sorbonne Université, Inserm U 1146, CNRS UMR 7371, Paris, France

⁴ AP-HP, Hôpital Pitié-Salpêtrière, Department of Nuclear Medicine, Paris, France

⁵ Centre pour l'Acquisition et le Traitement des Images, Institut du Cerveau et la Moëlle épinière (ICM)

⁶ Sorbonne Université, Inserm, CNRS, Institut du Cerveau et la Moëlle épinière (ICM), Paris, France

⁷ AP-HP, Hôpital Saint Antoine, Department of Radiology, Paris, France

⁸ Department of Neurology and Laboratory of Functional Neurosciences (EA 4559), University Hospital of Amiens. France

⁹ Department of Neurology, Memory Research and Resource Center for Alzheimer's Disease, University Hospital of Angers. France

¹⁰ Department of Psychiatry, Neurology and Rehabilitation University Hospital of Grenoble, Memory Research and Resource Center for Alzheimer's Disease. France

¹¹ Department of Neurology, University Hospital of Lille. France

¹² Department of Neurology, University Hospital of Limoges. France

¹³ Department of Neurology, Memory Research and Resource Center for AD, University Hospital of Montpellier. France

¹⁴ Department of Neurology, University Hospital of Nantes. France

¹⁵ Department of Neurology, University Hospital of Rouen. France

¹⁶ Normandie University, UNICAEN, EPHE, INSERM, U1077, Neuropsychologie et Imagerie de la Mémoire Humaine. France

¹⁷ Department of Neurology, University Hospital of Saint-Etienne. France

¹⁸ Department of Neurology, Pierre Paul Riquet Hospital, Toulouse. France

¹⁹ INSERM/UPS, UMR 1214 - ToNIC, Toulouse NeuroImaging Center, University of Toulouse III. France

²⁰ Department of Neurology, Memory Research and Resource Center for AD, University Hospital Pontchaillou, Rennes. France

²¹ Department of Neurology, Institute for Memory and Alzheimer's Disease, Pitié-Salpêtrière Hospital, AP-HP, Paris, France

²² National Reference Center for "PPA and rare dementias", Institute for Memory and Alzheimer's Disease, AP-HP, Paris, France

²³ AP-HP, Departments of Neuroradiology and Neurology, Hôpital de la Pitié-Salpêtrière, Paris, France

Introduction

Primary Progressive Aphasia (PPA) is a group of rare neurodegenerative diseases affecting language abilities. Three main variants [Gorno-Tempini et al., 2011] have been identified: non-fluent PPA (nfv-PPA) affecting syntax and phonological encoding, logopenic PPA (lv-PPA) impairing word-finding and verbal working memory, and semantic PPA (sv-PPA) characterized by an erosion of the system of word meanings. Various neuroimaging studies have demonstrated distinct atrophy (T1 MRI), hypometabolic (FDG PET) and white matter (WM) (diffusion MRI) alterations in PPA variants [Galantucci et al., 2011; Acosta-Cabronero et al., 2011; Ossenkoppele et al., 2015; Matias-Guiu et al., 2015; Mesulam et al., 2015; Krishnan et al., 2017]. However, these studies either included a relatively small number of patients, or were restricted to one PPA variant or to a single imaging modality. Therefore, the complementarity of those imaging techniques in PPA has not been extensively assessed.

In this paper, we propose to combine structural MRI, diffusion MRI and FDG PET imaging to characterize the three subtypes of PPA in a large cohort of patients.

Methods

Participants were recruited from a French multicenter investigation on PPA (PHRC-CAPP). 101 subjects (79 PPA, 41 sv-PPA, 26 lv-PPA, 12 nfv-PPA, 22 HC) had both T1 MRI and PET. 77 subjects (59 PPA, 32 sv-PPA, 19 lv-PPA, 6 nfv-PPA, 18 HC) had both T1 and diffusion MRI. For T1 MRI, we used cortical thickness (CT) analysis based on FreeSurfer. Diffusion MRI was analyzed using a region-of-interest approach, based on custom pipelines combining tools from FSL, ANTS and MRtrix. Specifically, we analyzed the average Fractional Anisotropy (FA) and Mean Diffusivity (MD) within each tract of the JHU WM atlas [Mori et al., 2005]. These pipelines are available in the Clinica platform (<http://clinica.run>). FDG PET data was analyzed using a voxel-based approach, using custom pipelines based on SPM. PET were corrected for partial volume.

Statistical analysis was performed using general linear model with age and sex as covariates. Statistics were corrected for multiple comparisons using random field theory for CT and PET, and Bonferroni correction for diffusion MRI.

Results

Results are shown in **Fig. 1-2**. Sv-PPA patients presented atrophy and hypometabolism in the anterior temporal lobes (ATL) bilaterally and in the left posterior temporal lobe, where atrophy was slightly more extensive than hypometabolism. Tracts connecting the ATL were altered bilaterally (uncinate fasciculus (UNC) for FA/MD and inferior longitudinal fasciculus (ILF) for MD). Tracts connecting the posterior temporal lobe were altered on the left side (inferior fronto occipital fasciculus (IFOF) and superior longitudinal fasciculus (SLF) for FA). Finally, alterations were observed within the right anterior thalamic radiation (ATR) for FA.

Lv-PPA patients exhibited atrophy and hypometabolism in the left temporo-parietal junction and the left posterior temporal lobe, where hypometabolism was more extended than atrophy. Tracts passing through these regions were altered, namely the IFOF (FA/MD), the ILF (MD) and the SLF (FA/MD). Finally, the forceps major was altered (FA) together with the left and right ATR (MD).

Nfv-PPA patients presented hypometabolism in small regions of the left inferior frontal gyrus. Larger alterations were found for CT, including the left premotor and left primary motor cortex. Diffusion MRI alterations were much less widespread than for other PPA variants, probably because of the smaller sample size. Of note, the UNC was found altered (MD). More surprisingly, the right temporal part of the SLF was also found altered (MD).

Conclusions

To the best of our knowledge, we present the largest study of all PPA variants using multimodal imaging (T1, DWI, FDG PET). These results showed high concordance between atrophy and hypometabolism for each PPA variant. WM alterations were more widespread including, but not limited to, tracts connecting the atrophic/hypometabolic regions.

References

- Gorno-Tempini, M. L., Hillis, A. E., Weintraub, S., Kertesz, A., Mendez, M., Cappa, S. F., Ogar, J.M., Rohrer, J.D., Black, S., Boeve, B.F., Manes, F., Dronkers, N.F., Vandenberghe, R., Rascovsky, K., Patterson, K., Miller, B.L., Knopman, D.S., Hodges, J.R., Mesulam, M.M., Grossman, M. (2011). Classification of primary progressive aphasia and its variants. *Neurology*, 76(11), 1006-1014.
- Mesulam, M. M., Thompson, C. K., Weintraub, S., Rogalski, E. J. (2015). The Wernicke conundrum and the anatomy of language comprehension in primary progressive aphasia. *Brain*, 138(8), 2423-2437.
- Matas-Guiu, J. A., Cabrera-Martn, M. N., Pérez-Castejn, M. J., Moreno-Ramos, T., Rodriguez-Rey, C., Garca-Ramos, R., Fernandez-Matarrubia, M., Oreja-Guevara, C., Matias-Guiu, J., Carreras, J. L. (2015). Visual and statistical analysis of 18F-FDG PET in primary progressive aphasia. *European journal of nuclear medicine and molecular imaging*, 42(6), 916-927.
- Acosta-Cabronero, J., Patterson, K., Fryer, T. D., Hodges, J. R., Pengas, G., Williams, G. B., Nestor, P. J. (2011). Atrophy, hypometabolism and white matter abnormalities in semantic dementia tell a coherent story. *Brain*, 134(7), 2025-2035.

Ossenkoppele, R., CohnSheehy, B. I., La Joie, R., Vogel, J. W., Mller, C., Lehmann, M., ..., Kramer, J. H. (2015). Atrophy patterns in early clinical stages across distinct phenotypes of Alzheimer's disease. *Human brain mapping*, 36(11), 4421-4437.

Galantucci, S., Tartaglia, M. C., Wilson, S. M., Henry, M. L., Filippi, M., Agosta, F., ..., Gorno-Tempini, M. L. (2011). White matter damage in primary progressive aphasias: a diffusion tensor tractography study. *Brain*, 134(10), 3011-3029.

Krishnan, K., Machulda, M. M., Whitwell, J. L., Butts, A. M., Duffy, J. R., Strand, E. A., ... , Josephs, K. A. (2017). Varying Degrees of Temporoparietal Hypometabolism on FDG-PET Reveal Amyloid-Positive Logopenic Primary Progressive Aphasia is not a Homogeneous Clinical Entity. *Journal of Alzheimer's Disease*, 55(3), 1019-1029.

Mori, S., Wakana, S., Van Zijl, P. C., Nagee-Poetscher, L. M. (2005). *MRI atlas of human white matter*. Elsevier.

Figures

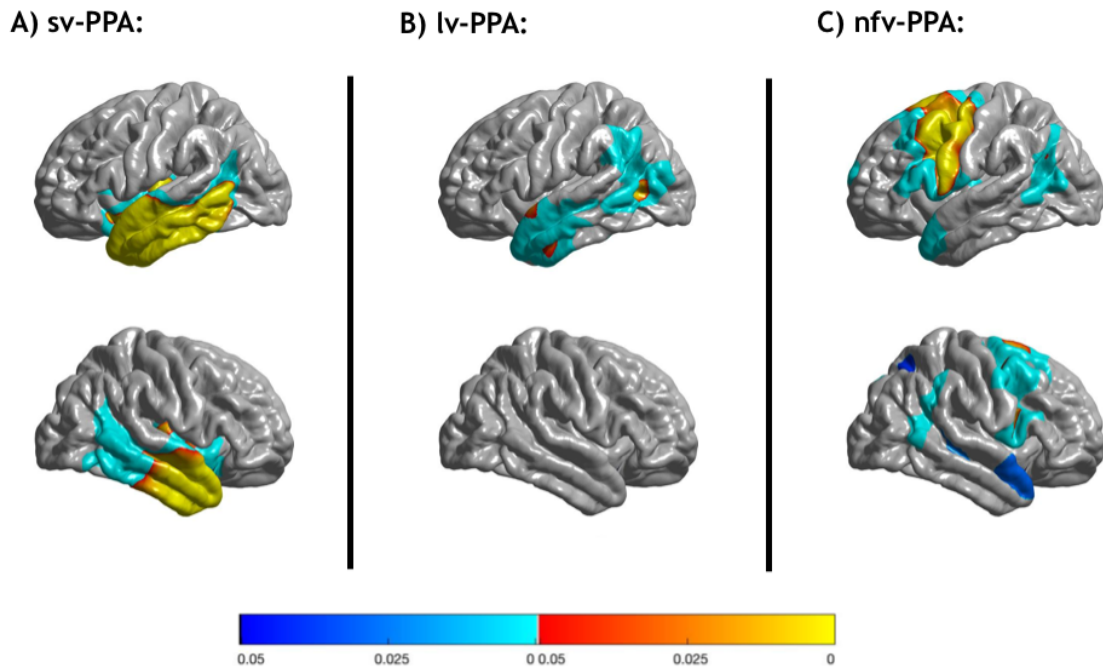


Fig.1. Areas of significantly reduced cortical thickness in A) sv-PPA B) lv-PPA, C) nfv-PPA compared to healthy controls. Correction for multiple comparisons using the Random Field Theory (blue colormap for cluster correction, red colormap for vertex correction) with corrected p -values < 0.05 are displayed. Age, sex were used as covariates. The surfacic smoothing kernel was 20 mm.

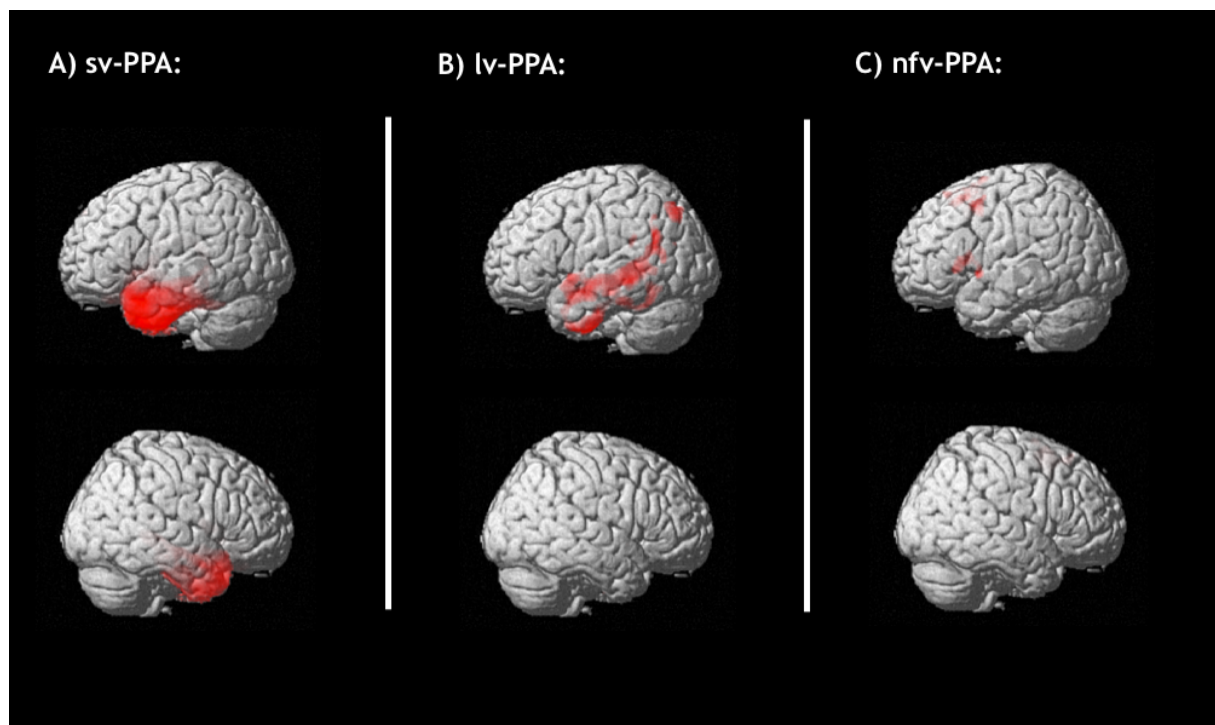


Fig.2. Areas of significant hypometabolism in A) sv-PPA B) lv-PPA, C) nfv-PPA compared to healthy controls. Correction for multiple comparisons using the Random Field Theory using Family-wise error with corrected p -values < 0.05 are displayed. Age, sex were used as covariates. The smoothing kernel was 8 mm.