



HAL
open science

Monitoring brain tumor evolution using multiparametric MRI

Benjamin Lemasson, Nora Collomb, Alexis Arnaud, Florence Forbes,
Emmanuel L. Barbier

► **To cite this version:**

Benjamin Lemasson, Nora Collomb, Alexis Arnaud, Florence Forbes, Emmanuel L. Barbier. Monitoring brain tumor evolution using multiparametric MRI. 2017 IEEE International Symposium on Biomedical Imaging, Apr 2017, Melbourne, Australia. hal-01652026

HAL Id: hal-01652026

<https://inria.hal.science/hal-01652026>

Submitted on 29 Nov 2017

HAL is a multi-disciplinary open access archive for the deposit and dissemination of scientific research documents, whether they are published or not. The documents may come from teaching and research institutions in France or abroad, or from public or private research centers.

L'archive ouverte pluridisciplinaire **HAL**, est destinée au dépôt et à la diffusion de documents scientifiques de niveau recherche, publiés ou non, émanant des établissements d'enseignement et de recherche français ou étrangers, des laboratoires publics ou privés.

Monitoring brain tumor evolution using multiparametric MRI

B. Lemasson, N. Collomb, A. Arnaud, F. Forbes, and E.L. Barbier

Abstract— Analysing brain tumor tissue composition can improve the handling of tumor growth and resistance to therapies. We show on a 6 time point dataset of 8 rats that multiparametric MRI can be exploited via statistical clustering to quantify intra-lesional heterogeneity in space and time.

I. INTRODUCTION

MRI can be used to map structural, eg diffusion, as well as functional, eg volume (BVf), vessel size (VSI), oxygen saturation of the tissue (StO₂), characteristics. In (1), these parameters were analyzed to show the great potential of multiparametric MRI (mpMRI) to monitor combined radio- and chemo-therapies. However, to exploit all the information contained in mpMRI while preserving information about tumor heterogeneity, new methods need to be developed. We demonstrate the ability of clustering analysis (2) applied to longitudinal mpMRI to summarize and quantify intra-lesional heterogeneity during tumor growth.

II. METHODS

Tumors (9L) were implanted in 8 rats and imaging was performed every 2 days (D7 to 17) post tumor implantation. The following *mpMRI* was acquired: a T2-weighted spin echo, a diffusion weighted EPI for the Apparent Diffusion Coefficient (ADC) and multiple spin/gradient echo to map T2 and T2*. A Gradient Echo Sampling of the FID and Spin Echo (GESFIDE) was acquired pre- and post-injection of USPIO. A dynamic contrast enhancing sequence was acquired using a RARE sequence. Gadolinium-chelate was administered after the acquisition of 4 images. BVf and VSI were computed as in (3), and StO₂ as in (4). The vessel permeability map (Perm) was calculated as the percentage of enhancement within 3min post injection of gadolinium. Each map was co-registered to that at the previous time point. Tumors were delineated using the T2w images (Fig1-A). **Cluster analysis:** voxels in the ROI were clustered with a Gaussian mixture model with 5 clusters (K1 to K5) selected with the Bayesian Information Criterion.

III. RESULTS AND CONCLUSION

Fig1-A shows the clusters for one rat, Fig1-B the evolution of the mean cluster volumes and Fig.1-C that of the clusters in 2 rats with slow (top) and high (top) tumor growth rates.

*MRI facility IRMaGe was partly funded by Grant ANR-11-INBS-0006. BL received a stipend from *Ligue contre le cancer* and from *Fondation ARC*. B.L., N.C. and E.B. are with U836 Inserm and University Grenoble Alpes, Grenoble Institut des neurosciences, Grenoble, France. A.A. and F.F. are with Inria and University Grenoble Alpes, LJK, Grenoble, France.

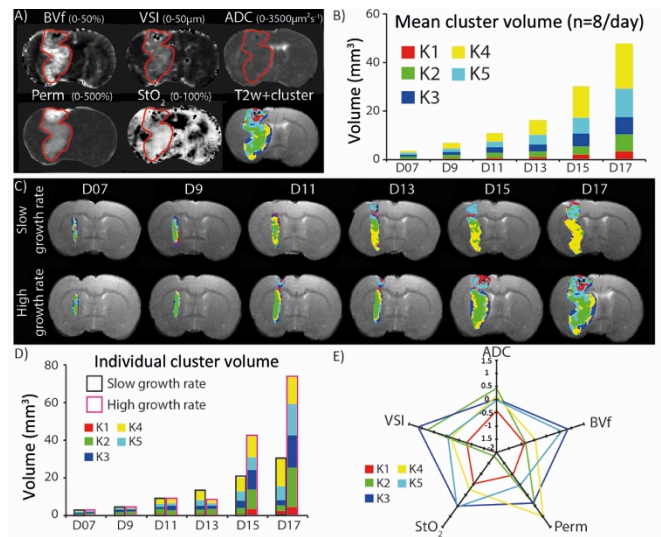


Figure 1. A) 1 rat: tumor (red line) and clustering. B) All rats: mean cluster volumes at each time. 2 rats, slow (top) and high (bottom) tumor growth: clustering (C) and volumes (D). E) MR parameters for each cluster.

The clustering is spatially consistent at each time point but also over time: eg. the green cluster is mostly located in the center of the tumor (Fig1-C). Our result shows a difference in cluster composition between the slow and the high growth rate tumors (Fig.1-C, D). In the slow rate tumor, the yellow cluster takes more space overtime (up to 49% at D17) whereas for the high rate, it is the green one. The main difference between these clusters is the strong reduction in StO₂ in the green one (cf. Fig.1-E).

This study shows the interest of a clustering analysis on mpMRI data to monitor the evolution of brain tumor heterogeneity. It highlights the type of tissue that mostly contributes to tumor development and could be used to refine the evaluation of therapies and to improve tumor prognosis.

REFERENCES

- [1] B. Lemasson et al. Multiparametric MRI as an early biomarker of individual therapy effects during concomitant treatment of brain tumours. *NMR Biomed.* 2015;28(9):1163-73. Epub 2015/08/01.
- [2] N. Coquery et al. Microvascular MRI and unsupervised clustering yields histology-resembling images in two rat models of glioma. *J Cereb Blood Flow Metab.* 2014;34(8):1354-62. Epub 2014/05/23.
- [3] Tropres I, et al. Vessel size imaging. *Magn Reson Med.* 2001;45(3).
- [4] Christen T, et al. Evaluation of a quantitative blood oxygenation level-dependent (qBOLD) approach to map local blood oxygen saturation. *NMR Biomed.* 2011;24(4):393-403. Epub 2010/10/21.