



HAL
open science

Semantic Modelling of Coronary Vessel Structures in Computer Aided Detection of Pathological Changes

Mirosław Trzupek

► **To cite this version:**

Mirosław Trzupek. Semantic Modelling of Coronary Vessel Structures in Computer Aided Detection of Pathological Changes. 1st Availability, Reliability and Security (CD-ARES), Aug 2011, Vienna, Austria. pp.220-227, 10.1007/978-3-642-23300-5_17. hal-01590386

HAL Id: hal-01590386

<https://inria.hal.science/hal-01590386>

Submitted on 19 Sep 2017

HAL is a multi-disciplinary open access archive for the deposit and dissemination of scientific research documents, whether they are published or not. The documents may come from teaching and research institutions in France or abroad, or from public or private research centers.

L'archive ouverte pluridisciplinaire **HAL**, est destinée au dépôt et à la diffusion de documents scientifiques de niveau recherche, publiés ou non, émanant des établissements d'enseignement et de recherche français ou étrangers, des laboratoires publics ou privés.



Distributed under a Creative Commons Attribution 4.0 International License

Semantic modelling of coronary vessel structures in computer aided detection of pathological changes

Mirosław Trzupek¹

¹ AGH University of Science and Technology, Institute of Automatics, 30 Mickiewicza Ave,
30-059 Kraków, Poland
mtrzupek@agh.edu.pl

Abstract. In the paper, the author discusses the results of his research on the opportunities for using selected artificial intelligence methods to semantically analyse medical images. In particular, he will present attempts at using linguistic methods of structural image analysis to develop systems for the cognitive analysis and understanding of selected medical images, and this will be illustrated by the recognition of pathological changes in coronary arteries of the heart. The problem undertaken is important because the identification and location of significant stenoses in coronary vessels is a widespread practical task. The obtained results confirm the importance of the proposed methods in the diagnosis of coronary heart disease.

Keywords: Intelligent medical image processing and understanding, spatial modelling of coronary vessels, computer-aided diagnosis.

1 Introduction

Coronary Heart Disease (CHD) is the leading cause of death in developed countries and at the same time constitutes a crucial diagnostic problem of the 21st century. Every year, over 19 million people globally suffer sudden, severe coronary incidents. Early diagnosis and risk assessment are widely accepted strategies to combat CHD [1]. The impressive technological progress in medical image diagnostics and the wide opportunities for 3D visualization of human organs have significantly improved the efficiency of medical diagnostic tasks. The 3D reconstructions of examined medical structures [2] obtained by rendering make it possible to truly represent the selected organ (including the changes in its texture), allowing its external and internal morphology to be observed precisely. Such high technologies of image processing [3] are today used in almost all types of diagnostic examinations based on digital technologies and of surgical jobs performed with the use of medical robots. As a result, it has become possible to identify a greater number of qualitative parameters of the examined structure which may be significant for making the correct diagnosis, and which could not be identified if the examination was made using a conventional method (2D imaging) [4]. However, all these achievements in the visualization technology field offer limited opportunities for automating the interpretation of the diagnostic images acquired. This is mainly due to the difficulties which informatics

encounters in formally describing and modelling complex thought processes taking place in the human mind which enable the semantic interpretation of analyzed medical images. Such intelligent IT systems supporting the thought processes of a physician analyzing complex cases simply have not been developed yet. There are, however, tools which support the work of a diagnostician by making quantitative measurements of pathologies depicted in the image [5], [6], which obviously makes his/her work easier, but only understanding the essence of the disease process allows the appropriate diagnosis to be made and the correct therapy to be prescribed.

2 The problem of analysis and understanding of medical images

One of the main difficulties in developing universal, intelligent systems for medical image diagnostics is the huge variety of images, both healthy and pathological, which have to be taken into account when intelligently supporting physicians interpreting them. In particular, the aforementioned varied shapes of morphological elements make it difficult to create a universal pattern defining the model shape of a healthy organ, or a pathological one. On the other hand, a computer using the well-known and frequently used techniques of automatic image recognition needs such a pattern to be provided to it. This is because the information technologies applied rely to a significant extent on intuition to determine the measure of similarity between the currently considered case and such an abstract pattern. These technologies frequently fail if there are unexpected changes to the shapes of analysed organs caused by the disease process or individual variability. All of this means that attempts to effectively assess the morphology using computer software are very complicated and frequently outright impossible, because there are too many cases that would have to be analysed to unambiguously determine the condition of the structure being examined. For this reason it is necessary to use those advanced artificial intelligence techniques and computational intelligence techniques that can generalize the recorded image patterns. What is particularly important is to use intelligent description methods that would ignore individual characteristics of the patient examined and characteristics dependent on the specific form of the disease unit considered, while at the same time making it possible to locate significant morphology changes and also to interpret and determine their diagnostic significance. Such methods, aimed at focusing the image description on diagnostically significant properties to the maximum extent can then be used in intelligent computer-aided diagnostics systems.

3 Methodology

Research work was conducted on images from diagnostic examinations made using SOMATOM Sensation Cardiac 64 tomograph [7] in the form of animations saved as AVI (MPEG4) files with the 512x512 pixel format. Such sequences were obtained for various patients and present in a very clear manner all morphologic changes of individual sections of arteries in any plane. Coronary vessels were visualized without the accompanying muscle tissue of the heart. Since image data has been saved in the

form of animations showing coronary vessels in various projections, for the further analyses should be selected the appropriate projection which will show the examined coronary vessels in the most transparent form most convenient for analysis. In the research work, attempts were made to automate the procedure of finding such a projection by using selected geometric transformations during image processing. Using the fact that the spatial layout of an object can be determined by projecting it onto the axes of the Cartesian coordinate system, values of horizontal Feret diameters [8], which are a measure of the horizontal extent of the diagnosed coronary artery tree, are calculated for every subsequent animation frame. The projection for which the horizontal Feret diameter is the greatest is selected for further analyses.

To help represent the examined structure of coronary vascularisation with a graph, it is necessary to define primary components of the analyzed image and their spatial relations, which will serve to extract and suitably represent the morphological characteristics significant for understanding the pathology shown in the image. It is therefore necessary to identify individual coronary arteries and their mutual spatial relations. To ease this process, the projection selected for analyzing was skeletonised by the Pavlidis skeletonising algorithm [9] (it leaves the fewest apparent side branches in the skeleton and the lines generated during the analysis are only negligibly shortened at their ends). This gives us the skeleton of the given artery which is much thinner than the artery itself, but fully reflects its topological structure (fig. 1.). Skeletonising is aimed only at making it possible to find points where artery sections intersect or end in the vascularisation structures and then to introduce an unambiguous linguistic description of individual coronary arteries and their branches. These points will constitute the vertices of a graph modelling the spatial structure of the coronary vessels. The next step is labelling them by giving each located informative point the appropriate label from the set of vertex labels (this set comprises abbreviated names of arteries found in coronary vascularisation). If a given informative point is a branching point, then the vertex will be labelled with the concatenation of names of the vertex labels of arteries which begin at this point. This way, all initial and final points of coronary vessels as well as all points where main vessels branch into lower level vessels have been determined and labelled as appropriate. After this operation, the coronary vascularisation tree is divided into sections which constitute the edges of a graph modelling the examined coronary arteries. This makes it possible to formulate a description in the form of edge labels which determine the mutual spatial relations between the primary components, i.e. between subsequent arteries shown in the analysed image.

Mutual spatial relations that may occur between elements of the vascular structure represented by a graph are described by the set of edges. The elements of this set have been defined by introducing the appropriate spatial relations: vertical - defined by the set of labels $\{\alpha, \beta, \dots, \mu\}$ and horizontal - defined by the set of labels $\{1, 2, \dots, 24\}$ on a hypothetical sphere surrounding the heart muscle. These labels designate individual final intervals, each of which has the angular spread of 15° . Then, depending on the location, terminal edge labels are assigned to all branches identified by the beginnings and ends of the appropriate sections of coronary arteries (fig. 1). The presented methodology draws upon the method of determining the location of a point on the surface of our planet in the system of geographic coordinates, where a similar cartographic projection is used to make topographic maps. This representation of

mutual spatial relations between the analysed arteries yields a convenient access to the unambiguous description of all elements of the vascular structure. At subsequent analysis stages, this description will be correctly formalised using ETPL(k) (Embedding Transformation-preserved Production-ordered k-Left nodes unambiguous) graph grammar G defined in [10], [11], supporting the search for stenoses in the lumen of arteries forming parts of the coronary vascularisation. Grammar G generates the language $L(G)$ in the form of IE (indexed edge-unambiguous) graphs which can unambiguously represent 3D structures of heart muscle vascularisation visualised in images acquired during diagnostic examinations with the use of spiral computed tomography. Quoted below (1) is the formal definition of the IE graph [10], [11].

$$H=(V, E, \Sigma, \Gamma, \Phi) \quad (1)$$

where:

V is a finite, non-empty set of graph node with unambiguously assigned indices

Σ is a finite, non-empty set of node labels

Γ is a finite, non-empty set of edge labels

E is a set of graph edges in the form of (v, λ, w) , where $v, w \in V, \lambda \in \Gamma$ and the index v is smaller than the index w

$\varphi: V \rightarrow \Sigma$ is a function of node labelling

After applying the presented methodology, a graph model representing the coronary arteries on the CT images was obtained (fig. 1.).

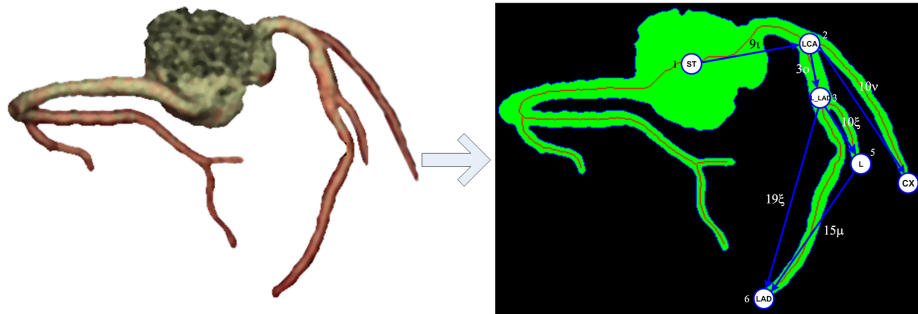


Fig. 1. The representation of the left coronary artery using IE graph.

Due to the fact that in obtained during diagnostic examination visualisations of coronary vascularisation, we can distinguish three different types of topologies, characteristic for these vessels, therefore, for each of the three types of topology, appropriate type of ETPL(k) graph grammars can be proposed. Each grammar generate IE graphs language, modelling particular types of coronary vascularisation. This representation was then subjected to a detailed analysis, to find the places of morphological changes indicating occurrence of pathology. This operation consists of several stages, and uses, among others context-free sequential grammars, used successfully for the detection of lesions in coronary planar images [12]. Next steps in

the analysis of the example coronary artery are shown in fig. 2. Artery with the vertices $L_LAD_3 - LAD_6$ represented by the edge 19ξ of the IE graph has been subjected to the operation of the straightening transformation [12], which allows to obtain the width diagram of the analyzed artery, while preserving all its properties, including potential changes in morphology. In addition, such representation allows to determine the nature of the narrowing (concentric or eccentric). Concentric stenoses occur on a cross-section as a uniform stricture of the whole artery (this symptom is characteristic for a stable disturbance of heart rhythm), whereas eccentric stenoses occur only on one vascular wall (an unstable angina pectoris) [13]. Analysis of morphological changes was conducting based on the obtained width diagrams, and using context-free attributed grammars [12]. As a result of carried out operations the profile of the analyzed coronary artery with marked areas of existing pathology, together with the determination of the numerical values of their advancement level was obtained (fig. 2). Methodology presented above was implemented sequentially to the individual sections of coronary vascularisation represented by the particular edges of the introduced graph representation.

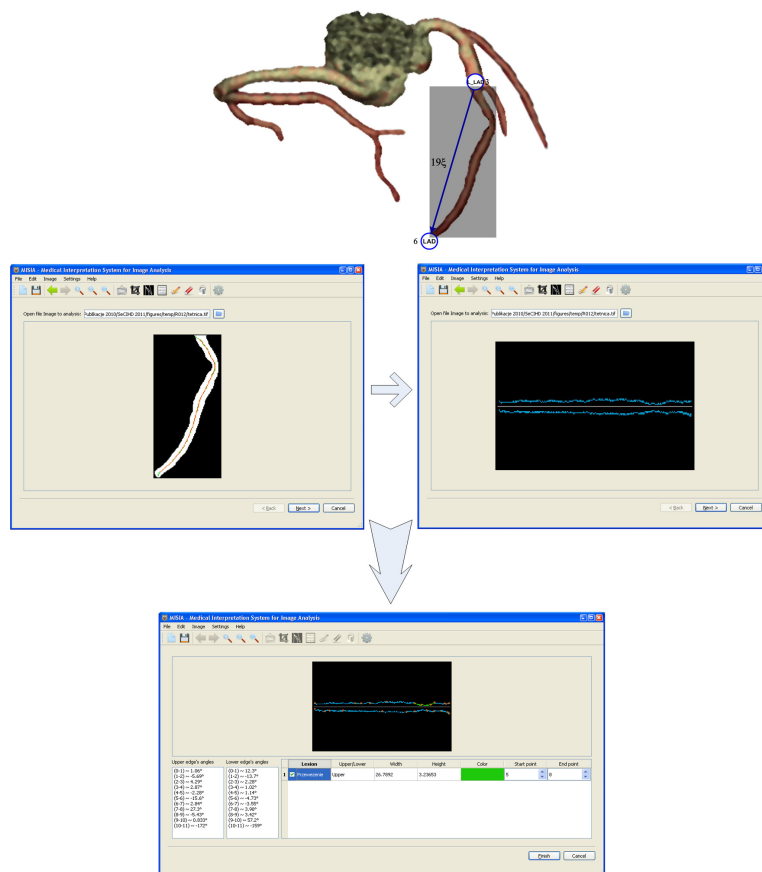


Fig. 2. Next steps in the analysis and recognition of pathological changes occurring on the example of the left coronary artery.

4 Results

The set of test images, which has been used to determine the efficiency of the proposed methods consisted of 20 complete reconstructions of coronary vascularisation obtained during diagnostic examinations of various patients, mainly suffering from coronary heart disease at different progression stages. These images were obtained during diagnostic examinations with 64-slice spiral computed tomography. Due to the different types of topologies of coronary vascularisation, the set of analyzed images consisted of three basic types (balanced artery distribution, right artery dominant, left artery dominant). Structure of the coronary vascularisation was determined by a diagnostician at the stage of acquisition of image data. This distinction was intended to obtain additional information about the importance of providing health risks of the patient depending on the place where pathology occurs in the type of coronary vascularisation. The test data also consisted of visualisations previously used to construct the grammar and the syntactic analyser. To avoid analysis of images that were used to construct the set of grammatical rules, from the same sequences frames were selected that were several frames later than the projections used to construct the set of grammatical rules, and these later frames were used for the analysis. The above set of image data was used to determine the percentage efficiency of correct recognitions of the stenoses present, using the methodology proposed here. The recognition consists in identifying the locations of stenoses, their number, extent and type (concentric or eccentric). For the research data included in the experiment, 85% of recognitions were correct. This value is the percentage proportion of the number of images in which the occurring stenoses were correctly located, measured and properly interpreted to the number of all analysed images included in the experimental data set. No indication of major differences in the effectiveness evaluation, depending on the structure of the coronary vascularisation is noticed. In order to assess whether the size of the stenosis was correctly measured, comparative values from the syngo Vessel View software forming part of the HeartView CI suite were used. This program is used in everyday clinical practice where examinations are made with the SOMATOM Sensation Cardiac 64 tomograph [7]. In order to confirm or reject the regularity of the stenosis type determination (concentric or eccentric) shown in the examined image, a visual assessment was used, because the aforementioned programs did not have this functionality implemented. As the set of test data was small the results obtained are very promising. Further research on improving the presented analysis techniques of lesions occurring in the morphology of coronary vessels might bring about a further improvement in the effectiveness and the future standardisation of these methods, obviously after they have first been tested on a much more numerous image data set.

5 Conclusions

The obtained results show that graph languages for describing shape features can be effectively used to describe 3D reconstructions of coronary vessels and also to formulate semantic meaning descriptions of lesions found in these reconstructions [14], [15]. Such formalisms, due to their significant descriptive power (characteristic especially for graph grammars) can create models of both examined vessels whose morphology shows no lesions and those with visible lesions bearing witness to early or more advanced stages of the ischemic heart disease. In addition, by introducing the appropriate spatial relations into the coronary vessel reconstruction, it is possible to reproduce their biological role, namely the blood distribution within the whole coronary circulation system, which also facilitates locating and determining the progression stage of lesions. The research also has shown that one of the hardest tasks leading to the computer classification and then the semantic interpretation of medical visualisations is to create suitable representations of the analysed structures and propose effective algorithms for reasoning about the nature of pathologies found in these images. Visualisations of coronary vascularisation are difficult for computers to analyse due to the variety of projections of the arteries examined. Problems related to automating the process of generating new grammars for cases not included in the present language remain unsolved in the on-going research. However, it is worth noting that generally, the problem of deriving grammatical rules is considered unsolvable, particularly for graph grammar. It can appear if the image undergoing the analysis shows a coronary vascularisation structure different from the so far assumed three cases of vessel topologies occurring the most often, i.e. the balanced distribution of arteries, the dominant right artery or the dominant left artery. In those cases it will be necessary to define a grammar taking this new case into account. The processes of creating new grammars and enriching existing ones with new description rules will be followed in further directions of research on the presented methods.

Acknowledgments. This work has been supported by the Ministry of Science and Higher Education, Republic of Poland, under project number N N516 478940.

References

1. Yusuf, S., Reddy, S., Ounpuu, S., Anand, S.: Global burden of cardiovascular diseases, Part I. General considerations, the epidemiologic transition, risk factors, and impact of urbanization. *Circulation*;104: 2746-2753 (2001)
2. Lewandowski, P., Tomczyk, A., Szczepaniak, P.S.: Visualization of 3-D Objects in Medicine - Selected Technical Aspects for Physicians. *Journal of Medical Informatics and Technologies* 11:59-67 (2007)
3. Sonka, M., Fitzpatrick, J.M.: *Handbook of Medical Imaging - Volume 2. Medical Image Processing and Analysis*, SPIE, Bellingham, Washington (2004)
4. Katritsis, D.G., Pantos, I., Efstathopoulos, E.P., et al.: Three-dimensional analysis of the left anterior descending coronary artery: comparison with conventional coronary angiograms. *Coronary Artery Disease* 19(4):265-270 (2008)

5. Wang Yin, Liatsis, P.: A Fully Automated Framework for Segmentation and Stenosis Quantification of Coronary Arteries in 3D CTA Imaging. *dese, Second International Conference on Developments in eSystems Engineering*, pp.136-140 (2009)
6. Oncel, D., Oncel, G., Tastan, A., Tamci, B.: Detection of significant coronary artery stenosis with 64-section MDCT angiography. *European Journal of Radiology Jun;62(3)*, 394-405 (2007)
7. SOMATOM Sensation Cardiac 64 Brochure.: Get the Entire Picture. Siemens medical (2004)
8. Tadeusiewicz, R., Korohoda, P.: *Computer Analysis and Image Processing* (in Polish). Foundation of Progress in Telecommunication, Kraków (1997)
9. Pavlidis, T.: *Algorithms for graphics and image processing*. Rockville Computer Science Press (1982)
10. Tadeusiewicz, R., Flasiński, M.: *Pattern Recognition* (in Polish). PWN, Warsaw (1991)
11. Skomorowski, M.: *A Syntactic-Statistical Approach to Recognition of Distorted Patterns*. Jagiellonian University, Krakow (2000)
12. Tadeusiewicz, R., Ogiela, M.R.: *Medical Image Understanding Technology*, Springer Verlag, Berlin-Heidelberg (2004)
13. Faergeman, O.: *Coronary Artery Disease*, Elsevier (2003)
14. Ogiela, M.R., Tadeusiewicz, R., Trzupek, M.: Picture grammars in classification and semantic interpretation of 3D coronary vessels visualisations. *Opto-Electronics Review*. Vol. 17 no. 3 p. 200-210 (2009)
15. Trzupek, M, Ogiela, MR, Tadeusiewicz, R.: Image content analysis for cardiac 3D visualizations. *Knowledge-based and intelligent information and engineering systems : 13th international conference, KES 2009 : Santiago, Chile, September 28-30, 2009 : proceedings, Part 1 / eds. Juan D. Velásquez, [et al.] eds. R. Goebel, J. Siekmann, W. Wahlster LNAI 5711 p. 192-199* (2009)