



HAL
open science

A New Fire Hazard for MR Imaging Systems: Blankets-Case Report

Anne Bertrand, Sandrine Brunel, Marie-Odile Habert, Marine Soret, Simone Jaffre, Nicolas Capeau, Laetitia Bourseul, Isabelle Dufour-Claude, Aurélie Kas, Didier Dormont

► **To cite this version:**

Anne Bertrand, Sandrine Brunel, Marie-Odile Habert, Marine Soret, Simone Jaffre, et al.. A New Fire Hazard for MR Imaging Systems: Blankets-Case Report. *Radiology*, 2018, 286 (2), pp.568-570. 10.1148/radiol.2017162921 . hal-01580514

HAL Id: hal-01580514

<https://inria.hal.science/hal-01580514>

Submitted on 4 Sep 2017

HAL is a multi-disciplinary open access archive for the deposit and dissemination of scientific research documents, whether they are published or not. The documents may come from teaching and research institutions in France or abroad, or from public or private research centers.

L'archive ouverte pluridisciplinaire **HAL**, est destinée au dépôt et à la diffusion de documents scientifiques de niveau recherche, publiés ou non, émanant des établissements d'enseignement et de recherche français ou étrangers, des laboratoires publics ou privés.



Distributed under a Creative Commons Attribution - NonCommercial - ShareAlike 4.0 International License

A New Fire Hazard for MR Imaging Systems: Blankets—Case Report¹

Anne Bertrand, MD, PhD
 Sandrine Brunel, BS
 Marie-Odile Habert, MD
 Marine Soret, PhD
 Simone Jaffre, RN
 Nicolas Capeau, BS
 Laetitia Bourseul, BS
 Isabelle Dufour-Claude, PhD
 Aurélie Kas, MD, PhD
 Didier Dormont, MD, PhD

In this report, a case of fire in a positron emission tomography (PET)/magnetic resonance (MR) imaging system due to blanket combustion is discussed. Manufacturing companies routinely use copper fibers for blanket fabrication, and these fibers may remain within the blanket hem. By folding a blanket with these copper fibers within an MR imaging system, one can create an electrical current loop with a major risk of local excessive heating, burn injury, and fire. This hazard applies to all MR imaging systems. Hybrid PET/MR imaging systems may be particularly vulnerable to this situation, because blankets are commonly used for fluorodeoxyglucose PET to maintain a normal body temperature and to avoid fluorodeoxyglucose uptake in brown adipose tissue.

© RSNA, 2017

¹ From the Department of Neuroradiology, AP-HP Hôpital Pitié-Salpêtrière, Boulevard de l'Hôpital, 75013 Paris, France (A.B., D.D.); Sorbonne Universités, UPMC Univ Paris 06, Inserm, CNRS, Institut du Cerveau et la Moelle (ICM), AP-HP-Hôpital Pitié-Salpêtrière, Paris, France (A.B., D.D.); Aramis Project Team, Inria Paris, Paris, France (A.B., D.D.); Department of Nuclear Medicine, AP-HP Hôpital Pitié-Salpêtrière, Boulevard de l'Hôpital, F-75013, Paris, France (S.B., M.O.H., M.S., S.J., A.K.); Biomedical Department, AP-HP Hôpital Pitié-Salpêtrière, Boulevard de l'Hôpital, F-75013, Paris, France (N.C., L.B.); and GE Healthcare, Buc, France (I.D.C.). Received December 22, 2016; revision requested February 13, 2017; revision received May 9; accepted May 15; final version accepted June 8. **Address correspondence to** D.D. (e-mail: didier.dormont@aphp.fr).

© RSNA, 2017

Magnetic resonance (MR) imaging examinations have been associated with a number of potentially life-threatening health risks, one being the risk of excessive tissue heating and severe burn injuries because of radiofrequency (RF) energy transmission (1). Safety recommendations before MR imaging examination include the removal of any metal-containing device (wires, electrocardiography leads, skin patches), the use of metal-free clothes such as hospital garments, the correct positioning of the patient's body to avoid conductive loops, and careful isolation of the patient from the RF coil with appropriate padding (2,3). However, padding itself can create a burn hazard if the cloth contains traces of metal. Here we report a case of fire due to combustion of a blanket during a positron emission tomography (PET)/MR imaging examination, which was caused by the presence of a copper fiber related to the routine technique of blanket fabrication.

Case Report

A 62-year-old woman with clinical suspicion of logopenic aphasia and no noticeable medical history apart from a chronic loss of smell was referred to our department for a PET/MR imaging examination on August 2, 2016. Our PET/MR imaging system (Signa PET/MR; GE, Buc, France) had been installed on October 2, 2015, and 881 clinical examinations had been previously performed without any adverse incident. Patient preparation took place by using the following routine procedure: she was injected with 2 MBq/kg of fluorine 18 fluorodeoxyglucose and placed in a dark, silent room for 30 minutes with a blanket to maintain normal body temperature while awaiting her examination. The blanket was one of the hospital blankets, which have been produced for 15 years by the same industrial manufacturer (Poyet-Motte,

Cours-la-Ville, France). The patient was subsequently transferred to the PET/MR imaging unit and positioned with her arms along the body and her legs side by side. A large 50-cm strap was placed around her body and the blanket was placed above the strap. The PET/MR imaging examination was performed for 20 minutes with the usual routine protocol (three-dimensional T1-weighted imaging, three-dimensional fluid attenuated inversion recovery imaging, three-dimensional susceptibility-weighted sequences, and diffusion-weighted imaging with fluorodeoxyglucose PET images acquired simultaneously). At the end of the examination, the technician entered the room and noticed a strong burning odor related to the combustion of the blanket, which she quickly removed from the patient.

The patient had no skin lesions because she did not have any direct contact with the blanket. The antenna and the inner shell of the PET/MR imaging unit were deformed and covered with soot (Fig, A). Careful inspection of the blanket revealed the presence of a metallic fiber (Fig, B and C). Material safety investigation revealed that these copper fibers were used by the blanket manufacturer during the automatic process of blanket cutting and remained within the blanket hem. Noticeably, this technique does not appear to be specific to our manufacturer and was also used by other companies. Systematic inspection of older blankets at our hospital did not reveal the presence of copper fibers because this technique of production was recently implemented. The manufacturer was informed and modified the production line so that copper fibers were not used anymore. Radiology technicians and radiologists at the hospital were informed of the incident and were asked to stop using blankets inside MR imaging units. An

alert was sent to the French National Agency for Medicines and Health Products Safety and also to the other hospitals in our group (Assistance Publique-Hôpitaux de Paris), in which similar blankets were used. To our knowledge, this type of adverse event had never been recorded previously.

Discussion

Burn injury is a severe adverse event that can occur during an MR imaging examination. When RF energy is transmitted from the transmit RF coil to the patient, it also creates an electrical current within the conducting materials present in the RF field. If an electrical loop occurs, then RF-induced electrical currents can cause excessive heating and adjacent tissue damage. Although most metallic materials (electrocardiography cables, wires, jewelry) are easily detected and removed by the radiology technicians, they may also be present in other unexpected devices such as drug patches (4), identification bracelets (5), or even microfiber undershirts containing silver particles (6). All of these materials have been reported to cause severe skin damage during an MR imaging examination. To prevent direct burns, it is also recommended to isolate the patient's body from the RF coils by using clothing, sheets, and padding (2).

Blankets can sometimes be used during MR imaging examinations to

Advance in Knowledge

- The use of a blanket containing copper fibers during an MR imaging examination caused a fire.

Implication for Patient Care

- Manufactured blankets may occasionally contain copper fibers; such blankets should be strictly avoided in MR imaging units.

<https://doi.org/10.1148/radiol.2017162921>

Content code: **MR** **GI**

Radiology 2017; 000:1–3

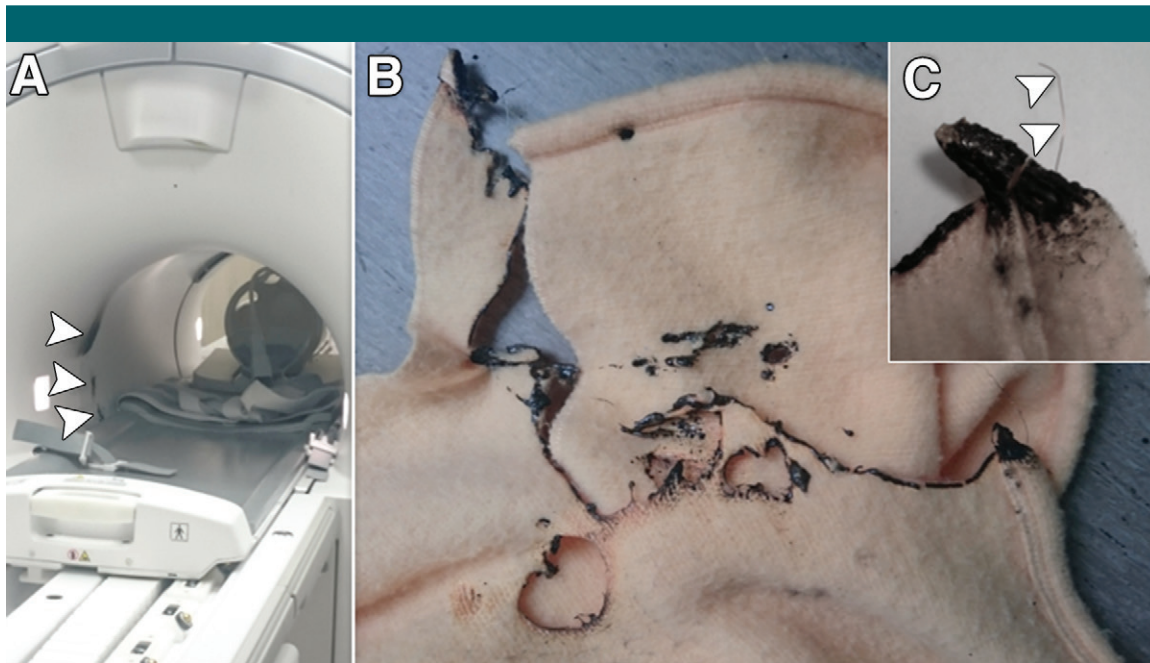
Abbreviation:

RF = radiofrequency

Author contributions:

Guarantors of integrity of entire study, A.B., I.D.C., A.K.; study concepts/study design or data acquisition or data analysis/interpretation, all authors; manuscript drafting or manuscript revision for important intellectual content, all authors; approval of final version of submitted manuscript, all authors; agrees to ensure any questions related to the work are appropriately resolved, all authors; literature research, A.B., D.D.; clinical studies, S.B., M.S., N.C., L.B., D.D.; and manuscript editing, A.B., M.O.H., S.J., N.C., I.D.C., A.K., D.D.

Conflicts of interest are listed at the end of this article.



Images show traces of smoke inside the, *A*, 3.0-T PET/MR imaging unit (arrowheads) related to, *B*, the combustion of a blanket due to the presence of, *C*, a small copper filament (arrowheads).

isolate the patient's body from the RF coils. During fluorodeoxyglucose PET imaging, blankets are routinely used to maintain a normal body temperature, thus avoiding hypothermia-related uptake of fluorodeoxyglucose in brown adipose tissue, which may induce artifactual hypometabolism of the brain (7). Noticeably, this incident occurred in our PET/MR imaging system after 10 months of use and 881 unremarkable examinations with a similar procedure. Hence, the creation of an electrical loop in the blanket requires that the blanket folding has a specific orientation, creating an almost closed loop that likely did not occur during previous examinations. The incident was not noticed until the end of the PET/MR imaging acquisition because the blanket was smoldering without flames, and also because the patient happened to have chronic loss of smell and did not notice a burnt odor in the room. This incident could have had dramatic consequences if the patient had not been protected by the 50-cm-long restraining strap between her and the blanket.

To conclude, we have shown that the use of a blanket containing copper fibers within an MR imaging unit may present a major fire hazard because of the potential for creating electrical current loops. When isolating the patient from RF coils, disposable linens should be preferred to blankets unless the absence of metallic fiber can be assessed.

Disclosures of Conflicts of Interest: **A.B.** Activities related to the present article: disclosed no relevant relationships. Activities not related to the present article: author reported grants from Agence Nationale pour la Recherche and Institut Hospitalo-Universitaire. Other relationships: disclosed no relevant relationships. **S.B.** disclosed no relevant relationships. **M.O.H.** Activities related to the present article: disclosed no relevant relationships. Activities not related to the present article: author reported payments for lectures from Piramal and Lilly. Other relationships: disclosed no relevant relationships. **M.S.** disclosed no relevant relationships. **S.J.** disclosed no relevant relationships. **N.C.** disclosed no relevant relationships. **L.B.** disclosed no relevant relationships. **I.D.C.** disclosed no relevant relationships. **A.K.** disclosed no relevant relationships. **D.D.** Activities related to the present article: disclosed no relevant relationships. Activities not related to the present article: author reported nonfinancial support from Bracco Imaging France. Other relationships: disclosed no relevant relationships.

References

1. Hardy PT 2nd, Weil KM. A review of thermal MR injuries. *Radiol Technol* 2010;81(6):606–609.
2. Tsai LL, Grant AK, Mortelet KJ, Kung JW, Smith MP. A practical guide to MR imaging safety: what radiologists need to know. *RadioGraphics* 2015;35(6):1722–1737.
3. Shellock FG, Crues JV. MR procedures: biologic effects, safety, and patient care. *Radiology* 2004;232(3):635–652.
4. Aluminium-containing transdermal patches: a risk of burns. *Prescrire Int* 2007;16(92):246.
5. Jacob ZC, Tito MF, Dagum AB. MR imaging-related electrical thermal injury complicated by acute carpal tunnel and compartment syndrome: case report. *Radiology* 2010;254(3):846–850.
6. Pietryga JA, Fonder MA, Rogg JM, North DL, Bercovitch LG. Invisible metallic microfiber in clothing presents unrecognized MRI risk for cutaneous burn. *AJNR Am J Neuro-radiol* 2013;34(5):E47–E50.
7. Surasi DS, Bhambhani P, Baldwin JA, Almodovar SE, O'Malley JP. ¹⁸F-FDG PET and PET/CT patient preparation: a review of the literature. *J Nucl Med Technol* 2014;42(1):5–13.