



HAL
open science

Automated Evaluation of Retinopathies Using Image Cytometry

K. Staniszewski, R. Sepehr, S. Maleki, C. M. Sorenson, N. Sheibani, M. Ranji

► **To cite this version:**

K. Staniszewski, R. Sepehr, S. Maleki, C. M. Sorenson, N. Sheibani, et al.. Automated Evaluation of Retinopathies Using Image Cytometry. 3rd Doctoral Conference on Computing, Electrical and Industrial Systems (DoCEIS), Feb 2012, Costa de Caparica, Portugal. pp.579-582, 10.1007/978-3-642-28255-3_64 . hal-01365779

HAL Id: hal-01365779

<https://inria.hal.science/hal-01365779v1>

Submitted on 13 Sep 2016

HAL is a multi-disciplinary open access archive for the deposit and dissemination of scientific research documents, whether they are published or not. The documents may come from teaching and research institutions in France or abroad, or from public or private research centers.

L'archive ouverte pluridisciplinaire **HAL**, est destinée au dépôt et à la diffusion de documents scientifiques de niveau recherche, publiés ou non, émanant des établissements d'enseignement et de recherche français ou étrangers, des laboratoires publics ou privés.



Distributed under a Creative Commons Attribution 4.0 International License

Automated Evaluation of Retinopathies Using Image Cytometry

K. Staniszewski¹, R. Sepehr¹, S. Maleki¹, C.M. Sorenson², N. Sheibani³, M. Ranji¹

¹ Biophotonics laboratory, University of Wisconsin Milwaukee, Department of Electrical Engineering and Computer Science, 3200 N Cramer St., Milwaukee, WI 53211, USA

² Department of Pediatrics, University of Wisconsin School of Medicine and Public Health, 600 Highland Avenue, Madison, WI, 53792-4673, USA

³ Department of Ophthalmology and Visual Sciences, University of Wisconsin School of Medicine and Public Health, 600 Highland Avenue, Madison, WI, 53792-4673, USA

{kevinss2, rsepehr, maleki, ranji}@uwm.edu, {cmsorenson, nsheibanikar}@wisc.edu

Abstract. Retinopathic changes are common to many ocular diseases and if detected early, much of the change caused by various injuries can be prevented or in some cases reversed. However, detection and quantification of these changes currently requires tedious invasive and manual examination of retinal wholemount images. To remedy the quantitative limitations, we have designed a software system to automatically determine the vascular cell counts and coverage of retina in wholemount trypsin digest images. To verify the utility of the system, retinal trypsin digests from wild type (bcl-2 +/+) and bcl-2 deficient (bcl-2 -/-) mice were compared. Bcl-2 is a critical regulator of apoptosis with a significant role in retinal angiogenesis and vascularization. The bcl-2 -/- mice exhibited significant reduction in retinal vascular density and complexity. Thus, our results show the potential for automated evaluation of retinal trypsin digests delineating the differences between the wild type and bcl-2-deficient retinal vasculature.

Keywords: Classification, Fractals, Retinopathy, Fluorescence Microscopy, Image Cytometry.

1 Introduction

Retinopathy can be caused by several disorders including, but not limited to, diabetes [1], hypertension [2], and age related macular degeneration [3]. The manifestation of diabetic retinopathy involves loss of existing vessels, ischemia, and growth of new abnormal blood vessels in the retina. Unfortunately, the pathology of this injury is not currently fully understood, and is currently a prominent area of research. However, detection of this injury currently relies on laborious manual analysis of retinal wholemount trypsin digests and subjective measures. Therefore, it would be beneficial to create a system to automatically and reproducibly detect these changes. With this end in mind, we have created a software package to determine retinal vascular cell density and ratios. This package is capable of analyzing bright field and

fluorescent images of the retinal vasculature for quantitative evaluations in a short period of time, facilitating faster and more reliable determination of vascular changes. In order to quantify the amount of injury experienced by the retina, the package measures the cell count and vessel coverage of high-resolution fields of view of the retinal wholemount trypsin digests, while requiring minimal input from the user.

Bright field and fluorescence images of stained wholemount retinal trypsin digests were acquired in digital formats, and the fluorescence images were thresholded using the histograms of intensity values in the fluorescent channel to separate vasculature from background. The histogram of these images showed a bimodal distribution, where the lower intensity mode corresponds to background and the higher intensity mode corresponds to the vasculature. With this in mind, the threshold level is determined independently for each image as the minimum value of the histogram (i.e. the least frequent intensity) between these two modes, leading to a binary image which contains the structure of the vasculature. The images acquired were saved as TIFF files and analyzed in MATLAB (The MathWorks).

2 Feature Extractions

Vascular Cell Detection and Count. The location of cells in each image was determined using the following segmentation algorithm. The location of foreground markers (cells) was detected by applying an FIR semi-Laplacian filter to enhance the contrast of the circular objects (using the center and surround method). The background markers were computed by applying watershed detection on the resultant binary mask of the previous stage. Then the gradient of the images is calculated and modified so that its intensity becomes zero in both foreground and background objects. The watershed transform of the modified gradient image is computed and results in a binary mask containing the borders of the objects. Automatic cell segmentation resulted in an accuracy of ~90% compared to manual cell detection and counting.

Retinal Vessel Coverage. The vessel coverage is defined as the amounts of pixels which are "on" in the thresholded image, which correspond to the area covered by the entire retinal vasculature.

3 Results

The Retinas from Bcl-2 $-/-$ Mice Have Fewer Numbers of Vascular Cells. The results shown in figure 1 indicate that those retinas from a bcl-2 $-/-$ mice contained fewer cells than the retinas from bcl-2 $+/+$ mice. The 6 week old group images contained a mean number of cells of 108.375 for the bcl-2 $-/-$ mice and 152.875 for bcl-2 $+/+$ mice ($p < 0.005$). Similarly, in the 3 week old group, the mean number of cells was 137 for bcl-2 $-/-$ mice compared with 177.75 for the bcl-2 $+/+$ mice ($p < 0.001$). Figure 1 shows the mean and standard deviations of the cell counts within each group. As expected, the mean values were higher in the bcl-2 $+/+$ group than

those in the *bcl-2*^{-/-} group, supporting the fact that the *bcl-2* gene is an apoptosis inhibitor with an important role in angiogenesis.

Wild Type Retinas have Higher Vessel Coverage. The results showed a significant difference in the 3 week old group, but a much smaller difference in the 6 week old group. In addition, the mean values of vessel caliber for the *bcl-2*^{-/-} and *bcl2*^{+/+} mice in the 3 week old group were 7.6×10^5 and 8.7×10^5 ($p < 0.05$), respectively. Figure 1 shows the mean and standard deviations of the vessel coverage.

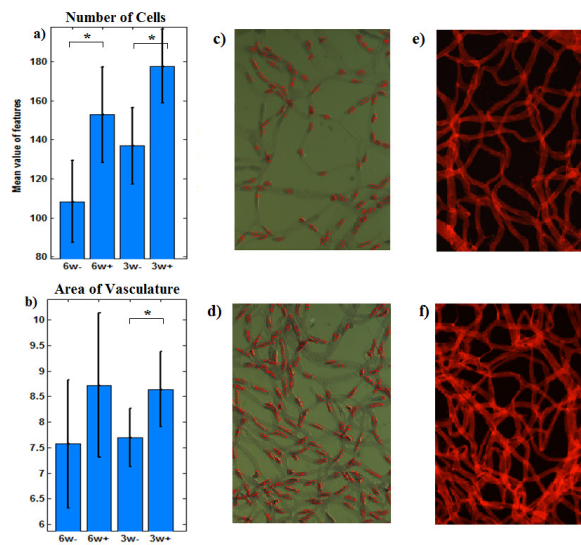


Fig.1. Mean values and Standard Deviations of Cell Counts (a) and Vasculature Area (b). Sample bright field (c and d) and fluorescence (e and f) images from 6 week old *bcl-2*^{-/-} (c and e) and 3 week *bcl-2*^{+/+} (d and f) mice. The bright field images have red lines surrounding detected cells. * indicates a significant difference ($p < 0.05$).

4 Discussion

We have developed a system capable of automatically quantifying several parameters of retinal trypsin digest images. The features used for this classification include the cell count and vasculature area. The cell count is an important indicator of retinopathy, as it is directly related to the early loss of vascular cell and later growth of new blood vessels. Therefore, we expect the concentration of cells in the retina to be a precursor to injury. Similarly, as new vessels grow, the area of the vasculature increases, so the measurement of this feature is also important.

The automated detection of the above features is important for two reasons. First, the speed of quantification capable with modern computers will allow for faster research and, therefore, sooner understanding of the causes and effects of retinopathy. Second, the automation leads to a reproducible result regardless of the person examining the retina. As previously mentioned, current measurement of these

parameters requires manual examination of these images, including counting individual cells one by one. This is not only time consuming, but is also prone to error, both of which are remedied by the automation used in this software system.

5 Conclusion

We can automatically quantify several features of the retinal vasculature with high sensitivity. This is important in understanding retinal injuries related to a wide range of diseases including diabetes, hypertension, and age related macular disease. By automatically measuring the cell count and vessel coverage of the images, we were able to show significant differences in bcl-2 deficient compared to bcl-2 +/- retinas. With the addition of more features, we hope to create a system capable of detecting very small changes in the retinal vasculature and various cell types allowing for the earliest detection of early vascular changes.

Acknowledgement: We would like to acknowledge the support of UWM research fellow award. CMS was funded, in part, by DK067120 from the National Institutes of Health and AHA research award (0950057G). NS is supported by NIH grants EY016995, and RC4 EY 021357 (NS) and an unrestricted departmental award from Research to Prevent Blindness. NS is a recipient of a Research Award from American Diabetes Association (1-10-BS-160) and Retina Research Foundation.

References

1. A. K. Sjolie, *et al.*, "Retinopathy and vision loss in insulin-dependent diabetes in Europe. The EURODIAB IDDM Complications Study," *Ophthalmology*, vol. 104, pp. 252-60, (1997)
2. B. A. Davis, *et al.*, "Prevalence of renovascular hypertension in patients with grade III or IV hypertensive retinopathy," *N Engl J Med*, vol. 301, pp. 1273-6, (1979)
3. A. C. Bird, *et al.*, "An international classification and grading system for age-related maculopathy and age-related macular degeneration. The International ARM Epidemiological Study Group," *Surv Ophthalmol*, vol. 39, pp. 367-74, (1995)
4. B. R. Masters, "Fractal analysis of the vascular tree in the human retina," *Annu Rev Biomed Eng*, vol. 6, pp. 427-52, (2004)
5. F. Family, *et al.*, "Fractal Pattern-Formation in Human Retinal-Vessels," *Physica D*, vol. 38, pp. 98-103, (1989)
6. Q. Huang, *et al.*, "PEDF-deficient mice exhibit an enhanced rate of retinal vascular expansion and are more sensitive to hyperoxia-mediated vessel obliteration," *Exp Eye Res*, vol. 87, pp. 226-41, (2008)