



**HAL**  
open science

# Development Of A Prototype Of Video Synchronisation For Relocalization Of Biopsy Sites During Endoscopic Evaluation Of Barrett's Oesophagus: Preliminary Experimental And Clinical Study

Adrien Sportes, Anant Vemuri, Stéphane Nicolau, Jerome Huppertz, Luc Soler, Michel Delvaux

► **To cite this version:**

Adrien Sportes, Anant Vemuri, Stéphane Nicolau, Jerome Huppertz, Luc Soler, et al.. Development Of A Prototype Of Video Synchronisation For Relocalization Of Biopsy Sites During Endoscopic Evaluation Of Barrett's Oesophagus: Preliminary Experimental And Clinical Study. United European Gastroenterology (UEG) Week, 2014, Vienna, Austria. 2014. hal-01310072

**HAL Id: hal-01310072**

**<https://inria.hal.science/hal-01310072v1>**

Submitted on 4 May 2016

**HAL** is a multi-disciplinary open access archive for the deposit and dissemination of scientific research documents, whether they are published or not. The documents may come from teaching and research institutions in France or abroad, or from public or private research centers.

L'archive ouverte pluridisciplinaire **HAL**, est destinée au dépôt et à la diffusion de documents scientifiques de niveau recherche, publiés ou non, émanant des établissements d'enseignement et de recherche français ou étrangers, des laboratoires publics ou privés.

A. Sportes<sup>1,2</sup>, A. Vemuri<sup>2</sup>, S. Nicolau<sup>2</sup>, J. Huppertz<sup>1</sup>, L. Soler<sup>2</sup>, M. Delvaux<sup>1,2</sup>

1. Department of Hepatogastroenterology, Nouvel Hopital Civil, University Hospital of Strasbourg, France 2. IRCAD, IHU Strasbourg

## Introduction

- The incidence of Barrett's oesophagus (BE) is increasing.
- The risk of progression to oesophageal adenocarcinoma is also increased in BE.
- Guidelines recommend an endoscopic surveillance for biopsies in patients with dysplastic changes detected by biopsies, according to the Seattle protocol.
- During the surveillance biopsies need to be repeated and targeted to the mucosal areas with dysplastic changes. The main difficulty is to clearly identify these areas from one endoscopy to the other.

## Aim

- The purpose of this study was to evaluate the prototype of a magnetic probe for accurate location of the position of the endoscope, allowing the relocalisation of this position in a further endoscopy.
- We report the results of a feasibility study in pig and a preliminary study in 8 patients with BE

## Method:

### ① First experimentation in pig

- During the first endoscopy, ten markings were made with a coagulation forceps in the distal oesophagus.
- The position of each marking was recorded by the magnetic system.
- A second operator blinded to the results of this first endoscopy performed a second endoscopy on the same pigs, guided by the magnetic system to relocate the markings.

### ② Second experimentation with 8 gastroenterologists in pig

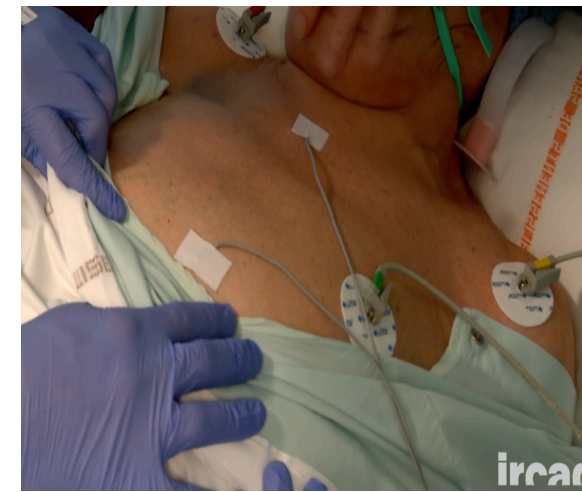- We obtained two recordings of a pig oesophagus with the magnetic system one without markings and one with markings created by a coagulation forceps.
- The experiments were performed in two phases.
  - In a first step, each endoscopist received a picture of a marked zone and was informed of its endoscopic coordinates. The endoscopist was then asked to retrieve this area on the recording without markings.
  - During a second test, each endoscopist had to retrieve the same area based on the informations provided by the synchronisation software.

### ③ Clinical experience in 8 patients with Barrett's oesophagus

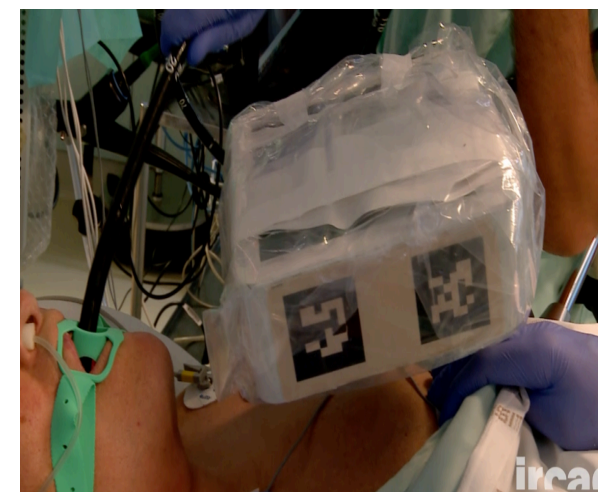
- During the same procedure, a first examination of the oesophagus allowed the selection of areas identified by visual criteria. After withdrawal of the endoscope, the endoscopist was asked to retrieve these areas, based on the informations provided by the magnetic system.
- Coordinates generated by the magnetic system during the two examinations of the oesophageal mucosa were then compared to verify the adequacy of the repositioning of the endoscope.

## Electromagnetic device

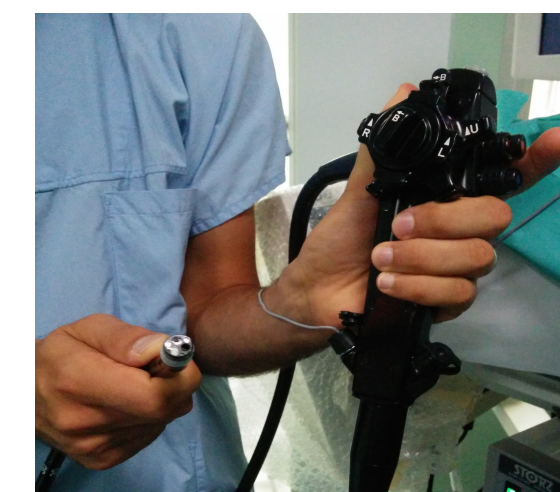- The electromagnetic tracking system (EMS) (NDI, Aurora) consists of an electromagnetic (EM) field transmitter and an EM probe.
- The EM probe is inserted through the operating channel of a double channel gastroscope. The EM field generator is positioned above the patient chest wall.



Electromagnetic sensors

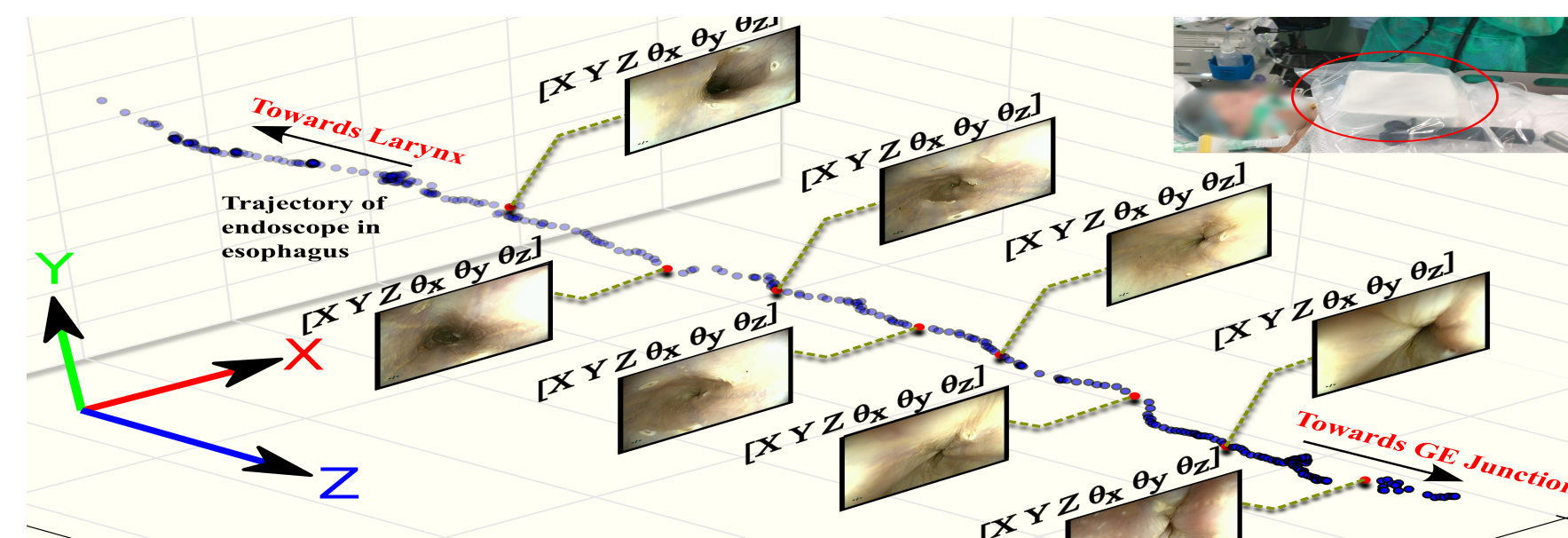


Electromagnetic field transmitter

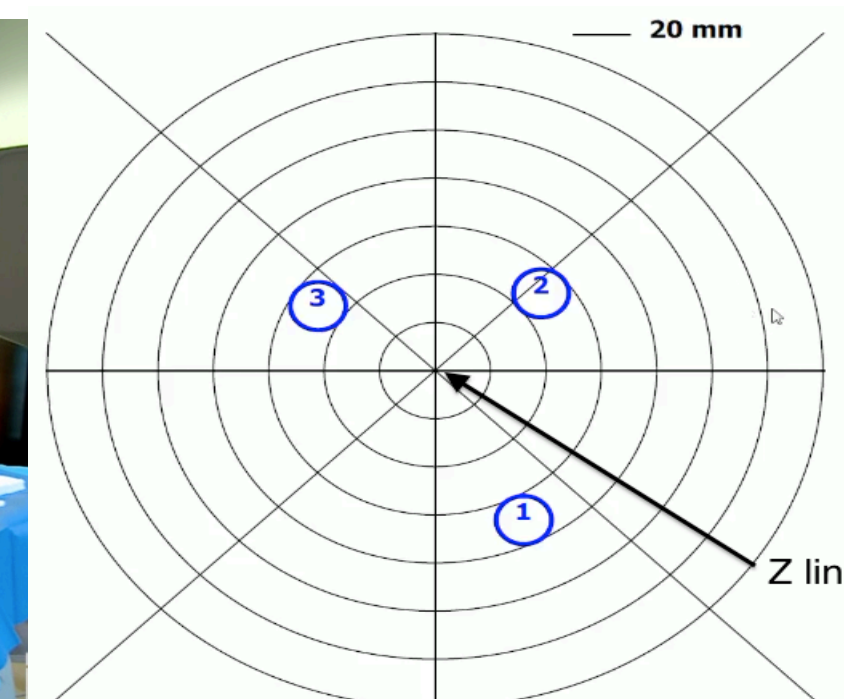
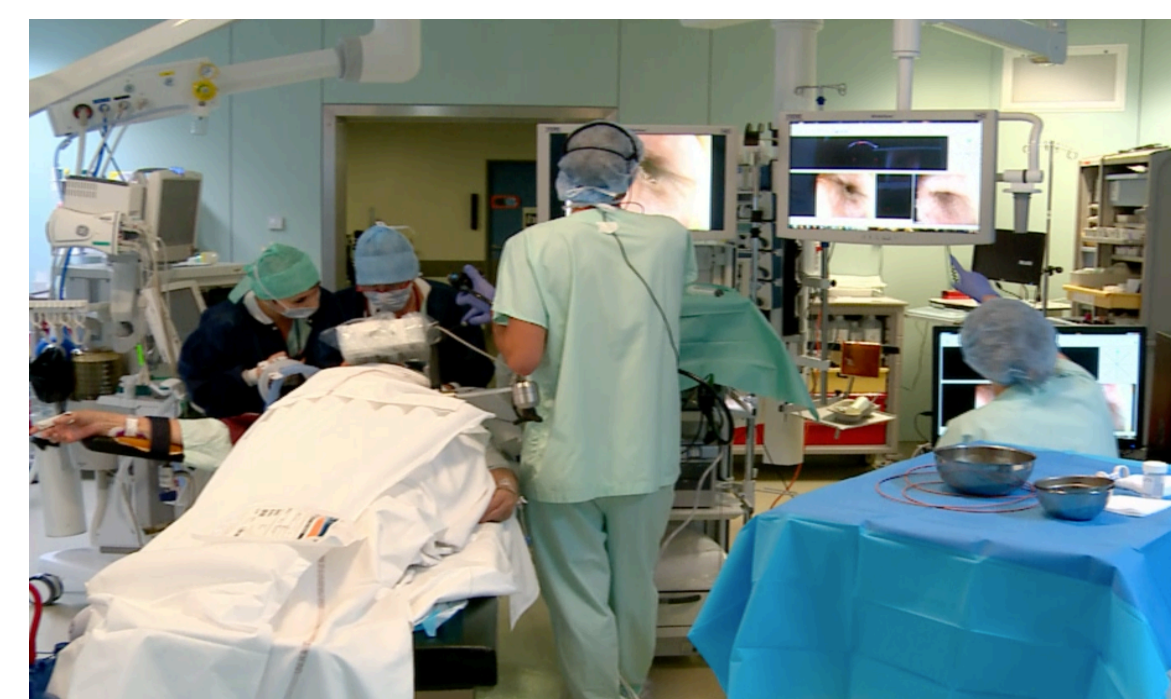

Electromagnetic probe in a working channel of a dual channel gastroscope

- The electromagnetic sensors and the transmitter enable 3D location of the recorded points during the procedure



- The rotation of the endoscope is also recorded, allowing the precise repositioning of the endoscope during the second procedure.
- The synchronization software (IRCAD®) records 3D coordinates point by point during the first procedure and then re-synchronizes these 3D coordinates in real time during the second procedure.
- At the end of the first examination, the software automatically generates a numeric chart of the biopsies sites in a PDF file.



## Results

### ① First experimentation in pigs

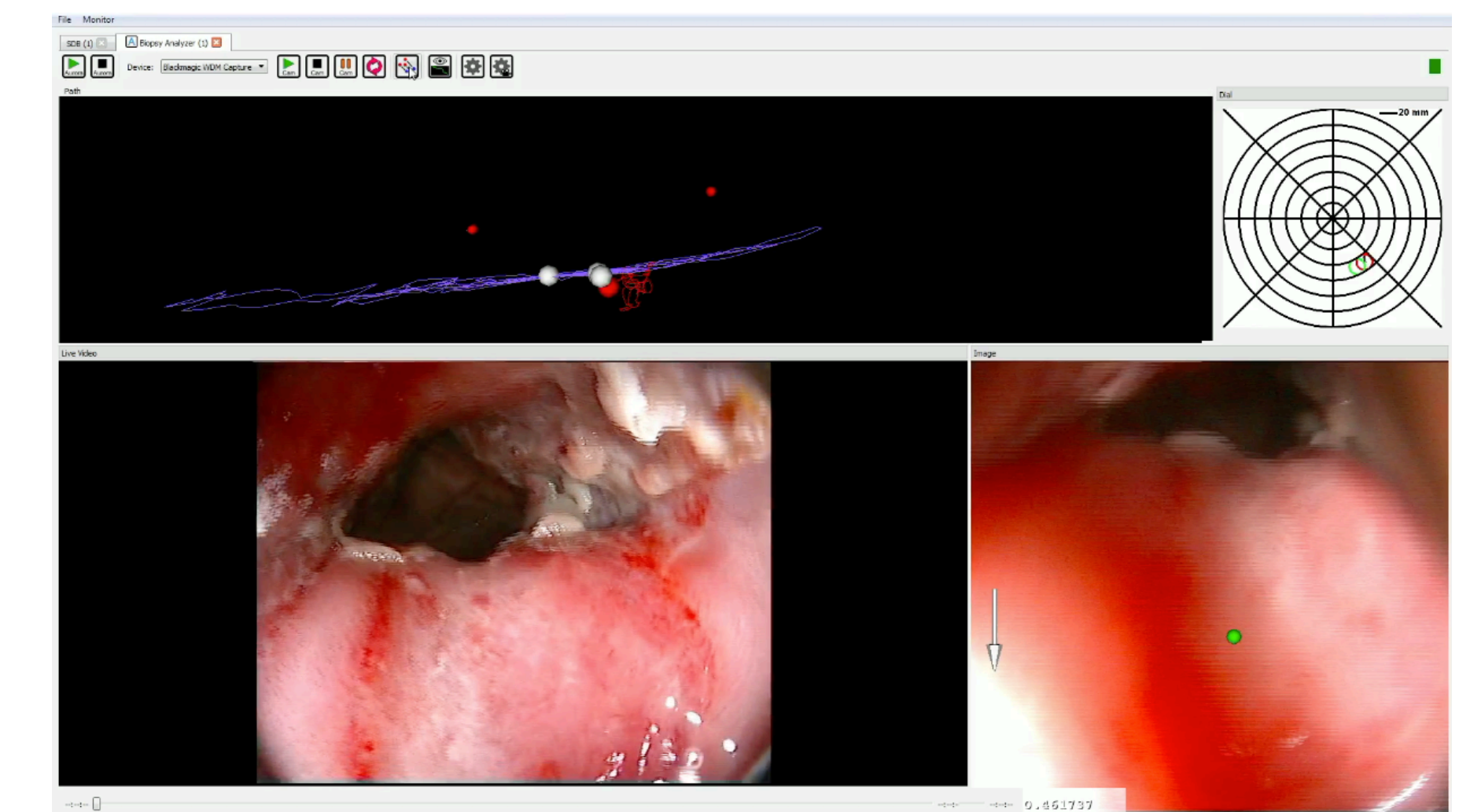
- After withdrawal of the endoscope, the second operator correctly relocated 48 of the 50 markings (96%) using the guidance system.
- The repositioning of the endoscope provided by the EMS system was within a 2mm range from the initial positioning.

### ② Second experimentation in pigs

Evaluator	Classical approach	Synchronization by EMS
N°1	6/12 (50%)	10/12 (83%)
N°2	9/12 (75%)	11/12 (92%)
N°3	3/12 (25%)	12/12 (100%)
N°4	6/12 (50%)	12/12 (100%)
N°5	0/12 (0%)	10/12 (83%)
N°6	7/12 (58%)	12/12 (100%)
N°7	8/12 (68%)	12/12 (100%)
N°8	3/12 (25%)	12/12 (100%)

### ③ Clinical study in patients with Barrett's oesophagus

- In 4 patients, the oesophagus was normal but we recorded spots defined by anatomical landmarks with the EMS system during the first examination.
- In 4 patients, a BE was diagnosed and multiple biopsy sites were recorded with the EMS system during the first examination.
- In the 8 patients, all spots defined during the first examinations were correctly recognized during the second examination, after the withdrawal of the endoscope, according to the informations provided by the EMS system.



## Conclusion:

- Both the experimental study in pig and the clinical study demonstrated the feasibility of the EMS prototype during gastroscopies and its usefulness to relocate the biopsy sites.
- The clinical usefulness of this system should be further evaluated during the follow-up of patients with BE.