



HAL
open science

Teaching tool for advanced visualization of temporal bone structures by fusion of μ CT and CT scan images

Clair Vandersteen, Thomas Demarcy, Hervé Delingette, Charles Raffaelli, Jonathan Laudanski, Thierry Pourcher, Jacques Darcourt, Philippe Franken, Dan Gnansia, Nicholas Ayache, et al.

► To cite this version:

Clair Vandersteen, Thomas Demarcy, Hervé Delingette, Charles Raffaelli, Jonathan Laudanski, et al.. Teaching tool for advanced visualization of temporal bone structures by fusion of μ CT and CT scan images. 8th International Symposium on Objective Measures in Auditory Implants, Oct 2014, Toronto, Canada. , 10.13140/2.1.1517.6007 . hal-01108877

HAL Id: hal-01108877

<https://inria.hal.science/hal-01108877v1>

Submitted on 23 Jan 2015

HAL is a multi-disciplinary open access archive for the deposit and dissemination of scientific research documents, whether they are published or not. The documents may come from teaching and research institutions in France or abroad, or from public or private research centers.

L'archive ouverte pluridisciplinaire **HAL**, est destinée au dépôt et à la diffusion de documents scientifiques de niveau recherche, publiés ou non, émanant des établissements d'enseignement et de recherche français ou étrangers, des laboratoires publics ou privés.

Clair Vandersteen^{1,2}, Thomas Demarcy^{2,3}, Hervé Delingette², Charles Raffaelli⁴, Jonathan Laudanski³, Thierry Pourcher⁵, Jacques Darcourt⁵, Philippe Franken⁵, Dan Gnansia³, Nicholas Ayache², Nicolas Guevara¹
 IUFC, Nice Hospital, France¹; Asclepios Research Team, Inria Sophia Antipolis, France²; Neurelec/Oticon Medical, France³; Radiology Department, University Hospital, Nice, France⁴; TIRO Department, Nice University, France⁵

Main goal

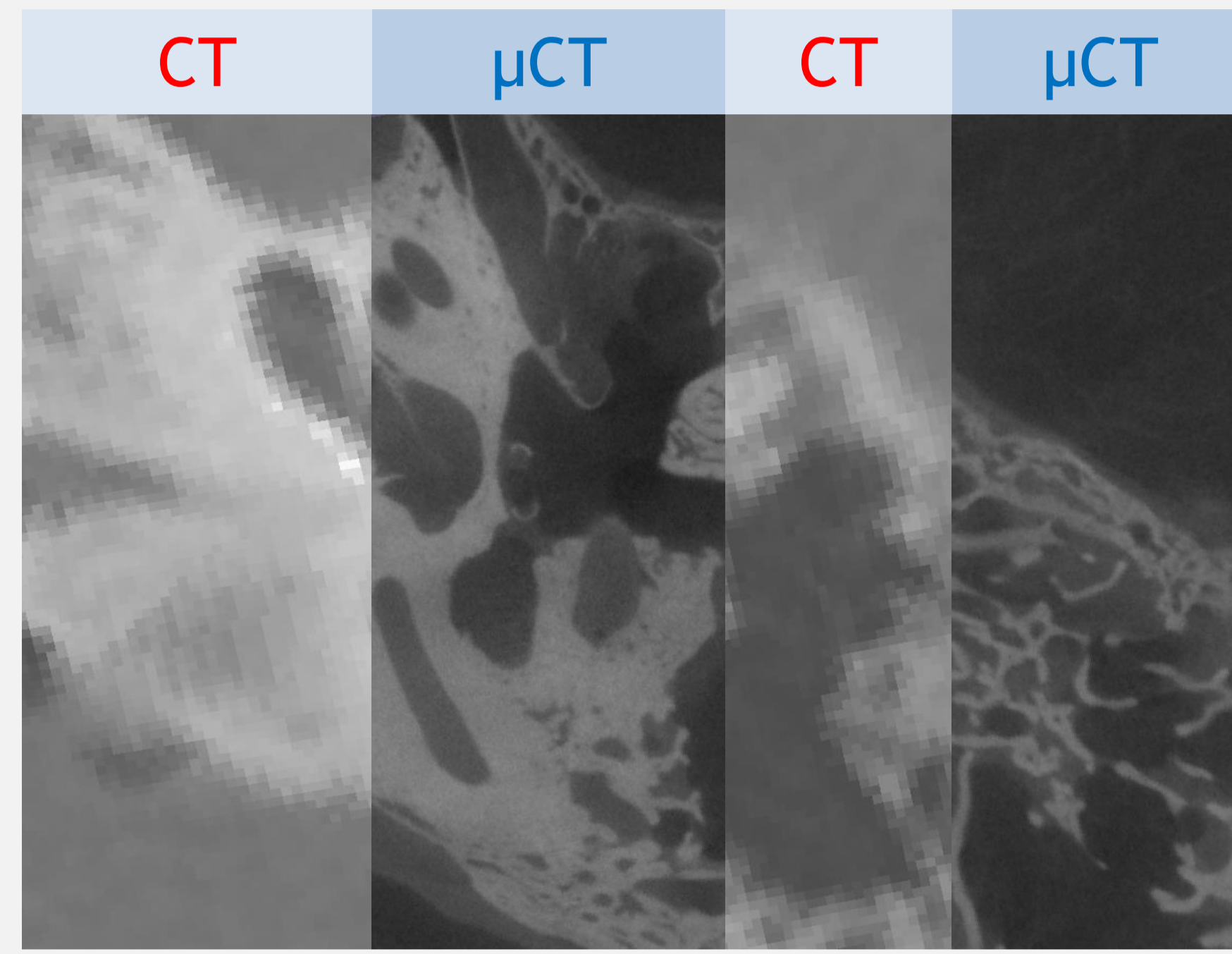
Improve the understanding of human temporal bone computed tomography (CT) scans based on semi-automatically segmented microcomputed tomography (μ CT).

Introduction

The three-dimensional ear anatomy is complex and challenging to interpret in CT scans because small structures are partially visible. Histological slices provide complementary high-resolution information, but may lead to geometrical distortions of the anatomy during preparation. Conversely, μ CT preserves the shape.

3D images acquisition and segmentation

- Five freshly cadaveric pairs of temporal bones
- Acquisition of CT (General Electric; Light Speed VTC 64) and a μ CT (General Electric; eXplore speCZT) images
- Seed-based segmentation of every **reliable anatomical structures** on CT or μ CT



Rigid registration of μ CT and CT

- First, rough point-based registration using anatomical landmarks¹
- Second, automatic rigid registration using a block matching framework²

References

¹ Umeyama, S.: Least-squares estimation of transformation parameters between two point patterns. IEEE Trans. Pattern Anal. Mach. Intell. 13, 376-380 (1991).
² Ourselin, S., Roche, A., Prima, S., Ayache, N.: Block Matching: A General Framework to Improve Robustness of Rigid Registration of Medical Images. Med. Image Comput. Comput. Interv. 557-566 (2000).

Reliable anatomical structures

- CT μ CT > cortical and trabecular layers of the entire temporal bone
- CT μ CT > vestibular labyrinth with the scalae tympani and vestibuli
- μ CT > ossicles and their ligaments
- CT μ CT > tympanic membrane
- μ CT > middle ear muscles and tendons
- CT > internal carotid artery and the sigmoide sinus
- CT μ CT > different branches of the vestibular nerve
- CT μ CT > facial nerve and the chorda tympani

Results

High resolution structures are fused and visualized on corresponding CT images. This experience significantly improves the visual recognition and spatial understanding of partially visible structures (e.g. tympanic scala, facial nerve and chorda tympani) in CT images.

Conclusion

Geometrically accurate temporal bone reconstructions provide an advanced teaching tool for medical students and cochlear implant surgeons. The understanding of spatial relationship between anatomical structures as well as the virtual exploration of surgical approaches is greatly facilitated.

N°	Structure
1	pyramidal eminence
2	sinus tympani
3	posterior tympanic sinus
4	chordal ridge
5	excavated lateral tympanic sinus
6	styloid eminence
7	chordal eminence
8	chorda tympani
9	cochlea
10	stapes
11	lateral sinus
12	superior semi-circular canal
13	facial nerve
14	internal carotid artery
15	tympanic membrane
16	scala tympani
17	CT slice
18	sickle crest
19	superior vestibular nerve area
20	inferior vestibular nerve area
21	posterior ampullary nerve
22	cochlear nerve area
23	stapes muscle
24	tensor tympani muscle
25	posterior ligament of incus
26	superior ligament of incus
27	superior ligament of malleus
28	anterior ligament of malleus

