



HAL
open science

Video Synchronization: An Approach to Biopsy Site Re-localization

Anant S. Vemuri, Adrien Sportes, Stéphane Nicolau, Jacques Marescaux,
Nicholas Ayache, Luc Soler

► **To cite this version:**

Anant S. Vemuri, Adrien Sportes, Stéphane Nicolau, Jacques Marescaux, Nicholas Ayache, et al..
Video Synchronization: An Approach to Biopsy Site Re-localization. Proceedings of Surgetica'2014 :
Computer-Assisted Medical Interventions: scientific problems, tools and clinical applications, Jocelyne
TROCCAZ, Dec 2014, Chambéry, France. hal-01089196

HAL Id: hal-01089196

<https://inria.hal.science/hal-01089196v1>

Submitted on 1 Dec 2014

HAL is a multi-disciplinary open access archive for the deposit and dissemination of scientific research documents, whether they are published or not. The documents may come from teaching and research institutions in France or abroad, or from public or private research centers.

L'archive ouverte pluridisciplinaire **HAL**, est destinée au dépôt et à la diffusion de documents scientifiques de niveau recherche, publiés ou non, émanant des établissements d'enseignement et de recherche français ou étrangers, des laboratoires publics ou privés.



Distributed under a Creative Commons Attribution - NonCommercial 4.0 International License

Video Synchronization: An Approach to Biopsy Site Re-localization

Anant S. Vemuri^{1,3}, Adrien Sportes^{4,2}, Stephane Nicolau², Jacques Marescaux², Nicholas Ayache^{3,1} and Luc Soler^{2,1}
¹IHU, Strasbourg; ²IRCAD, Virtual-Surg, Strasbourg; ³INRIA, Sophia Antipolis; ⁴NHC, CHU, Strasbourg.

Introduction:

Barrett's esophagus (Barrett's esophagus) is the pre-malignant lesion for the majority of patients with esophageal adenocarcinoma. The sequence of events from Barrett's esophagus to adenocarcinoma has several steps, encompassing low grade intra-epithelial Neoplasia (LGIN), and high grade intra-epithelial neoplasia (HGIN). As it seems that this evolution spans many years, endoscopic surveillance for patients with Barrett's esophagus has been advocated, to detect neoplasia at early and curable stages. In recent years endoscopic imaging techniques have improved greatly. However, even using sophisticated imaging techniques, the standard approach of comprehensive endoscopic biopsy protocol includes direct sampling from suspicious areas in combination with systematic random four quadrant biopsies (4QBs) every 1 ± 2 cm along the length of the Barrett's segment, according to the Seattle protocol, is recommended as the gold standard for surveillance. The approach is labor-intensive but is currently considered to be the state of the art. However, the primary problem is the inter-operative re-localization of these biopsy sites to guide the treatment. Often re-localization is performed using the markings made on the endoscope which are highly unreliable and prevent targeted treatments.

Related Work:

Several approaches to track the biopsy points "*intra-operatively*" exist [2,3]; each of them relying on the recovery of the 3D structure of the anatomy, to map and track the biopsy sites as they move in and out of the field-of-view of the endoscope frame. Atasoy et al. [3] propose to formulate the re-localization as image-manifold learning process for re-localization of the biopsy sites. However, they do not provide any spatial relations of the extracted segments inter-operatively, and so have not sufficiently clarified the application of their result in a clinical context for re-localization. We believe that, relying only on image based information for information extraction, that has to be mapped across multiple interventions can be highly unreliable; especially, due to temporal changes in tissue texture over multiple procedures, coupled with a highly deformable endoscopic scene, where repeatability of feature extraction, matching and tracking poses a significant challenge.

In an earlier work [1] we had proposed a general framework for inter-operative biopsy site re-localization framework by introducing an Electro-magnetic tracking system (EMTS) into the loop and providing a way to inter-operatively register video sequences to provide a guided navigation in the esophagus. In this work, we present a few modifications to our earlier approach to fit more closely with the work-flow in the clinical setting. Here we also present a qualitative evaluation of our approach.

System Setup:

The system consists of an electromagnetic tracking system (EMTS), which includes an electromagnetic field emitter (EMFE), a tracking interface, a titanium arm to mount the EMFE, EM sensors, a dual channel Karl Storz flexible endoscope. EMFE has a working volume of $50 \times 50 \times 50\text{cm}^3$. It has a blind zone of about 5cm in front of it, so it is positioned $\sim 6\text{cm}$ above the patient's chest and fixed in position using a titanium arm. The EMTS and the endoscope video output are connected to a computer. In our previous work, [1], we used a single sensor inserted into the endoscope channel. We discuss in the next few sections why this approach poses some practical issues. As a modification to our approach in [1], we propose an alternative using three sensors. One sensor attached at the Suprasternal (or Jugular) notch. It is the anatomical landmark located at the superior border of the manubrium of the sternum, between the clavicular notches. Externally it is a large dip, visible just below the neck. It is a

stable landmark that stays stationary during a breathing cycle or when the patient position is changed. The second sensor is attached along the sternum about 10-15cms below the Jugular notch. The third sensor is inserted in one of the channels of the endoscope, such that the sensor is placed at the opening of the channel.

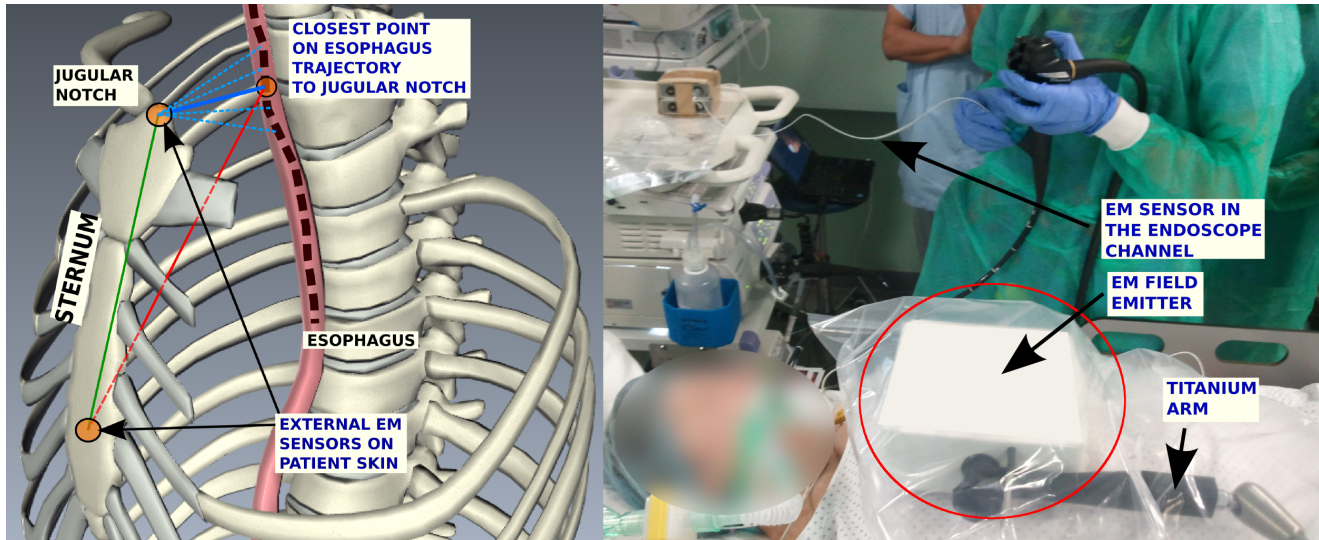


Fig. 1: Placement of sensors (left) and System setup (right)

The above figure shows the placement of the sensors on the patient.

Data acquisition: The process of acquiring data during an intervention involves a synchronized capture of video from the endoscope and tracking data from the EMTS. For each corresponding position of the endoscope in the esophagus, the corresponding position of (all three) sensors is recorded.

Inter-operative registration: To synchronize a previously performed recording with a live procedure, the reference frames of the EMTS have to be registered. We use the sensors attached to the sternum as our anatomical landmarks. More specifically, we use the sensor attached to the Jugular notch as the reference point. From this reference point, we define two vectors. The first in the direction of the second sensor placed on the sternum, \hat{n}_1 . The second point is computed online as the centroid of a cluster of points in the spherical region closest to the jugular notch in the esophagus trajectory. It defines the second vector at the Jugular notch \hat{AC} . Using these vectors we define a reference frame at the jugular notch as shown in the figure below. We register the live intervention and recorded interventions using these reference frames that are centered at the Jugular notch. We use the Jugular notch as our reference frame since it is easily identifiable externally and is very stable upon repeated sensor placement.

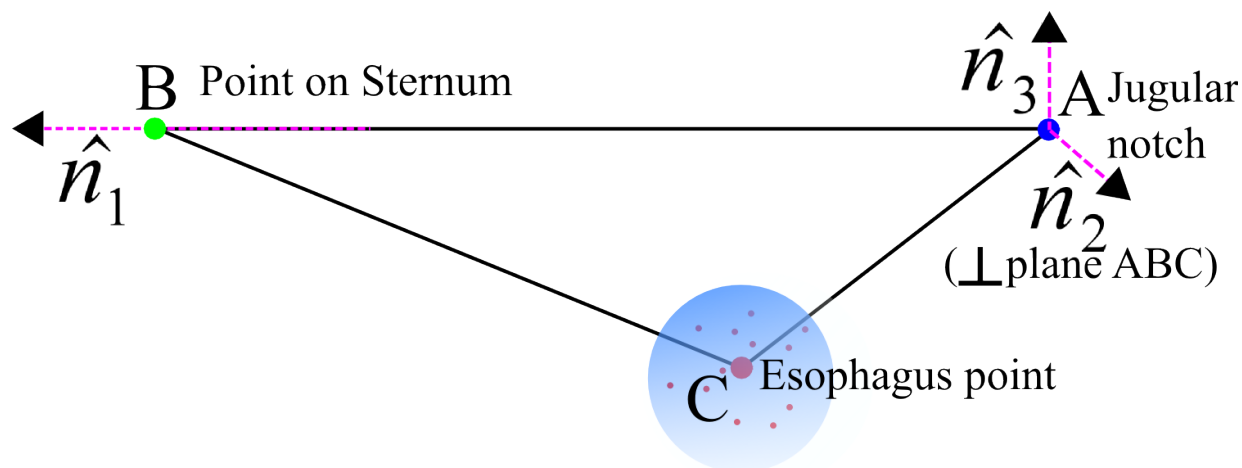


Fig. 2: Forming the reference frame for inter-operative registration.

The registration is performed online during the procedure so, there are no additional steps are necessary to initialize the video synchronization.

Evaluation:

Here we present a more detailed qualitative evaluation of our approach with experts and young gastroenterologists. We make two recordings of a pig's esophagus. The first with no markings made and the second with markings made using a coagulation device. Between the two recordings all the sensors were removed and replaced. Our experts tagged the regions in all the images of the first recording where the coagulation markings were made by reviewing the images from the second recording. This corresponds to the ground truth. The experiments were presented in two phases. The first using a classical approach where the evaluator had access to a printed picture of the marking and the distance inside the esophagus where the picture was taken. As the expert reviews the recorded images, he is also presented with an approximate distance inside the esophagus of each of the recorded images. In the second phase, the evaluator used our software which providing a synchronization between the two recordings. The evaluator had to locate and tag the markings on to the first recording using the information provided to him. The table below shows the result from eight evaluations. It values are the number of markings found out by the evaluator out of 12.

#	Classical Approach	Synchronization Approach
1	6	10
2	9	11
3	3	12
4	6	12
5	0	10
6	7	12
7	8	12
8	3	12

Our initial evaluation results are quite promising. We are performing more experiments and expect to provide a more detailed evaluation of our work soon.

References:

1. Vemuri et. al. "Inter-Operative Trajectory Registration for Endoluminal Video Synchronization: Application to Biopsy Site Re-localization" , MICCAI 2013.
2. Allain et. al. "Biopsy site re-localization based on the computation of epipolar lines from two previous endoscopic images", MICCAI 2009.
3. Atasoy et. al. "Endoscope video manifolds for targeted optical biopsy", IEEE, TMI 2012.