



HAL
open science

Addressing the Challenge of Edema in Fiber Tracking

Jérémy Lecoœur, Emmanuel Caruyer, Mark Elliott, Steven Brem, Luke Macyszyn, Ragini Verma

► **To cite this version:**

Jérémy Lecoœur, Emmanuel Caruyer, Mark Elliott, Steven Brem, Luke Macyszyn, et al.. Addressing the Challenge of Edema in Fiber Tracking. MICCAI 2014 DTI Tractography Challenge, Sep 2014, Boston, United States. hal-01072222

HAL Id: hal-01072222

<https://inria.hal.science/hal-01072222>

Submitted on 7 Oct 2014

HAL is a multi-disciplinary open access archive for the deposit and dissemination of scientific research documents, whether they are published or not. The documents may come from teaching and research institutions in France or abroad, or from public or private research centers.

L'archive ouverte pluridisciplinaire **HAL**, est destinée au dépôt et à la diffusion de documents scientifiques de niveau recherche, publiés ou non, émanant des établissements d'enseignement et de recherche français ou étrangers, des laboratoires publics ou privés.

Addressing the Challenge of Edema in Fiber Tracking

Jérémy Lecoœur¹, Emmanuel Caruyer¹, Mark Elliott¹, Steven Brem², Luke Macyszyn², and Ragini Verma¹

¹ Department of Radiology

² Department of Neurosurgery

Hospital of the University of Pennsylvania Philadelphia, PA, USA

Abstract. In this paper, we present a tractography paradigm that addresses the challenge of tracking through edema as well as regions of complex white matter. It involves the fitting of a multi-compartment model to a multi-shell acquisition, with one compartment pertaining to free water that characterizes the edema, and the second compartment, a higher order diffusion model that captures the underlying fiber structure. This is then incorporated into a probabilistic streamline tracking algorithm. This paradigm has been validated using cortical stimulation data acquired on patients. We applied the tracking paradigm to the datasets of the MICCAI Tractography Challenge. As the data comprised four shells, $b = 200, 500, 1000$ and 3000 s/mm^2 respectively, we were able to successfully fit a two-compartment model to the data that combines edema correction with a fiber orientation distribution (FOD) scheme to create a new higher order diffusion model. We then used this higher order diffusion model for tracking the cortico-spinal tract (CST) in the two patients with brain tumor. The tract was reconstructed using inclusion regions in the cerebral peduncle provided with the Challenge data, as well as regions defining the motor cortex segmented in the two subjects using an atlas. The results of fiber tracking showed that we were able to track through the edema, as well as complex white matter to reconstruct the CST, obtaining not only the main trunk of the CST, but also the lateral fibers to the hand and face regions. The results on the Challenge data were evaluated for anatomical correctness by two neurosurgeons, as well as for overlap with the motor strip provided with the Challenge data.

1 Introduction

The goal of modern surgical planning is to determine the optimal resection margin that maximizes tumor removal while preserving language, visual and motor function. Surgical planning has been increasingly reliant on diffusion imaging for the visualization of fiber tracts and the characterization of white matter changes. With mounting evidence that the extent of resection (EoR) of a brain tumor is linked to survival [1–5], maximizing the EoR while preserving function is of critical importance. Pre-operative dMRI-based fiber visualization facilitates an

optimized resection margin, leading to improved clinical outcomes [6–9]. However the widespread use of tractography in neuro-oncology has been hindered by the inaccuracy of current fiber tracking paradigms in the presence of cerebral edema. Edema affects water diffusion and thus alters measures such as fractional anisotropy (FA) that are used as stopping criteria for clinically available tractography suites, leading to highly variable and inaccurate white matter fiber reconstructions. Many software packages are available to help the surgical team in the complex task of fiber tracking and to create a resection plan that incorporates this data. The surgeon uses this roadmap during resection of the tumor in order to spare the eloquent white matter regions surrounding the tumor. However, currently available software packages address tracking in the presence of edema heuristically, by using a combination of parameters and anatomical knowledge. Edema, which manifests as a change in the free water content of tissue, is a significant confounder for fiber tracking as it lowers anisotropy and obfuscates the presence of the underlying fiber bundle, which may remain completely unaffected. This causes incorrect and inconsistent tracking. Furthermore, tensor-based models, which are the current norm in clinical software packages, are unable to track through complex white matter. While fitting the diffusion data with high order models enables tracking through crossing fiber regions, these regions are still susceptible to artifact when there is increased free water. Finally, although higher order models resolves certain challenges in tractography, current clinical packages cannot process state of the art diffusion acquisition sequences that can be fitted with such models. Tracking paradigms that attempt to address the challenge of edema depend on the acquisition sequence, the model fitted to the data, as well as the tracking algorithm. We have built on our work from the previous DTI Challenge [10], to create a new tractography paradigm that fits a multi-compartment model to a multi-shell data acquisition, which is then incorporated into a probabilistic streamline tracking algorithm. This method has been validated using cortical stimulation data. In this paper, we have applied this tracking paradigm to the multishell Challenge data to reconstruct the cortico-spinal tract (CST) in the presence of edema. The results have been evaluated by two neurosurgeons for anatomical correctness, as well as compared for overlap with the motor strip segmentation provided with the Challenge data.

2 Methods

Here we describe the application of the tractography paradigm to the Challenge data. In addition to the tractography paradigm, as surgical planning is customized for each patient, the tract extraction process depends on the placement of regions of interest, based on the anatomical knowledge of the user. The guiding principle is to be able to pick regions of interest such that the tracking results are highly sensitive and specific. We want to identify anatomically accurate tracts without sacrificing the sensitivity (at the cost of accuracy), as missing a portion of the tract, may lead to inaccurate resection and subsequent motor

deficit. We this in mind, we first describe the tractography paradigm (including the model fitted to the data) and then the choice of inclusion regions of interest (ROIs).

2.1 Tractography paradigm

The inability of DTI (Diffusion Tensor Imaging)-based strategies in handling crossing fibers has led to the development of HARDI (High Angular Resolution Diffusion Imaging)-based [11–18] paradigms that enable tracking through complex WM regions [19, 20]. However, the presence of edema increases local free water (FW) diffusion, which these single compartment models cannot estimate. This has led to the development of Multi-Compartment Models (MCMs) that consist of a FW component and another corresponding to the data model. Pasternak [21] used a tensor-based MCM, in which data was fitted with a tensor after correcting for the free water diffusion. Similarly, NODDI [22] also provides a FW estimation, but both of these cannot resolve complex WM regions with crossing fibers in the absence of a HARDI compartment. We have addressed these limitations by designing an MCM with a FW compartment [21] and a fiber orientation distribution (FOD) [23] to estimate diffusion directions in presence of edema. Alternate HARDI models other than the FOD can be used. The first compartment models the FW diffusion and the second, the anisotropic diffusion within and around axons. The Fiber Impulse Response is estimated by fitting a DTI-model to the data and identifying voxels with $FA > 0.7$ as single fiber voxels. We use the spherical harmonic (SH) representation of the FOD. The SH order is picked based on the number of gradient directions that have been acquired in each of the shells and whether the directions in the different shells are independent of each other. In the case of the Challenge data, there are 30 directions in the $b = 1000$ and 3000 s/mm^2 shells; however, they are not independent of each other (the same gradient directions are replicated). As such we use a 4th order representation. Although, mathematically a 6th order representation could have been used, a 4th order provides better tractography results, perhaps due to the increased smoothing afforded by the redundant directions. The FW correction is applied only to the regions of edema, when such a map is available. In our tractography paradigm, we use a probabilistic streamline approach [24] on the edema-free FODs, performed using mrtrix [15]. For the Challenge data, the tractography was constrained by an FA mask that was thresholded at 0.15 and a radius of curvature threshold of 3 mm, both values classically used in tractography applications [8]. It may be noted that FA was computed by fitting a tensor to the multishell data using DiPy [25].

Validation Cortical stimulation (STIM) is the established clinical standard of care technique to map the eloquent cortex with high spatial accuracy [26, 27]. STIM sites, recorded on the T1-image, were registered to the dMRI data using deformable registration following the surface registration map provided by the surgical navigation system. We compare the output of a clinical software

package with our tract (Fig. 1). The CST in the clinical software shows no lateral projections (left), however the functional activation (green blob) indicates the presence of fibers in the hand and face area. These fibers are identified by our tracking (center), which shows a high overlap with the STIM points (right), as compared to that of the tract extracted by the clinical software (yellow). The tractography has been validated on data from 4 patients.

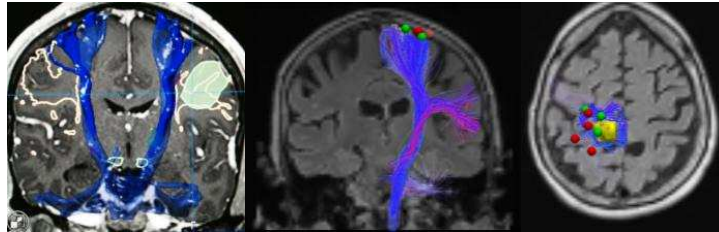


Fig. 1: CST created using (left) the clinical planning software package overlaid with functional activation (green blob); (center, right) views showing tracts available to the surgeon (yellow) and created by our method (blue), overlaid with STIM points (red: negative, green: positive).

2.2 Choice of Inclusion Regions of Interest (ROIs)

Surgical planning requires a customized choice of ROIs. In order to reconstruct a complete CST, we based our approach on the following definition of the tract: it originates largely from the pre-central gyrus (motor cortex), expanded into the pre-motor cortex and post-central gyrus to increase the sensitivity of the tract; as the tract descends in the corona radiata, the axons of the tract converge and form the posterior limb of the internal capsule (PLIC) and then plunge into the anterior part of the cerebral peduncles as shown on Figure 2.

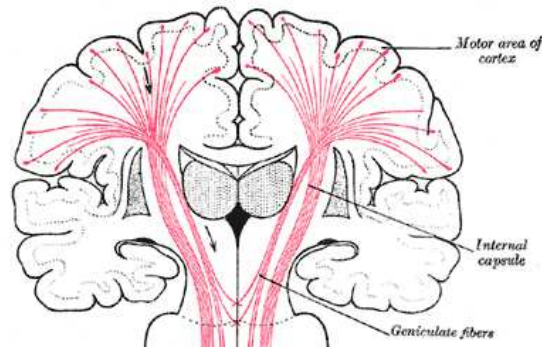


Fig. 2: Course of the CST (in red) from Gray [28]

We used the ROI of the cerebral peduncles provided by the Challenge. The neurosurgeons (Drs. Macyszyn and Brem) at UPenn prefer, that for enhanced

sensitivity, CST should be reconstructed using the supplemental areas that are the pre-motor cortex and the post-central gyrus, and using only the pre-central gyrus gives an incomplete answer about the location of the CST. Hence, instead of using the motor strip of the Challenge, that covered only the pre-central gyrus, we segmented the motor cortex for each subject. We used the strip provided by the Challenge, as a means of evaluating the results. Since our approach is a probabilistic streamline method, we split the motor cortex into 3 regions so each of the main regions of the CST (leg, arm and face) had equal probability of being reached. Using the Desikan Atlas [29] on Eve template [30], we retained the pre-central and post-central gyri and the pre-motor cortex in both hemispheres and dilated that ROI into the adjacent white matter. Our expert anatomist (Dr. Macyszyn) then cut this region in the three main regions of interest for each hemisphere (leg, arm and face). We then used the Fractional Anisotropy map of Eve and each subject to perform a non-rigid registration. This deformation field was then applied to these ROIs to register them to the subjects diffusion space. Figure 3 shows our ROIs on the template and both subjects.

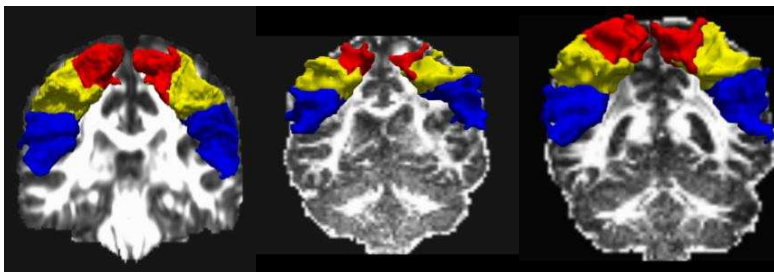


Fig. 3: The motor cortex in Eve template (left), registered to patient1 (middle) and to patient 2 (right).

3 Results

In this section, we will present the results of the tracking the CST in each of the Challenge subjects.

3.1 Subject 1

The CST was tracked in this subject by fitting the multi-compartment model to the data and tracking described in section 2.1, using the aforementioned ROIs defined in section 2.2. Figure 4 shows the CST of the healthy side and the Figure 5, the CST of the side with the tumor. We display the motor strip provided with the Challenge data, as means of evaluating the overlap. We are able to reconstruct not only the main trunk of the CST but also the lateral projections to the hand and face area.

Figure 5 shows the fibers of the affected CST traversing the edema region. The overlay with the Challenge motor strip (pre-central gyrus) shows how the tracts are displaced to both sides of the strip as a result of the tumor. The results

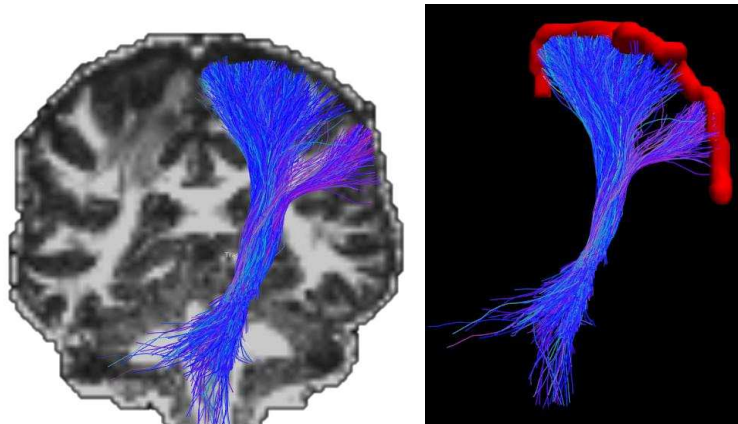


Fig. 4: Reconstructed CST of subject 1 on the healthy side: (left) overlay on a representative slice of FA image; (right) tract with the motor strip (red) showing that the reconstructed fibers overlap with the motor strip.

can be evaluated based on the overlap of the end points of the fibers with the pre-central gyrus, which is shown Fig. 4 (right), and in Fig. 5 (bottom). The overlap was visually evaluated to be high in the healthy side, and in parts of the strip away from the tumor, on the affected side.

3.2 Subject 2

Next, we applied our tractography paradigm to subject 2. Figures 6 and 7 show the results on the healthy side and the tumor side, respectively. As can be seen, the face, hand and foot region are well reconstructed in the CSTs on both the sides. In Figure 6, we see a high overlap of the tracked fibers with the pre-central gyrus (strip provided by the Challenge). Figure 7 shows the tracking results in subject on the side of the tumor. Since the edema does not overlap a lot with the fibers, the challenge here was the presence of mass effect. The figure shows how the fibers of the affected CST proceed from the cerebral peduncle to the motor cortex, compressed around the PLIC.

3.3 Evaluation Criteria

The algorithm presented in this paper has been validated using cortical stimulation data acquired on patients with brain tumor, with a multi-shell image acquisition. For the purposes of the Challenge, in the absence of ground truth, we evaluated the results based on the anatomical correctness of the results as judged by the neurosurgeons. It was also evaluated based on the overlap with the motor strip / pre-central gyrus provided with the Challenge data. Since we did not use this strip for the purposes of initiating the tracking, and instead used

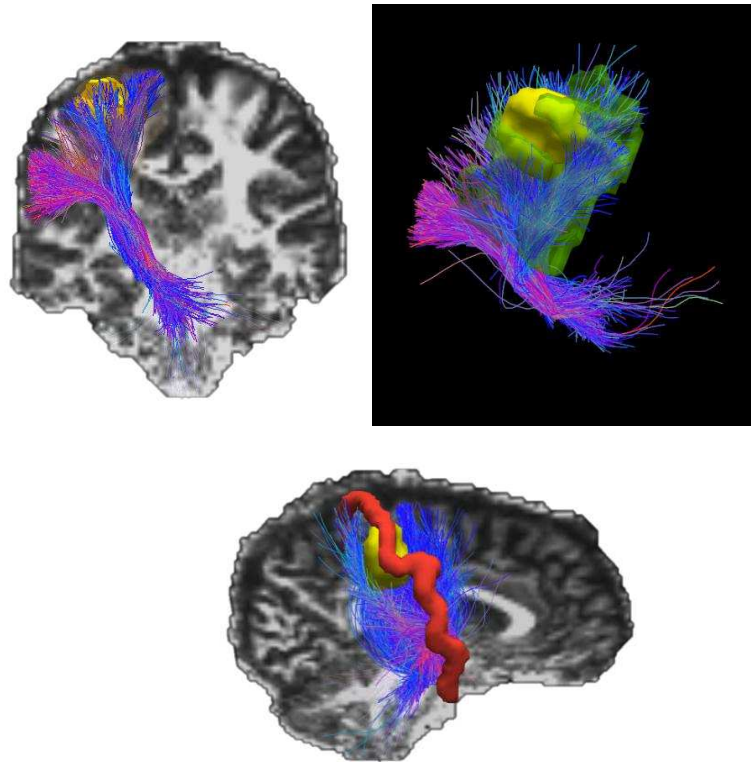


Fig. 5: CST on the side of the tumor in subject 1: (top left) Challenge motor strip overlaid on the CST; (top right) the CST displaced by the tumor (yellow) and tracking through the edema (green); (bottom) the CST displaced to both sides of the motor strip by the edema.

our own segmentation of the motor cortex, this could be used as an independent evaluation criterion. As was seen in both the cases, there was high overlap of the fiber end points with this strip, on the side that was unaffected by the tumor.

4 Discussion

The central nervous system is densely organized into multiple eloquent cortical areas responsible for language, vision, motor, and other important functions. White matter (WM) pathways such as the CST, the arcuate fasciculus (AF) and the optic radiations (OR) form the complex communication structures between these cortical areas leading to key eloquent brain function. Thus, the surgical treatment of any intrinsic brain pathology, irrespective of etiology, necessitates careful planning to characterize the complex inter-connections between these

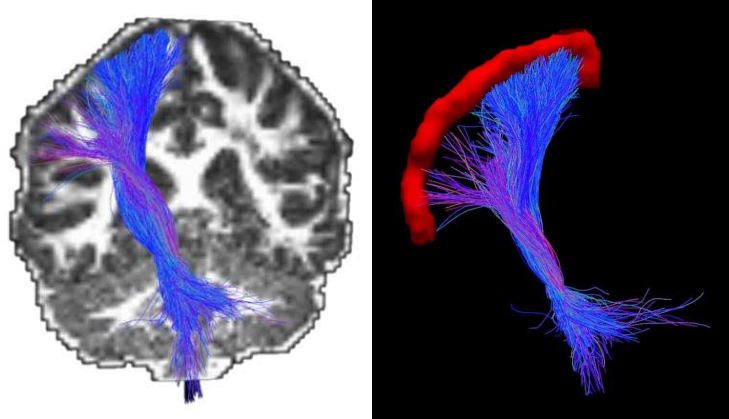


Fig. 6: CST of subject 2 on the healthy side (right) and overlaid with the precentral gyrus (motor strip) provided by the Challenge. The high overlap with the strip provides visual evaluation of the accuracy of the tracking paradigm.

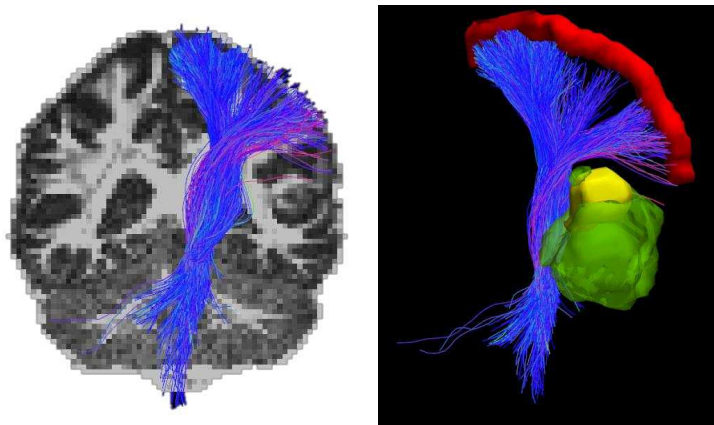


Fig. 7: CST of subject 2 on the affected side shows the PLIC being displaced by mass effect. The overlap with the Challenge motor strip demonstrates accurate reconstruction of the hand, face and foot area, despite the mass effect.

cortical areas, to preserve patient function during all stages of treatment. Fiber tractography not only enables the surgeon to visualize the spatial relationship between a tumor and fiber tract, but it also allows the surgeon to understand tract displacement when significant mass effect is present. Currently, there are numerous tractography techniques that vary based on the type of data acquisition, the diffusion model (tensors or higher order) fitted to the data, as well as the method of propagation, from streamline to probabilistic tractography. However,

independent of the factors used to generate fiber tracts, all current fiber tracking methods are affected by the presence of edema and mass effect. Additionally, all current clinical software packages are DTI-based, and hence cannot process advanced acquisition schemes that can facilitate characterization of edema as well as regions of complex white matter. The aim of this paper was to provide a tractography paradigm that has been designed for a multi-shell acquisition scheme. By fitting a multi-compartment model, the tractography paradigm accurately tracks through edematous, peritumoral brain regions, as well as regions of complex white matter like crossing fibers. The underlying hypothesis for our paradigm is that in regions of edema there is an increase in the extra-cellular water content, but the underlying white matter fiber is still present/intact. If our hypothesis is true, then tractography methods, which account for intra- and inter-cellular water, should be able to reconstruct white matter fiber in edematous brain regions. To achieve this, we previously used the simplest form of tractography, namely streamline tractography. As we show in our previous paper [10], this leads to a better reconstruction of tracts but it is limited to the usual caveats of this algorithm. By extending this methodology to a higher order model, we were able to reconstruct a more comprehensive CST that encompasses all three main regions (arm, leg and face). The results presented on the two subjects demonstrate that our novel algorithm enables tracking through edematous regions and is able to reconstruct the body of the CST, as well as the lateral projections. The tractography paradigm has been validated using cortical stimulation data obtained on patients at UPenn. For the Challenge, in the absence of cortical stimulation data, we evaluated the accuracy of tracts qualitatively. The qualitative evaluation of the tracts was based on the anatomical correctness of the reconstructed tract, as determined by the neurosurgeon and based on the overlap of the end points of fibers with the precentral gyrus / motor strip provided as part of the DTI Challenge dataset. As the reconstruction of the CST requires the modeling of regions with complex white matter (regions with crossing fibers) and turning (for the lateral fibers to the hand and face region), the HARDI-based multi-compartment model is able to reconstruct the fibers. As can be seen, our algorithm allows us to retrieve CSTs that fan out to the whole extent of the motor cortex. Since we used our own segmentation of the motor strip for the tracking, we used the overlap with the motor strip as an independent evaluation criterion. Upon inspection of the results, there is a high overlap between the motor strip and the end points of the fibers, both on the unaffected and affected side. In subject 1, the tracts are displaced by the tumor, but the overlap is high in the regions away from the tumor. In subject 2, where the tumor affects the PLIC, the overlap with the entire motor strip is very high.

5 Conclusions

This paper demonstrates that combining the free water component with a higher order diffusion model enables the tracking through edematous regions. The tracking is also resilient to mass effect. The fact that in addition to tracking through

edema, it can also successfully track through regions of crossing fibers is an important and powerful improvement of our previous method when performing white matter tractography in the presence of edema. By applying this validated algorithm on the Challenge data, we have demonstrated the importance of data acquisition, appropriate modeling and tracking, for the purposes of addressing the challenge of edema and complex white matter.

6 Acknowledgments

The authors acknowledge support from the NIH grant NIH-R01 MH092862 and CBICA seed grant.

References

1. Sanai, N., Berger, M.: Glioma extent of resection and its impact on patient outcome. *Neurosurgery* **62** (2008) 753–64
2. Smith, J., Chang, E., Lamborn, K., Chang, S., Prados, M., Cha, S., Tihan, T., Vandenberg, S., McDermott, M., Berger, M.: Role of extent of resection in the long-term outcome of low-grade hemispheric gliomas. *Journal of clinical oncology : official journal of the American Society of Clinical Oncology* **26** (2008) 1338–45
3. McGirt, M., Chaichana, K., Gathinji, M., Attenello, F., Than, K., Olivi, A., Weingart, J., Brem, H., Quiñones-Hinojosa, A.: Independent association of extent of resection with survival in patients with malignant brain astrocytoma. *Journal of neurosurgery* **110** (2009) 156 – 162
4. Oppenlander, M., Wolf, A., Snyder, L., Bina, R., Wilson, J., Coons, S., Ashby, L., Brachman, D., Nakaji, P., Porter, R., Smith, K., Spetzler, R., Sanai, N.: An extent of resection threshold for recurrent glioblastoma and its risk for neurological morbidity. *Journal of neurosurgery* **120** (2014) 846–53
5. Marina, O., Suh, J., Reddy, C., Barnett, G., Vogelbaum, M., Peereboom, D., Stevens, G., Elinzano, H., Chao, S.: Treatment outcomes for patients with glioblastoma multiforme and a low karnofsky performance scale score on presentation to a tertiary care institution. *clinical article. Journal of neurosurgery* **115** (2011) 220–9
6. Tsolaki, E., Kousi, E., Svolos, P., Kapsalaki, E., Theodorou, K., Kappas, C., Tsougos, I.: Clinical decision support systems for brain tumor characterization using advanced magnetic resonance imaging techniques. *World journal of radiology* **6** (2014) 72–81
7. Fernandez-Miranda, J., Pathak, S., Engh, J., Jarbo, K., Verstynen, T., Yeh, F., Wang, Y., Mintz, A., Boada, F., Schneider, W., Friedlander, R.: High-definition fiber tractography of the human brain: neuroanatomical validation and neurosurgical applications. *Neurosurgery* **71** (2012) 430–453
8. Castellano, A., Bello, L., Michelozzi, C., Gallucci, M., Fava, E., Iadanza, A., Riva, M., Casaceli, G., Falini, A.: Role of diffusion tensor magnetic resonance tractography in predicting the extent of resection in glioma surgery. *Neuro-oncology* **14**(2) (2012) 192–202
9. Wu, J., Zhou, L., Tang, W., Mao, Y., Hu, J., Song, Y., Du, G.: Clinical evaluation and follow-up outcome of diffusion tensor imaging-based functional neuronavigation: a prospective, controlled study in patients with gliomas involving pyramidal tracts. *Neurosurgery* **61** (2007) 935–48

10. Lecoecur, J., Caruyer, E., Macyszyn, L., Verma, R.: Improving white matter tractography by resolving the challenges of edema. In: Proceedings of MICCAI workshop: DTI Challenge 2013. (2013)
11. Tournier, J., Yeh, C., Calamante, F., Cho, K., Connelly, A., Lin, C.: Resolving crossing fibres using constrained spherical deconvolution: validation using diffusion-weighted imaging phantom data. *Neuroimage* **42** (August 2008) 617–25
12. Tuch, D.: Diffusion MRI of Complex Tissue Structure. PhD thesis, Harvard University and Massachusetts Institute of Technology (2002)
13. Tuch, D., Reese, T., Wiegell, M., Wedeen, V.: Diffusion mri of complex neural architecture. *Neuron* **40** (2003) 885–95
14. Tuch, D.: Q-ball imaging. *Magnetic Resonance in Medicine* **52** (2004) 1358–1372
15. Tournier, J., Calamante, F., Gadian, D., Connelly, A.: Direct estimation of the fiber orientation density function from diffusion-weighted mri data using spherical deconvolution. *Neuroimage* **23**(3) (Nov 2004) 1176–1185
16. Descoteaux, M., Angelino, E., Fitzgibbons, S., Deriche, R.: Regularized, fast, and robust analytical q-ball imaging. *Magnetic Resonance in Medicine* **58** (September 2007) 497–510
17. Descoteaux, M., Deriche, R., Knösche, T., Anwander, A.: Deterministic and probabilistic q-ball tractography: from diffusion to sharp fiber distributions. *IEEE Transactions in Medical Imaging* **28** (February 2009) 269–86
18. Descoteaux, M., Deriche, R., Le Bihan, D., Mangin, J.F., Poupon, C.: Multiple q-shell diffusion propagator imaging. *Medical Image Analysis* **15** (2011) 603–621
19. Descoteaux, M., Deriche, R., Le Bihan, D., Mangin, J.F., Poupon, C.: Diffusion propagator imaging: Using Laplace’s equation and multiple shell acquisitions to reconstruct the diffusion propagator. In: Proc. 21th IPMI. LNCS-5636, Williamsburg, VA, Springer (July 2009) 1–13
20. Bloy, L., Ingalhalikar, M., Batmanghelich, N., Schultz, R., Roberts, T., Verma, R.: An integrated framework for hardi-based investigation of structural connectivity. *Brain Connectivity* **2**(2) (2012) 69–79
21. Pasternak, O., Sochen, N., Gur, Y., Intrator, N., Assaf, Y.: Free water elimination and mapping from diffusion mri. *Magnetic Resonance in Medicine* **62**(3) (2009) 717–730
22. Zhang, H., Schneider, T., Wheeler-Kingshott, C., Alexander, D.: Noddi: practical in vivo neurite orientation dispersion and density imaging of the human brain. *Neuroimage* **61** (2012) 1000–16
23. Tournier, J., Calamante, F., Connelly, A.: Robust determination of the fibre orientation distribution in diffusion MRI: Non-negativity constrained super-resolved spherical deconvolution. *NeuroImage* **35**(4) (May 2007) 1459–1472
24. Tournier, J., Calamante, F., Connelly, A.: Mrtrix: diffusion tractography in crossing fibre regions. *International Journal of Imaging Systems and Technology* (2012)
25. Garyfallidis, E., Brett, M., Amirbekian, B., Rokem, A., van der Walt, S., Descoteaux, M., Nimmo-Smith, I., Contributors, D.: Dipy, a library for the analysis of diffusion mri data. *Frontiers in Neuroinformatics* **8**(8) (2014)
26. Kim, S., McCutcheon, I., Suki, D., Weinberg, J., Sawaya, R., Lang, F., Ferson, D., Heimberger, A., DeMonte, F., Prabhu, S.: Awake craniotomy for brain tumors near eloquent cortex: correlation of intraoperative cortical mapping with neurological outcomes in 309 consecutive patients. *Neurosurgery* **64** (2009) 836–45
27. Sanai, N., Berger, M.: Intraoperative stimulation techniques for functional pathway preservation and glioma resection. *Neurosurgical focus* **28** (2010) E1
28. Gray, H.: Anatomy of the human body. Henri Gray (1858)

29. Augustinack, J., Huber, K., Stevens, A., Roy, M., Frosch, M., van der Kouwe, A., Wald, L., Van Leemput, K., McKee, A., Fischl, B.: Predicting the location of human perirhinal cortex, brodmann's area 35, from mri. *NeuroImage* **64** (2013) 32–42
30. Oishi, K., Faria, A., Mori, S.: Jhu-mni-ss atlas. Technical report, JHU (2010)