



HAL
open science

Improving White Matter Tractography by Resolving the Challenges of Edema

Jérémy Lecoœur, Emmanuel Caruyer, Luke Macyszyn, Ragini Verma

► To cite this version:

Jérémy Lecoœur, Emmanuel Caruyer, Luke Macyszyn, Ragini Verma. Improving White Matter Tractography by Resolving the Challenges of Edema. MICCAI 2013 DTI Tractography Challenge, Sep 2013, Nagoya, Japan. hal-00850496

HAL Id: hal-00850496

<https://inria.hal.science/hal-00850496>

Submitted on 6 Aug 2013

HAL is a multi-disciplinary open access archive for the deposit and dissemination of scientific research documents, whether they are published or not. The documents may come from teaching and research institutions in France or abroad, or from public or private research centers.

L'archive ouverte pluridisciplinaire **HAL**, est destinée au dépôt et à la diffusion de documents scientifiques de niveau recherche, publiés ou non, émanant des établissements d'enseignement et de recherche français ou étrangers, des laboratoires publics ou privés.

Improving White Matter Tractography by Resolving the Challenges of Edema

Jérémy Lecoœur¹, Emmanuel Caruyer¹, Luke Macyszyn², Ragini Verma¹

¹ Section of Biomedical Image Analysis, Department of Radiology,
University of Pennsylvania, Philadelphia, PA, USA.

² Hospital of the University of Pennsylvania, Department of Neurosurgery,
University of Pennsylvania, Philadelphia, PA, USA.

Abstract. In this paper, we present a paradigm for alleviating the challenge of fiber tracking through edematous brain regions. This new framework of fiber tracking is applied to the brain tumor datasets 1, 2 and 3 provided as part of the 3rd MICCAI DTI Tractography Challenge. Although the data was single shell, $b = 1000\text{s/mm}^2$, we were able to successfully fit a two-compartment model to the data and extracted measures of free water in edema as well as corrected tensors. We subsequently used these corrected tensors for fiber tracking. Our tracking was initialized using regions of interest manually demarcated by the neurosurgeon, with streamline tracking being the adopted method. As part of the challenge, we tracked the corticospinal tracts of the three subjects in the presence of extensive edema. In addition, other peritumoral tracts in regions of edema were also tracked to evaluate the extent to which our technique was able to improve tracking in edematous areas. Results of fiber tracking are presented for these tracts, before and after the correction of tensors and removal of the free water component. The evaluation criteria of the different tracts were based on the qualitative evaluation by the neurosurgeon and the anatomical knowledge of these tracts. Additionally, quantitative criteria, consisting of the change in the principal orientation of the tensors and the fractional anisotropy, both of which affect fiber tracking, were also used to evaluate our paradigm.

1 Introduction

Fiber tracking is extensively studied with the aim of augmenting and improving the surgical planning of patients with intrinsic brain lesions. Current clinical research suggests that both extent of resection as well as patient morbidity following surgery are important variables that are significantly correlated with survival. Fiber tracking has the potential to optimize resection while maximizing patient function.

There are a variety of clinical software packages that facilitate fiber tracking, which is then used by surgeons in the operating room during the course of tumor resection. However, a major limitation of current fiber tracking methods is the inability to account for mass effect and track in the presence of edema. Specifically, edema, which is the result of increased intercellular free water, presents a unique challenge to fiber tracking as it lowers anisotropy. Despite the presence of the underlying fiber bundle, which may remain completely unaffected, fiber tracking is interrupted due to

this lowered anisotropy. While high order models allow tracking through crossing fiber regions, they will likewise be affected by increased free water. In addition, these models require significantly longer acquisition sequences, which are not currently the standard of care.

There are several existing methods to model water content in tissue, which require a multi-shell acquisition. In light of the data provided in the context of this challenge, we chose to model water content in edematous brain tissue using the free water multi-compartment model [1]. This method allows us to calculate the free water fraction, as well as the corrected tensor, with a low b value acquisition and limited gradient directions. We use this method on the challenge dataset to perform fiber tracking in edematous, peritumoral regions.

2 Methods

In this section, we describe the steps that were performed on the challenge datasets, from raw data pre-processing to fiber tracking magic.

2.1 Pre-processing of the diffusion-weighted images

In order to eliminate the noise present in the diffusion-weighted (DW) images that can be highly detrimental to the quality of tractography, we used the joint Linear Minimum Mean Squared Error (LMMSE) filter introduced by Tristan-Vega et al [2]. This denoising method is adapted to the Rician nature of the noise in low SNR magnitude MR images. Based on the findings of Dyrby et al. [3], where results of tractography were greatly improved by resampling the DW images to an isotropic resolution, the denoised DW images were resampled from a $1.14 \times 1.14 \times 5.2 \text{ mm}^3$ resolution to a 2mm isotropic resolution using a trilinear interpolation. This resampling enhanced the data in such a way that anatomical details are now visible on the sagittal and coronal slices while no information could be inferred in the original resolution. The pre-processed data was fitted with a diffusion tensor model. Fractional anisotropy and color maps were created from the data, to facilitate the drawing of regions of interest (ROIs) for fiber tracking.

2.2 Regions of interest for tracking

The RGB color map of the tensor was used to draw the regions of interest for fiber tracking. A neurosurgeon drew the regions of interest (ROI) for selecting out the desired tract, based on anatomy and the colormap data. A large portion of the corticospinal tract originates from the pre-central gyrus (motor cortex), while the premotor cortex and post-central gyrus contribute the remaining fibers that compose the tract. As the tract descends in the corona radiata, the axons of the tract converge and form the posterior limb of the internal capsule (PLIC). Hence, we use the PLIC as our main ROI for tracking. To constrain the fiber tracking to the corticospinal tract, we used a secondary ROI at the level of the cerebral peduncles. Figure 1 shows

representative regions of interest in subject one.

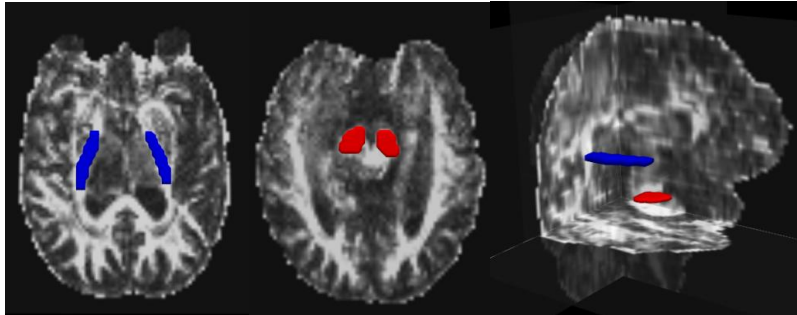


Figure 1. Regions of interest for selecting the corticospinal tract. Left panel: Posterior limb of the internal capsule. Middle panel: Cerebral peduncles. Right panel: Relative position of both ROIs in the brain.

Given the unique subject and tumor location, we selected the appropriate peri-tumoral tracts independently for each subject. Thus, the ROIs for each subject are different with respect to these tracts. In subject 1, the arcuate fasciculus was in close proximity of the tumor and in a region of edema. Two ROIs were used to filter the tract and select the arcuate; one in the temporal lobe (shown in green in Figure 2, left panel) and the other one in the parietal lobe (shown in yellow on Figure 2, left panel). The tract of interest in subject 2 was the inferior fronto-occipital fasciculus (IFOF), once again based on tumor proximity and edema. The ROI for this tract was placed as shown on figure 3 (center), corresponding to the body mid-section of the tract. In subject 3, given the location of the edema and tumor, the interesting fibers were part of the corpus callosum tract. Hence we designed an ROI to capture that particular sub-bundle (see figure 3, right panel).

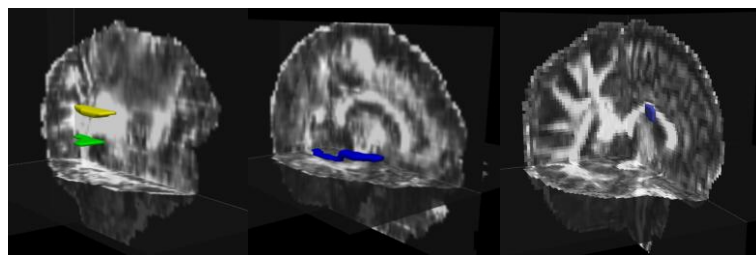


Figure 2. Regions of interest for tracking the (left) arcuate fasciculus, (center) the IFOF and (right) part of the corpus callosum.

2.3 Free water suppression

Pasternak et al. showed in [1] that the anisotropy observed in diffusion MRI is only due to the displacement of a fraction f of the water molecules within the imaging

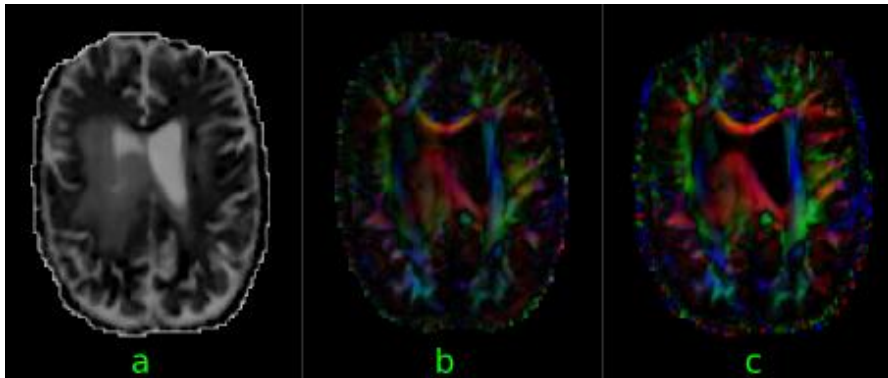


Figure 3. Effect of free water suppression on tensors: (a) map of the free water volume fraction, (b) color map of tensors fitting, (c) color map of tensors corrected for free water.

voxel. This diffusion can be represented by the well known diffusion tensor model [4], and the corresponding contribution to the signal follows the Stejskal and Tanner equation [5], $C_{\text{tissue}} = f \exp(-b \mathbf{g}_k^T \mathbf{D} \mathbf{g}_k)$, where b is the diffusion weighting, and \mathbf{g}_k is the diffusion gradient direction. Conversely, the remaining fraction of the water protons loosely interacts with the tissue for the typical timescale of diffusion sensitization in clinical scanners, and can be assimilated as free diffusion, leading to a contribution in the signal attenuation $C_{\text{water}} = (1-f) \exp(-b d)$, where d is the diffusion of water. We have implemented the estimation of f and \mathbf{D} as described in [3], on the pre-processed challenge data. The “corrected” tensor, \mathbf{D} is used for the fiber tracking. The effect of free water elimination on the anisotropy and the color map of the corrected tensors is illustrated in Fig. 3.

2.4 Fiber tractography

As the aim of the challenge was to reconstruct the corticospinal tract (CST) and other surgically and anatomically relevant peri-tumoral tracts, we performed whole brain tractography using DTK [6], keeping the parameters the same for all the tracts. Importantly, we did not fine-tune parameters for each of the tracts separately. The tractography was constrained by a fractional anisotropy (FA) mask that was thresholded at 0.15 and an angle threshold of 35 degrees, both values classically used

in tractography applications [7]. We used FACT [8], a simple, efficient deterministic tracking algorithm on the tensors before and after free water removal. This could be replicated with any tractography algorithm, however, we chose the most widely adopted one, as the crux of the paper was to evaluate the effect of modeling edema, more generally water content of tissue, via a multi-compartment model.

3 Results

In this section, we will first present the sharpened principal direction of tensors after free water removal. Next, these tensors were used to perform fiber tracking. Finally, we present qualitative and quantitative comparisons of the tracts obtained from the same ROIs before and after free water removal on each of the challenge subjects.

3.1 Effect of Free water removal

In Figures 4 and 5, we demonstrate the effect of water removal on the principal direction of the tensors. We use the dot product between the principal direction of the

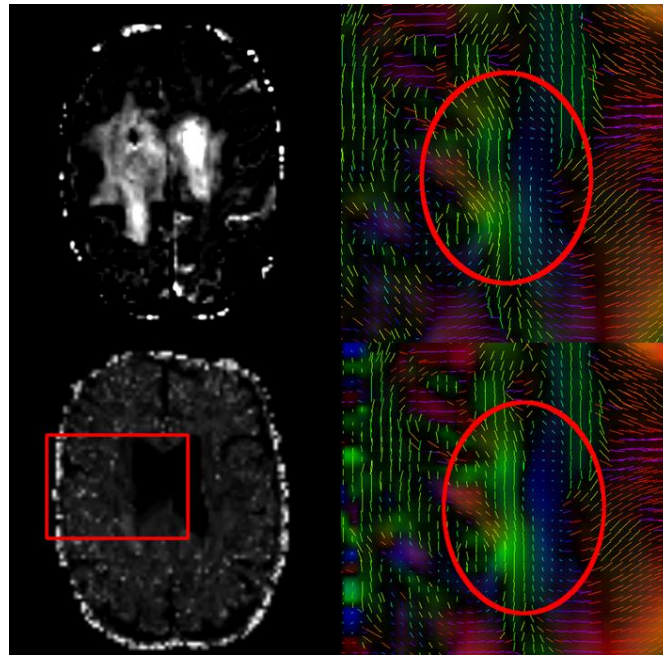


Figure 4. Effect of the free water removal on subject 1. Left panel: FA difference (top) and dot product of the principal directions (bottom) of the tensor before and after removal. Right panel: Principal orientation of the tensor before (top) and after (bottom) free water removal. Effect is clearly visible in the red circle, especially in the blue area.

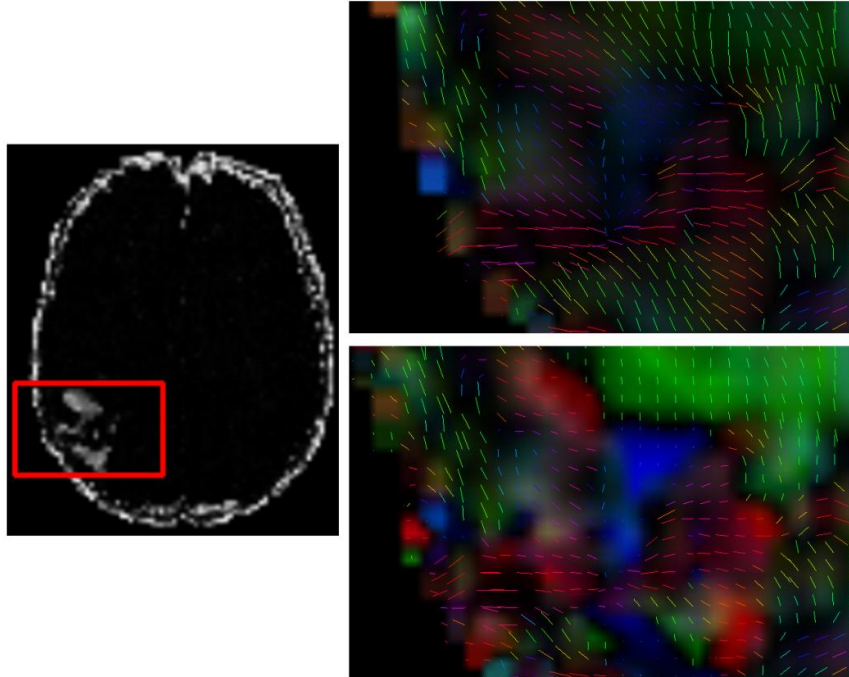


Figure 5. Effect of the free water removal on subject 2. Left panel: Dot product of the principal direction of the tensor before and after removal (black is 0 degree correction, white corresponds to 90 degrees). Top right: principal orientation of the tensor before free water removal. Bottom right: principal orientation of the tensor after the free water removal.

tensor before and after the free water removal, as a measure of the amount of change. Additionally, we also compute the difference in FA after free water correction. As can be seen in the figures, the principal direction of the tensors gets realigned to the underlying anatomical fiber orientation, most prominently evident in the edematous region of the corticospinal tract (see red circles on figure 4).

3.2 Subject 1

We present the results of tracking the corticospinal tract and the arcuate, before and after the removal of free water.

Corticospinal Tract

The left and right corticospinal tracts were tracked through the original DTI data without the removal of free water using the aforementioned ROIs (see Methods section 2.2). As can be seen in Figure 6, the fibers in the left corticospinal tract are incomplete as the tracking algorithm is hindered by the presence of edema, which extends to the motor cortex. The left CST consists of a bundle of 278 fibers while the right CST has 514 fibers, with the tumor/edema present on the left. After applying the free water removal, the number of fibers increases in the tracts bilaterally and we are able to track through the edematous region; this is especially visible on the bottom right panel of figure 6. We found that the left CST now has 641 fibers (an increase of 130%) and the right CST has 1020 fibers (an increase of 98%). Of note, the

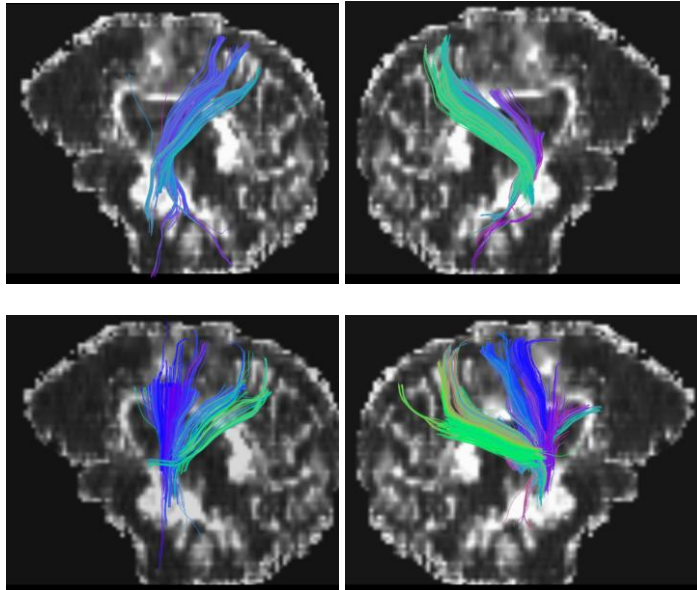


Figure 6. Corticospinal tract of subject 1 tracked using tensors before free water removal (top row) and after free water removal (bottom row).

reconstructed CST on the left is more robust and anatomically correct, while the number of false-positive tracts has not been significantly increased.

Arcuate Fasciculus

In Fig 7, we show the three orthogonal views of the arcuate fiber bundle of subject 1, before and after free water removal. On the first set of images, tracking of the fiber terminates when the tract enters the region of edema, which is situated around the superior part of the arcuate fasciculus.

As can be seen on Figure 7, the presence of edema, which prevented the tracking

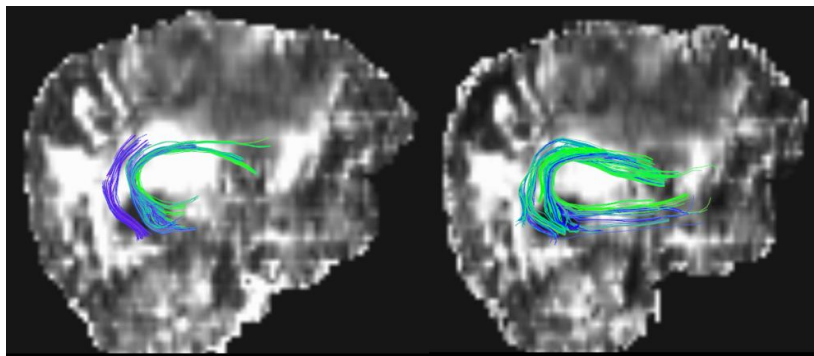


Figure 7. Tractography of the Arcuate fasciculus in subject 1 (left panel) using tensors before and after free water removal (right panel).

algorithm from tracking the arcuate fasciculus, has been mitigated in the images after free water removal. Not only are we able to tract fibers through the edematous region and obtain longer fibers (66.22 +/- 19.23 mm pre-correction versus 88.99 +/- 21.42 mm post-correction), but we are also able to recover more fibers: 155 before free water removal versus 242 after (an increase of 56 %). Furthermore, as for the CST, the arcuate fasciculus is more robust without the addition of false-positive tracts/fibers.

3.3 Subject 2

As the effect of free water removal is similar on this subject, we only present the fibers recovered after the free water removal.

Corticospinal tract

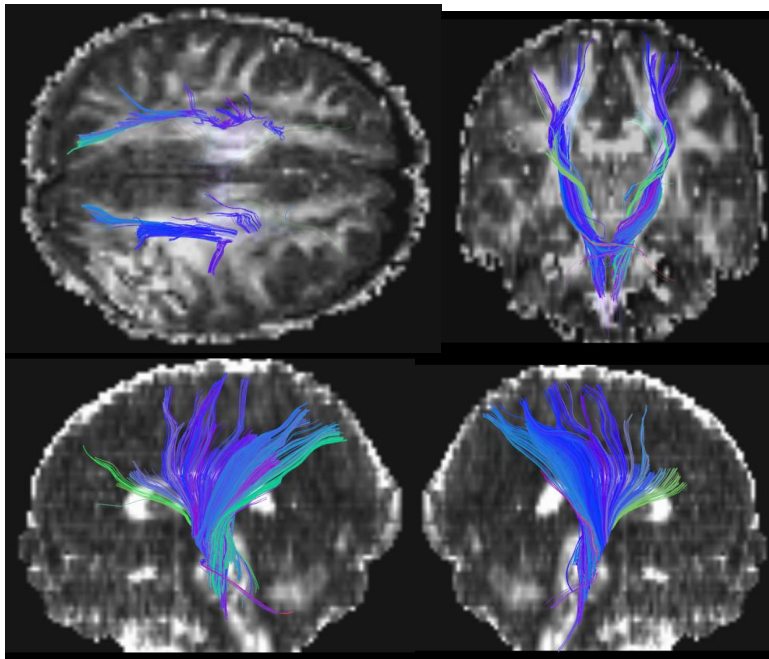


Figure 8. Four views of the corticospinal tract of subject 2, when the tracking was carried out on the tensors after free water removal.

Since the tumor was situated in the posterior and lateral portion of the brain (temporo-parietal region), the CST was fairly unaffected by the tumor, and hence there was

little difference between the CST in the tensors before and after free water removal. After free water removal, we obtained 683 fibers for the left CST, while we had 650 before (+5%). On the right side, the side of the tumor and edema, the CST contained 638 fibers, versus 602 before (+13%). Figure 8 shows the CST recovered after free water removal.

Inferior Fronto-Occipital Fasciculus

The Inferior Fronto-Occipital Fasciculus (IFOF) was severely affected by the presence of edema and could not be tracked prior to the removal of free water. Hence, the improvement in tracking after free water removal was spectacular and we were able to track the major bundles of IFOF. The post-correction IFOF is shown in Figure 9. Not only were we able to recover a previously unrecoverable tract, but as in subject one, the method achieved this without the addition of numerous false-positive fibers.

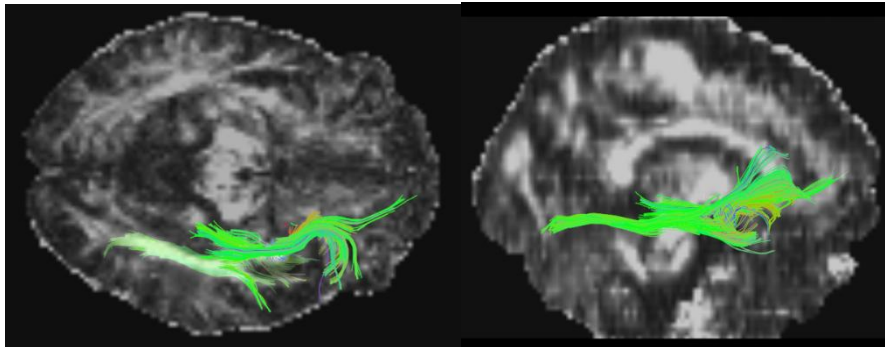


Figure 10. The Inferior Fronto-Occipital Fasciculus of subject 2 after free water removal. With the same ROIs, no tracts were recovered in the data before free water removal.

3.3 Subject 3

Again, as the effect of free water removal is similar on this subject, we only present the fibers recovered after free water removal. We also compared the fibers reconstructed from the 20 direction DWI and the 30 direction DWI.

Corticospinal tract

In this patient, as the tumor is situated in front of the left CST, the fibers were not affected by edema. As such, the difference between the CST reconstructed before and after free water removal is not striking. Indeed, with the 20 direction DWI we obtained 201 fibers for the left CST after free water removal, versus 193 before (hence an improvement of 4%). On the right side, the CST comprised 233 fibers post free water removal, while there were 225 before (an increase of 3.5%). As before, the same seed ROIs were used pre- and post-free water correction.

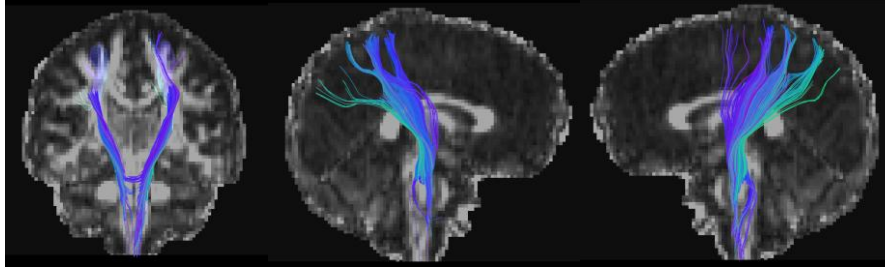


Figure 9. Three views of the corticospinal tract in subject 3. Tracking was carried out on the tensors after free water removal using the 30 direction dataset.

Using the same ROIs we tracked significantly more fibers using the 30 direction dataset, especially in the left CST (tumor side). For this dataset, the left CST contained 573 fibers after free water removal while there were only 540 before (increase of 6%) and the right CST had 387 fibers post treatment versus 381 (increase of 1.5%).

Corpus Callosum

Because of the location of the tumor and surrounding edema, we postulated that the fiber tract that is most affected is the corpus callosum. Since the 30 direction dataset enabled denser tract reconstruction, it was used to reconstruct the fibers of the corpus callosum, nearest to the tumor, pre- and post-free water removal. In the peritumoral region, this fiber bundle comprised 781 fibers post- versus 695 pre-free water removal (an increase of 12%).

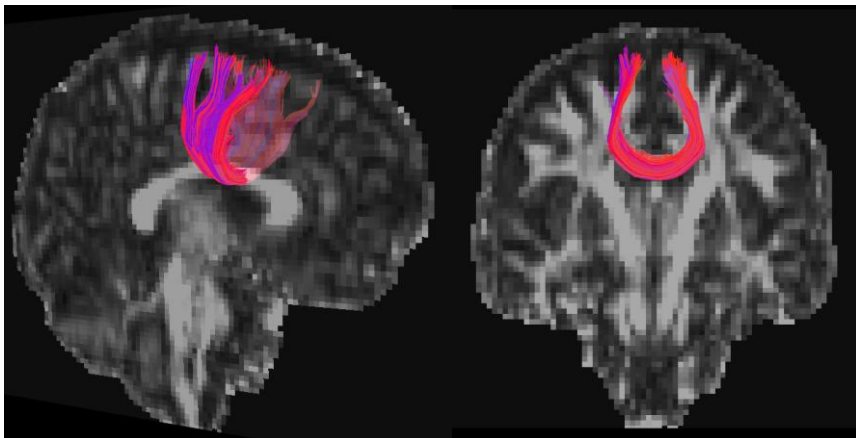


Figure 10. Two views of the corpus callosum in subject 3. Tracking was carried out using the 30 direction dataset and using tensors that were corrected for free water. Only the fiber bundle in proximity to the peritumoral region, and hence most affected by edema, is demonstrated.

4 Discussion

Tractography provides valuable information to a neurosurgeon, especially for intrinsic tumors in or near eloquent cortex and when significant mass effect is present. Fiber tractography not only enables the surgeon to visualize the spatial relationship between a tumor and fiber tract, but it also allows the surgeon to understand tract displacement when significant mass effect is present. Currently, there are numerous tractography techniques that vary based on the diffusion model (tensors or higher order) fitted to the data, as well as the method of propagation, from streamline to probabilistic tractography. More importantly, independent of the diffusion model or selected tractography algorithm, all current fiber tracking methods are affected by the presence of edema and mass effect. Specifically, fractional anisotropy, which is the stopping criteria for all established tracking algorithms, is affected by fluctuations in tissue water content.

The aim of this paper was to create a paradigm that facilitates accurate tracking through edematous brain regions, as opposed to iterating on a published tractography algorithm. The underlying hypothesis for our paradigm is that in regions of edema there is an increase in the extra-cellular water content, but the underlying white matter fiber is still present/intact. If our hypothesis is true, then tractography methods, which account for intra- and inter-cellular water, should be able to reconstruct white matter fiber in edematous brain. To achieve this, we use the simplest form of tractography, namely streamline tractography, and instead focus our efforts on extracting information from the underlying tensor. We perform this by quantifying and extracting the free water content, with the purpose of reconstructing a corrected tensor and thereby improving fiber tracking.

The results presented on the three subjects demonstrate that the removal of free water and the correction of tensors achieved in the process significantly change the results of the fiber tracking algorithm. Evaluation of these tracts is based on a combination of qualitative and quantitative measures, since there is an absence of ground truth. While the corticospinal tract was evaluated in both subjects, the affected peritumoral tracts differed between the subjects. We evaluated the difference between the tracts (pre and post free water removal), quantitatively based on three criteria. First, we evaluated how well the calculated free water map was able to identify edematous brain regions. This evaluation was based on overlap between regions of high free water with the map of edema. Secondly, the dot product of the principal Eigen direction of the tensors before and after free water correction was likewise calculated. Figure 4 and 5 shows the latter evaluation for both the patients. Finally, the difference in FA was likewise calculated for each subject pre- and post- correction, as demonstrated in Figure 3.

The qualitative evaluation of these tracts was based on the anatomical correctness of the reconstructed tract, as determined by the neurosurgeon. In order to make the

comparison unbiased, we used the same ROIs for tracking pre- and post- free water removal. While the tracts could have been pruned with the addition of constraining ROIs, it was felt that this would compromise the comparability of the results after free water correction. It is notable that we were able to use minimal, but anatomically faithful, inclusion ROIs to reconstruct the white matter tract of interest. Furthermore, the results did not produce significant false-positive fibers despite the absence of exclusion ROIs for pruning.

5 Conclusions

As shown in this paper, correction of tensors using free water removal is an important and powerful method when performing white matter tractography in the presence of edema. Using this method, we were able to improve the reconstruction of critical white matter tracts in the vicinity of an intrinsic brain lesion, while minimizing any false-positive fiber bundles. Importantly, in subject two our method enabled us to reconstruct the IFOF, which was not possible using the original, free water uncorrected imaging data. Although significant work remains in improving diffusion acquisition schemes, tensor modeling, and tractography algorithms, the presented results highlight the importance of modeling free water. In turn, this advanced modeling independently enhances tractography results, facilitating the reconstruction of important peritumoral tracts despite the presence of edema. Finally, this augmented tracking paradigm can be easily adapted to currently used clinical tractography techniques, therefore improving the accuracy and reliability of diffusion imaging for pre-operative surgical planning.

Acknowledgments. The authors acknowledge support from the NIH grant NIH-R01 MH092862 and a CBICA grant.

References

1. Pasternak O., Sochen N., Gur Y., Intrator N. and Assaf, Y. "Free water elimination and mapping from diffusion MRI." *Magnetic Resonance in Medicine* 62(3): 717-730 (2009).
2. Tristan-Vega A. and Aja-Fernandez S. "DWI filtering using joint information for DTI and HARDI", *Medical Image Analysis* 14(2): 205-218 (2010)
3. Dyrby T., Lundell H., Liptrot M., Burke W., Ptito M. and Siebner H. "Interpolation of DWI prior to DTI reconstruction and its validation." *Proceedings of ISMRM*, 1917 (2011)
4. Basser P. J., Mattiello J. and Le Bihan D. "MR diffusion tensor spectroscopy and imaging." *Biophysical journal* 66(1): 259-267 (1994).

5. Stejska, E. O. and Tanner J. E. "Spin diffusion measurements: spin echoes in the presence of a time-dependent field gradient." *The journal of chemical physics* 42(1): 288 (1965).
6. Wang R., Benner T., Sorensen A. G. and Wedeen V. J. "Diffusion Toolkit: A Software Package for Diffusion Imaging Data Processing and Tractography" *Proceedings of ISMRM*, 3720 (2007).
7. Castellano A., Bello L., Michelozzi C., Gallucci M., Fava E., Iadanza A, Riva M, Casaceli G and Falini A. " Role of diffusion tensor magnetic resonance tractography in predicting the extent of resection in glioma surgery." *Neuro-oncology* 14(2) 192-202 (2011).
8. Mori S, Crain BJ, Chacko VP, van Zijl PC. "Three-dimensional tracking of axonal projections in the brain by magnetic resonance imaging" *Ann Neurol*. 45(2):265-269 (1999).